



LETTER TO THE EDITOR

Reversible diffuse lung disease after mycophenolate mofetil withdrawal



Mycophenolate mofetil (MMF) is a cell cycle inhibitor widely used in patients with solid organ transplants¹, in the treatment of many autoimmune diseases^{2,3} and, even, in hypersensitivity pneumonitis⁴. Its most frequent side effects are myelosuppression, gastrointestinal disorders and an increased susceptibility to infections, including pneumonia^{3,4}. The development of interstitial lung disease after taking this drug is a rare adverse effect of which only isolated cases have been published^{5–7}. We present a patient with pulmonary toxicity due to MMF.

A 72-year-old woman came to the Emergency Department after seven days of fever, asthenia and dyspnoea. In 2008, she had received a kidney transplant due to chronic renal failure secondary to Polycystic kidney disease and had begun treatment with corticosteroids, sirolimus and MMF (640 mg/12 hours). In 2014, a chest computed tomography (CT) scan revealed an extended micronodular interstitial lung disease that disappeared after withdrawal of sirolimus. It was interpreted as a pulmonary toxicity and was replaced by tacrolimus.

Upon arrival to the Emergency Room she had a fever (37.5 °C) with diminished respiratory sounds and crackles in the middle of the left hemithorax. The patient had never smoked, had no close contact with animals and had not engaged in any potentially harmful professional, recreational or domestic activities. Blood test results showed hemoglobin 11.7 g/dL, leukocytes 5,000/mm³ with lymphopenia (650/mm³; 13%), urea 70 mg/dL, creatinine 1.57 mg/dL and C-reactive protein 1.9 mg/dL. Arterial blood gases evidenced hypoxemia (pO₂ 49.7 mmHg) and chest CT demonstrated multifocal pulmonary lesions with areas of ground-glass and small bilateral pleural effusion of left predominance (Fig. 1A). The cultures in different biological samples (blood, sputum, bronchoalveolar lavage and pleural fluid) for bacteria, tuberculosis, virus (cytomegalovirus, influenza, parainfluenza, herpes, chickenpox, syncytial, HIV, etc.), aspergillus-galactomannan and *pneumocystis jirovecii* were all negatives. Serology against Coxiella, Legionella, Chlamydia, Toxoplasma and Mycoplasma pneumoniae was negative. Macroscopically, bronchofibroscopy was normal.

Bronchoalveolar lavage showed a lymphocyte predominance (50%) with a CD4/CD8 T-lymphocyte ratio of 4.35. There were relevant alterations in the smear findings. The pleural fluid had biochemical exudate characteristics with 100% mononuclear cells and an adenosine deaminase of 14 IU/L. Echocardiography ruled out endocarditis. Neither pulmonary function tests nor any type of lung biopsy were performed due to the patient's clinical situation and the presumably limited collaboration. During the first days of admission, treatment with MMF and tacrolimus were maintained, and different antibiotic cycles were performed (levofloxacin, ceftriaxone, piperacillin/tazobactam, voriconazole, amikacin and linezolid), without improvement. The fact that all cultures were negative and the lack of response obtained led to rejection of the hypothesis of an infectious cause in an immunocompromised patient and to considering the possibility of pulmonary toxicity. Antibiotics and MMF were discontinued and tacrolimus was maintained. Since then, the clinical and radiological improvement was progressive, with resolution of fever, respiratory failure and radiological alterations, including pleural effusion (Fig. 1B). Once clinical improvement was observed, the oral corticosteroid dose of methylprednisolone was increased to 80 mg/day. After nine months of follow-up, the patient is asymptomatic.

MMF is used as a first or second immunosuppressant line in solid organ transplant protocols since it inhibits the purine biosynthesis of T and B lymphocytes through the inosine monophosphate dehydrogenase enzyme, limiting the proliferation of lymphocytes. In this way, there is a reduction in the generation of effector lymphocytes for T cell-mediated immunity and the production of antibodies. Its profile of adverse effects is acceptable. In all cases published to date, the appearance of interstitial lung disease induced by MMF manifested in the short-medium term (maximum 18 months) after the introduction of the drug⁷. However, this is the first case described in which lung disease appears after the use of MMF in the long term (9 years).

The development of interstitial lung disease with MMF is an unusual side effect of immunosuppression. The main difficulty in establishing a link between any immunosuppressive agent and a lung disease is that it is a diagnosis of exclusion. In this case, the temporal relationship, the clinical and CT characteristics of the thorax, the negative cultures and the symptomatic and radiological improvement after the removal of MMF suggest interstitial lung disease induced by MMF, although an atypical infection cannot be

Abbreviations: CT, computed tomography; MMF, mycophenolate mofetil.

<https://doi.org/10.1016/j.pulmoe.2018.10.003>

2531-0437/© 2018 Sociedade Portuguesa de Pneumologia. Published by Elsevier España, S.L.U. This is an open access article under the CC BY-NC-ND license (<http://creativecommons.org/licenses/by-nc-nd/4.0/>).

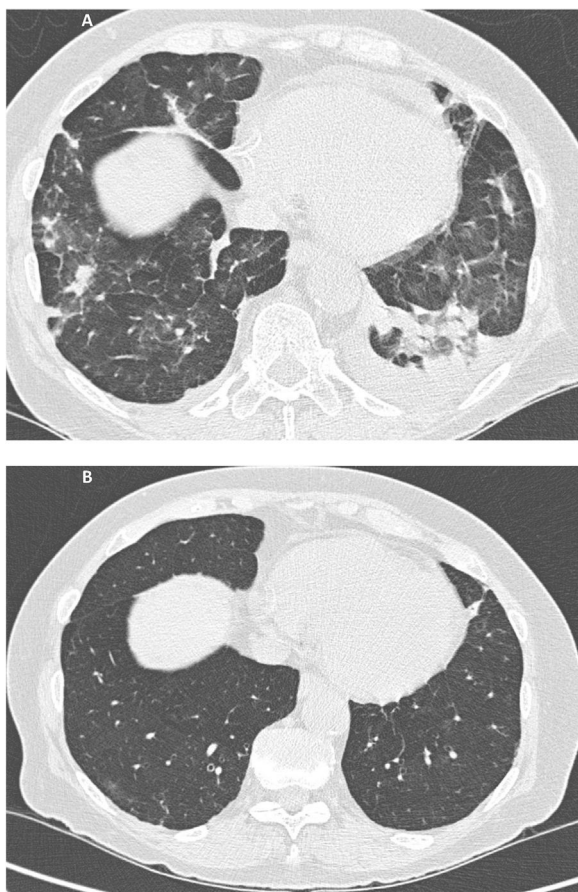


Figure 1 A Multiple small consolidations in both lungs with areas of ground glass opacification and small bilateral pleural effusion of left predominance. Fig. 1B. Complete resolution of the extensive pulmonary disease with consolidative component and ground glass, as well as the small bilateral pleural effusion.

safely excluded. Cryptogenetic organizing pneumonia and pulmonary eosinophilia were ruled out when presenting clinical-radiological improvement with a minimum dose of corticosteroids and eosinophils were not demonstrated in bronchoalveolar lavage, respectively.

In summary, what can be learned from this case is that MMF is a drug that must be taken into account as a potential cause of interstitial lung disease. Although rare, this is a serious adverse effect. Therefore, in the presence of fever, dyspnoea and diffuse pulmonary involvement in chest CT, this possibility should be considered. An empirical test of MMF suspension and observation of symptomatic improvement could be enough to identify the drug as the probable cause of the disease.

References

1. Staatz CE, Tett SE. Pharmacology and toxicology of mycophenolate in organ transplant recipients: an update. *Arch Toxicol.* 2014;88:1351–89.
2. Hahn BH, McMahon MA, Wilkinson A, et al. American college of rheumatology guidelines for screening, treatment and management of lupus nephritis. *Arthritis Care Res.* 2012;64:797–808.
3. Tashkin DP, Roth MD, Clements PJ, Furst DE, Khanna D, Kleeup EC, et al. Mycophenolate mofetil versus oral cyclophosphamide in scleroderma-related interstitial lung disease: Scleroderma Lung Study II (SLS-II), a double-blind, parallel group, randomized controlled trial. *Lancet Respir Med.* 2016;4:708–19.
4. Morriset J, Johansson KA, Vittinghoff E, Aravena C, Elicker BM, Jones KD, et al. Use of Mycophenolate Mofetil or Azathioprine for the Management of Chronic Hypersensitivity Pneumonitis. *Chest.* 2017;151:619–25.
5. Gross DC, Sasaki TM, Buick MK, Light JA. Acute respiratory failure and pulmonary fibrosis secondary to administration of mycophenolate mofetil. *Transplantation.* 1997;64:1607–9.
6. Reynolds BC, Paton JY, Howatson AG, Ramage IJ. Reversible chronic pulmonary fibrosis associated with MMF in a pediatric patient: a case report. *Pediatr Transplant.* 2008;12:228–31.
7. Tull TJ, TomaT, Menagé HP. Reversible interstitial lung disease following treatment of atopic dermatitis with mycophenolate mofetil. *Clin Exp Dermatol.* 2016;41:702–3.

Romina Abelleira

Complejo Hospitalario Universitario De Santiago De Ompostela Neumología Choupana S/N A Coruña/ Galicia 15706 Santiago De Compo Stela Spain