



PULMONOLOGY

www.journalpulmonology.org


REVIEW

Transbronchial lung cryobiopsy for peripheral pulmonary lesions. A narrative review

Y. Tang^{a,b,c,1}, S. Tian^{a,b,1}, H. Chen^{a,1}, X. Li^{a,d,1}, X. Pu^c, X. Zhang^e, Y. Zheng^c, Y. Li^b, H. Huang^a, C. Bai^{a,*}

^a Department of Respiratory and Critical Care Medicine, The First Affiliated Hospital of Naval Medical University, Shanghai, China

^b Department of Respiratory and Critical Care Medicine, No. 906 Hospital of the Chinese People's Liberation Army Joint Logistic Support Force, Ningbo, China

^c Basic Medical School, Guizhou University of Traditional Chinese Medicine, Guiyang, Guizhou, China

^d Department of Respiratory and Critical Care Medicine, General Hospital of Central Theater Command of Chinese People's Liberation Army, Wuhan, China

^e Department of Respiratory and Critical Care Medicine, The First Affiliated Hospital of Guizhou University of Traditional Chinese Medicine, Guiyang, Guizhou, China

Received 7 August 2023; accepted 30 August 2023

Available online xxx

KEYWORDS

Transbronchial lung cryobiopsy;
Peripheral pulmonary lesions;
Diagnosis;
Lung cancer;
Radial endobronchial ultrasound

Abstract An increasing number of peripheral pulmonary lesions (PPLs) requiring tissue verification to establish a definite diagnosis for further individualized management are detected due to the growing adoption of lung cancer screening by chest computed tomography (CT), especially low-dose CT. However, the morphological diagnosis of PPLs remains challenging. Transbronchial lung cryobiopsy (TBLC) that can retrieve larger specimens with more preserved cellular architecture and fewer crush artifacts in comparison with conventional transbronchial forceps biopsy (TBFB), as an emerging technology for diagnosing PPLs, has been demonstrated to have the potential to resolve the clinical dilemma pertaining to currently available sampling devices (e.g., forceps, needle and brush) and become a diagnostic cornerstone for PPLs. Of note, with the introduction of the 1.1 mm cryoprobe that will be more compatible with advanced bronchoscopic navigation techniques, such as radial endobronchial ultrasound (r-EBUS), virtual bronchoscopic navigation (VBN) and electromagnetic navigation bronchoscopy (ENB), the use of TBLC is expected to gain more popularity in the diagnosis of PPLs. While much remains for exploration

Abbreviations: PPLs, peripheral pulmonary lesions; CT, computed tomography; CT-TTNB, CT-guided transthoracic needle biopsy; r-EBUS, radial endobronchial ultrasound; VBN, virtual bronchoscopic navigation; ENB, electromagnetic navigation bronchoscopy; CLE, confocal laser endomicroscopy; OCT, optical coherence tomography; TBFB, transbronchial forceps biopsy; TBLC, transbronchial lung cryobiopsy; ILD, interstitial lung disease; NSCLC, non-small cell lung cancer; EGFR, epidermal growth factor receptor; TBNA, transbronchial needle aspiration; ROSE, rapid on-site evaluation; GS, guide sheath; GGO, ground-glass opacity; ETT, endotracheal tube; ICI, immune checkpoint inhibitor; PD-L1, programmed death ligand 1. LCOs, lung cancer organoids.

* Corresponding author at: Department of Respiratory and Critical Care Medicine, The First Affiliated Hospital of Naval Medical University, Shanghai 200433, China.

E-mail address: Chongbai@smmu.edu.cn (C. Bai).

¹ These authors contributed equally to this work.

<https://doi.org/10.1016/j.pulmoe.2023.08.010>

2531-0437/© 2023 Sociedade Portuguesa de Pneumologia. Published by Elsevier España, S.L.U. This is an open access article under the CC BY-NC-ND license (<http://creativecommons.org/licenses/by-nc-nd/4.0/>).

Please cite this article in press as: Y. Tang, S. Tian, H. Chen et al., Transbronchial lung cryobiopsy for peripheral pulmonary lesions. A narrative review, Pulmonology (2023), <https://doi.org/10.1016/j.pulmoe.2023.08.010>

using the TBLC technique for diagnosing PPLs, it can be envisaged that the emergence of additional studies with larger data accrual will hopefully add to the body of evidence in this field.

© 2023 Sociedade Portuguesa de Pneumologia. Published by Elsevier España, S.L.U. This is an open access article under the CC BY-NC-ND license (<http://creativecommons.org/licenses/by-nc-nd/4.0/>).

Introduction

In recent years, there have been an increasing number of patients with peripheral pulmonary lesions (PPLs) that are being detected as a result of the growing adoption of chest computed tomography (CT) scans performed for lung cancer screening.^{1,2} Obtaining tissue from PPLs to establish an accurate diagnosis for both prognostic and therapeutic implications remains difficult to achieve. Whilst CT-guided transthoracic needle biopsy (CT-TTNB) previously served as the treatment of choice for identifying PPLs, with a superior diagnostic yield,³ there has been concern regarding a considerable complication rate (pneumothorax and pulmonary haemorrhage),⁴ which has limited further application of this technique. By comparison, minimally invasive bronchoscopic modalities, such as thin/ultrathin bronchoscopes, radial endobronchial ultrasound (r-EBUS), virtual bronchoscopic navigation (VBN), electromagnetic navigation bronchoscopy (ENB), cone beam CT, confocal laser endomicroscopy (CLE) and optical coherence tomography (OCT), have opened up a new way to diagnose PPLs and are emerging as safer alternatives to CT-TTNB.⁵⁻¹⁰ However, a suboptimal diagnostic yield for lesion sampling compared with CT-TTNB remains a significant limitation.¹¹ One of the reasons for the insufficient diagnostic outcomes of such technologies is the use of sampling instruments.¹² Specimens from PPLs obtained by transbronchial forceps biopsy (TBFB) are generally small and sometimes crushed, which may prevent a successful diagnosis and result in molecular testing failure.¹³

Transbronchial lung cryobiopsy (TBLC) that can yield larger tissue samples with better cellular architecture preservation and fewer crush artifacts via a tangential/lateral biopsy, as a novel tool for sampling PPLs, is frequently described for the evaluation of interstitial lung disease (ILD).^{14,15} In addition, placing an endobronchial blocker as the occlusion balloon at the start of the procedure, and the use of r-EBUS with a role of searching for blood vessels at the biopsy site and avoiding them during TBLC, may improve the safety of this technique in the diagnosis of PPLs.¹⁶ Given the potential benefits of TBLC, there is an increased focus on the use of TBLC for sampling PPLs, especially over the last 2 years. From studies to date, as promising as TBLC may be, this technique for diagnosing PPLs has not been standardized. We here present a comprehensive overview on the basis of the current literature and focus on the diagnostic yield, safety profile and the quantity and quality of specimens of TBLC in the setting of PPLs.

Methods

A comprehensive and systematical online literature search via PubMed, Web of Science, and EMBASE was performed to

identify relevant articles from the date of inception to June 2023, using the following search terms: “cryobiopsy”, “lung”, “peripheral”, and “diagnosis”. We also searched specifically for “transbronchial lung cryobiopsy” and “peripheral pulmonary lesions”. Furthermore, we performed an extensive manual screening of reference lists of the selected articles to capture further papers of interest. The aforementioned procedure was conducted repeatedly until all relevant articles were retrieved. Written informed consent was obtained from the patient with the provision of images.

Technical outline

Transbronchial lung cryobiopsy (TBLC) requires a cryoprobe that is an insulated catheter inserted through the working channel of a flexible bronchoscope and can extend to the lung periphery through the bronchoscope. The distal metal tip of the cryoprobe cools to a temperature of -79°C (using carbon dioxide) or -89°C (using nitrous oxide) within seconds, which is mediated by the Joule-Thomson effect where the cryoprobe uses compressed gas that is decompressed within its metallic tip, and thereby causing the cooling.^{17,18} As a consequence, TBLC allows for a 360-degree biopsy, enabling the bronchoscopist to obtain larger tissue specimens with a minimized crush artifact, thereby allowing pathologists to easily identify the immunohistochemical and molecular characteristics of PPLs, which are common in non-small cell lung cancer (NSCLC).^{19,20}

Fig. 1 illustrates the details of r-EBUS guided TBLC. Prior to the procedure, a solitary pulmonary nodule with a positive CT bronchus sign in the left lower lobe was determined on the CT scan. Following moderate-to-deep conscious sedation with intravenous midazolam and fentanyl, a 20-MHz r-EBUS probe with an external diameter of 1.4 mm (UM-S20-17S; Olympus, Tokyo, Japan) was extended into the lung periphery through the working channel of the bronchoscope. r-EBUS imaging showing a concentric lesion (i.e., the r-EBUS probe was within and completely surrounded by the lesion) with no significant surrounding vessels. An endobronchial blocker was then placed at the target segmental bronchi. Subsequently, cryobiopsy was performed (ERBE Cryoprobe 1.9 mm diameter, Medizintechnik, Tuebingen, Germany) with the foot pedal switch of Cryostation being activated for 5 s. The cryoprobe was quickly retracted en bloc together with the flexible bronchoscope from the patient. Upon removal of the cryoprobe, the pre-placed endobronchial blocker was inflated with air immediately in order to control bleeding after procedure. All biopsy specimens were fixed in formalin and sent to the pathology lab immediately for further analysis. Immunohistochemical and molecular analysis revealed lung adenocarcinoma with sensitizing epidermal growth factor receptor (EGFR) mutation.

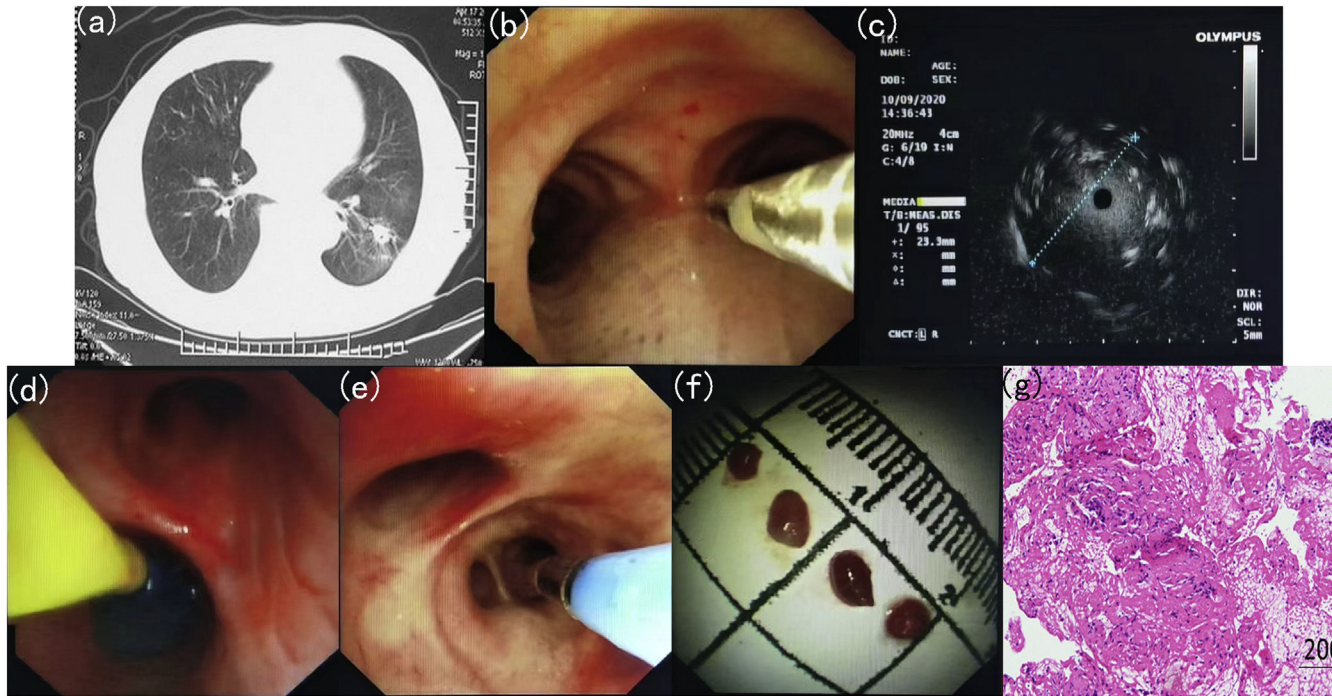


Fig. 1 Details of transbronchial lung cryobiopsy (TBLC) guided by radial endobronchial ultrasound (r-EBUS). (a) Computed tomography (CT) scan of the chest showing a solitary pulmonary nodule located in the left lower lobe; (b) The placement of the r-EBUS probe into the target bronchus; (c) r-EBUS imaging showing a concentric lesion with no significant surrounding vessels; (d) An endobronchial blocker is placed in the proximal lobar bronchus from the lesion and is inflated after procedure; (e) The placement of the cryo-probe into the target bronchus; (f) Bioptic specimens with sizing scale collected through TBLC; (g) Immunohistochemical analysis revealing lung adenocarcinoma.

Diagnostic yield

Where all the previous studies of TBLC are almost confined to ILD,^{21,22} Schuhmann et al.¹⁷ evaluated for the first time the use of TBLC in patients with PPLs in 2014. In the randomized trial, a total of 31 patients whose lesions could be detected by r-EBUS were randomly assigned to each group; 16 patients undergoing TBLC and 15 patients undergoing TBFB were analyzed. The diagnostic yields were 74.2% and 61.3% for TBLC and TBFB, respectively. Although the statistical difference in yield between both groups was not significant ($P=0.42$), the increasing trend seemed attractive. Since then, a growing body of studies have highlighted the role of TBLC for the diagnosis of PPLs. Tanaka et al.²³ performed a prospective study involving 50 cases to investigate the utilization of TBLC for PPLs, using a new 1.7-mm cryoprobe. Diagnostic yield was reported at 94%, it was notable, however, that there was no statistically significant difference between the 1.1 mm and 1.9 mm cryoprobes used in ILD regarding diagnostic yield, according to recent report from Ravaglia et al.²⁴ Several studies have compared TBLC to TBFB in the diagnosis of PPLs during the same procedure.²⁵⁻⁴⁰

A prospective control study whereby patients underwent both TBLC and TBFB revealed diagnostic rates of 75.00% and 64.52%, respectively; when taking only the first sample into account, the diagnostic yield of TBLC (64.29%) was higher than that of TBFB (35.48%).²⁵ Similarly, Torky and colleagues demonstrated diagnostic accuracies of TBLC and TBFB were 76.7% and 69.8%, respectively; when both were combined the yield increased further to 86.7%.²⁶ To date, the largest series which consisted of 2,724 cases with a propensity score analysis indicated that the diagnostic yield was significantly higher in the TBLC group than in the TBFB group (89.2% vs. 77.6%, $P < 0.001$).²⁷ Moreover, TBLC has been shown to improve diagnostic yield of PPLs when used in addition to other conventional devices, including TBFB, transbronchial needle aspiration (TBNA) and transbronchial brushing.^{28,41} Worth noting was that for PPLs less than 2 cm in diameter, TBLC presented an additional benefit with a relatively high diagnostic yield ranging from 69.0% to 76.5%.^{29,42,43} A prospective study of 32 patients compared the influence of TBLC and TBFB on the diagnosis of PPLs smaller than 20 mm. The diagnostic yield of TBLC was 69% vs. 38% with TBFB ($P = 0.044$),⁴² which could be reported in larger series of 152 PPLs patients.²⁹ Also of note is that for eccentrically and adjacently oriented lesions with a suboptimal diagnostic yield for TBFB due to inadequate depth of the forceps biopsy, a number of studies have demonstrated encouraging diagnostic yield with a range of 74.0% to 84.3%, which significantly improves compared to TBFB.^{29-32,41,44}

Rapid on-site evaluation (ROSE) with the aid of conventional microscopy and higher harmonic generation microscopy allowing rapid stain and real-time assessment for direct slides,^{45,46} because of its high specificity (90.0%) and positive predictive value (93.8%), was considered to be a potential tool in deciding whether TBLC could be finished in a case series of 63 patients with PPLs.⁴⁷ A meta-analysis by Sryma and colleagues from 9 studies that included 300 patients between 2014 and 2020 compared TBLC to TBFB when combined with r-EBUS for the diagnosis of PPLs.¹¹ TBLC resulted in a higher diagnostic yield than TBFB (77% vs 72%, respectively); however, the statistical difference

observed was not significant. This may be attributed to 1.9 mm cryoprobe used in all studies of this meta-analysis. It was reported that the addition of a guide sheath (GS) allowing for cryobiopsy at the same location provided an additional diagnostic gain to TBLC³³; its use was, nevertheless, not routinely possible in most cases with a non-ultrathin cryoprobe, as it could hamper this procedure. Another limitation is that the non-ultrathin cryoprobe restricted by the thickness and stiffness of their tip made it difficult to approach some locations such as the subpleural areas and the apical segment of the upper lobe.⁴⁰ Although special techniques including the crawling up and cryoprobe bending method have been created and demonstrated to be useful for pushing the cryoprobe into the upper field of the lung,^{41,48} they mostly depended on the bronchoscopists' individual experience. Also, it is necessary to remove the tissue sample, bronchoscope en bloc, and non-ultrathin cryoprobe from the patient when specimen is adhered to it, which is adverse to repeat biopsy.¹¹

Hopefully, a novel commercially available 1.1 mm ultrathin cryoprobe with increased flexibility that can be used with a 1.95 mm GS in a 2.0 mm working channel has been developed to address the diagnostic dilemma of the non-ultrathin cryoprobe for PPLs. A landmark study was done by Yarmus et al.⁴⁹ in 2016, who first reported the use of 1.1 mm ultrathin cryoprobe through the GS and leaving the GS in situ, with the bronchoscope remaining inside the airway. They demonstrated that this technique was feasible without a significant bleeding risk, however, the pilot study only focused on a porcine model. Subsequently, the feasibility of the ultrathin cryoprobe in the clinical setting was first described by Kho and colleagues in 2020, and they demonstrated that the ultrathin cryoprobe had a dramatic improvement over the non-ultrathin cryoprobe when diagnosing PPLs located in the apical segment of upper lobes.⁵⁰ Jiang et al.⁵¹ retrospectively evaluated 20 PPLs patients with 23 ground-glass opacity lesions (GGOs) (12 pure GGOs, 11 mixed GGOs) who underwent TBLC using a new 1.1-mm diameter cryoprobe, and eventually diagnosis was established in 82.6% of GGOs. The considerable diagnostic yield of the ultrathin cryoprobe for PPLs with GGOs that are relatively difficult to diagnose by TBFB, may be attributed to the fact that detailed information related to alveolar structures can be provided by TBLC. In addition to lesions located in the upper lobe and GGOs, the superiority of 1.1 mm ultrathin cryoprobe in diagnosing lesions near the pleura could be also observed when compared with 1.9 mm conventional cryoprobe.^{23,52} In order to evaluate the clinical outcomes of TBLC using the ultrathin cryoprobe for the diagnosis of PPLs, Kim et al.⁵³ performed the prospective observational pilot study in which they sampled 50 PPLs and were able to achieve 45 positive samples with a yield of 90%. Furthermore, a comparative study conducted by Chung and colleagues retrospectively examined a consecutive series of 229 patients who underwent TBLC with an ultrathin cryoprobe and TBFB; results indicated that the diagnostic yields of TBLC and TBFB were 84.4% and 65.3%, respectively; when both were combined the overall diagnostic yield increased further to 91.5%.³¹ It is well established that despite good accessibility to the targeted PPLs, especially combined with advanced bronchoscopic navigation technologies, ultrathin bronchoscopy fails to obtain the large size of biopsy

specimens owing to the restricted size of the biopsy instrument.⁵⁴ Fortunately, the ultrathin cryoprobe inserted through the working channel of the ultrathin bronchoscopy makes up the deficiency. The use of the ultrathin cryoprobe in combination with ultrathin bronchoscopy was first reported by Oki and colleagues in 2022. They demonstrated that TBLC, TBFB and the combination of these two methods provided a definitive diagnosis in 62%, 54%, and 74% of patients with PPLs, respectively.³⁵

Radial endobronchial ultrasound (r-EBUS) confirming the location of the target PPLs is always used when performing TBLC. One major limitation regarding r-EBUS is the absence of real-time guidance during TBLC, a certain amount of tissue samples remain nondiagnostic, which can be overcome by the combination with advanced bronchoscopic navigation techniques.¹⁷ The unique characteristics of the 1.1 mm cryoprobe enable TBLC under guidance techniques, such as VBN, ENB and robotic-assisted bronchoscopy platforms.⁴⁹ The first study performed TBLC, TBFB and TBNA using the Ion™ Endoluminal System in 112 patients with 120 PPLs. The overall diagnostic yield of 90% was reported, and nearly 18% of diagnoses were made exclusively from TBLC.³⁶ A subsequent study evaluated the Monarch™ platform in 58 PPLs patients with a median lesion size of 15mm. 94.8% of the PPLs was successfully localized using r-EBUS, however a diagnostic yield of 74% was reported.⁴⁴ As encouraging as the results of both studies may be, the use of guidance techniques, especially robotic-assisted bronchoscopy is associated with high economic costs; therefore, evaluation of cost-effectiveness is essential.⁵⁵ Additionally, the combination of transthoracic ultrasound and flexible cryoprobe has been reported to be a simple, feasible and reproducible modality with low cost and bedside availability for the diagnosis of PPLs, making it a potential surrogate for hospitals with cost-benefit consideration.⁵⁶ To better confirm these findings, further prospective studies in a larger patient cohort are required.

It should be emphasized that the disposable design of the 1.1 mm ultrathin cryoprobe may be cost-prohibitive. Plus, some studies showed that the 1.1 mm and 1.9 mm cryoprobes have similar diagnostic performance for PPLs.^{37,49} Hence, their use in the clinical field should be based on various factors, such as lesion characteristics and cost-effectiveness. The main characteristics of the prospective trials that describe the utility of TBLC for the diagnosis of PPLs are summarized in Table 1.

Safety profile

In view of the safety profile of TBLC in the evaluation of ILD, concerns associated with bleeding and pneumothorax have been raised when using TBLC for patients with PPLs.¹⁴ Indeed, a meta-analysis involving 9 articles on the application of TBLC in PPLs demonstrated that TBLC-related complications reported were mainly mild to moderate bleeding that settled with the negative pressure suction, local adrenaline instillation or ice adrenaline dilution, and severe bleeding and pneumothorax were only observed after procedure in 1 (0.5%) and 3 (1.4%) of 222 patients, respectively.¹¹ Another meta-analysis of 39 studies conducted by Giri and colleagues compared TBLC and TBFB for the diagnosis of

PPLs with respect to utility and safety, showing that TBLC was associated with a significant increase in the incidence of moderate to severe bleeding (OR, 2.17; 95% CI, 1.48–3.19; $P < 0.01$) based on the unified bleeding grade,⁶¹ however, no significant difference was observed in the incidence of pneumothorax between the TBLC and TBFB groups (OR, 0.90; 95% CI, 0.44–1.85; $P = 0.78$).⁶² Consequently, bleeding has been of particular concern. In recent years, there has been increased interest in the use of precautionary interventions to control bleeding caused by TBLC.⁶³

As the commonest type of technique used in the guidance of a bronchoscope to PPLs,⁶⁴ r-EBUS can also identify vascular areas that are hyperechoic, thereby mitigating the risk of bleeding during TBLC in patients with PPLs by manoeuvring the probe to the least vascular area.⁶⁵ A prospective randomized double-blind pilot trial by Pannu and colleagues assessing the utility of r-EBUS in minimizing bleeding from TBLC showed trends of less severe grade of bleeding towards the decreased grade of bleeding, less time spent to control bleeding and less need for additional interventions were observed under r-EBUS guidance.⁵⁹ Due to the anticipated higher bleeding risk based on the TBLC data in ILD,⁶⁶ rigid bronchoscope, endotracheal tube (ETT) and an endobronchial blocker have generally been used to provide airway protection in case of unpredictable bleeding for TBLC of PPLs.⁶⁷⁻⁷⁰ Nevertheless, the use of rigid bronchoscope or ETT is time-consuming and resource intensive, which could be a hindrance for the widespread adoption of this diagnostic modality at majority of centers with a lack of rigid bronchoscopy expertise and intubation skills.^{71,72} Plus, the presence of an endobronchial blocker during TBLC may be detrimental for the diagnosis of PPLs because it interferes with bronchoscope manipulation and prevents the devices such as r-EBUS, GS, and the cryoprobe guiding into the correct bronchus route toward the targeted PPLs. Recently, the two-scope technique, as a novel alternative method of hemostasis for TBLC of PPLs, have been described to allow the prompt control of bleeding and flexible manipulation of devices during the procedure instead of using an endobronchial blocker; but to date, a direct comparison between the two-scope method and the prophylactic balloon occlusion technique for TBLC is still absent.³⁸ Surprisingly, all aforementioned measures being implemented to control and prevent bleeding are expected to be revolutionized by the introduction of the new 1.1 mm cryoprobe. It is well recognized that the previously used 1.9 mm cryoprobe needs to be removed from the patient with the specimen, GS, and bronchoscope en bloc, on account of the larger size of the tissue sample. As such, the blind period between extracting the cryobiopsy and bronchoscope reinsertion during TBLC, where bleeding may be occurring but unattended, is unbeneficial to early monitoring of bleeding.⁷³ The 1.1 mm cryoprobe could be removed through the GS whilst keeping the bronchoscope and GS in situ, similar to conventional r-EBUS guided TBFB, where the GS provides some measure of mechanical tamponade, and simultaneously the bronchoscope is consistently in the airway to deal with any bleeding, effectively reducing the risk of bleeding.^{49,74} To confirm the safety of the 1.1 mm cryobiopsy use through the r-EBUS GS, without rigid bronchoscopy, ETT and an endobronchial blocker, additional studies are obviously required.

Table 1 Procedural characteristics of prospective trials of TBLC for PPLs.

Author (year)	Cryoprobe size (mm)	Freezing time (s)	Anaesthesia	Artificial airway	Endobronchial blocker	Navigation modalities	Comparison ^a
Schuhmann et al. (2014) ¹⁷	1.9	4	GA	Yes, rigid bronchoscopy	No	r-EBUS	Yes
Taton et al. (2018) ⁴²	1.9	7-8	GA	Yes, rigid bronchoscopy	Yes	r-EBUS + ENB	Yes
Arimura et al. (2019) ⁵⁷	1.9	3-5	Deep sedation	No	Yes	r-EBUS	Yes
Udagawa et al. (2020) ⁵⁸	1.9	3-5	Moderate/deep sedation	ETT if necessary	No	r-EBUS	Yes
Pannu et al. (2021) ⁵⁹	1.9	4-5	Deep sedation	Yes, ETT	Yes if necessary	r-EBUS	No
Pertzov et al. (2021) ⁴³	2.4	3	Moderate sedation	NA	NA	r-EBUS + ENB	No
Jiang et al. (2021) ²⁵	1.9	4-6	Deep sedation	Yes, LMA	Yes if necessary	r-EBUS	Yes
Ankudavicius et al. (2022) ⁴⁰	1.1, 1.7 and 1.9	4-11	GA	Yes, rigid bronchoscopy	Yes	r-EBUS	Yes
Benn et al. (2022) ⁶⁰	1.1	4	GA	Yes, ETT	No	r-EBUS + ENB	No
Tanaka et al. (2022) ²³	1.7	3	Moderate/deep sedation	Yes, ETT	No	r-EBUS + VBN	No
Kim et al. (2023) ⁵³	1.1	6-8	Moderate/deep sedation	Yes, ETT	No	r-EBUS + VBN	No
Kinoshita et al. (2023) ²⁸	1.9	3-7	Moderate/deep sedation	Yes, ETT	Yes	r-EBUS	Yes
Oki et al. (2023) ³⁵	1.1	4-13	Moderate/deep sedation	Yes, ETT	Yes	r-EBUS + VBN	Yes

TBLC: peripheral pulmonary lesions. TBLC: transbronchial lung cryobiopsy. GA: general anaesthesia. r-EBUS: radial endobronchial ultrasound. ENB: electromagnetic navigation bronchoscopy. ETT: endotracheal tube. NA: not applicable. LMA: laryngeal mask airway. VBN: virtual bronchoscopic navigation.

^a Comparison between TBLC and transbronchial forceps biopsy in same patients.

Immunohistochemical and molecular testing

With the emergence of precision medicine for lung cancer, target therapy and immunotherapy improving the prognosis of NSCLC have revolutionized the management of these patients; however, this has led to more urgent requirement for adequate quantity and quality of specimens.^{75–77} Apart from helping to provide consistent personalised management for patients with lymphoproliferative disorders,⁷⁸ mediastinal lymph nodal involvement for oncologic reasons^{79,80}, and Covid-19 via complete immunohistochemical and molecular analysis,^{81–83} TBLC retrieving the larger size of the tissue samples with more preserved cellular architecture and less biopsy artefacts has opened possibilities for increasing personalization of antineoplastic treatments. Several studies have reported that TBLC yielded significantly larger specimens than TBLB in the diagnosis of PPLs.^{11,17,28,29,35,39,40,42,57,58,62} As for different sizes of cryoprobes, it has been reported that the sample size obtained by 1.1 mm cryoprobe was comparable to that with 1.9 mm cryoprobe.⁵² Haentschel et al.⁸⁴ evaluated the detection rate of EGFR mutations in TBLC specimens in comparison to specimens obtained by non-TBLC techniques (TBFB, TBNA and CT-TTNB) in NSCLC patients. Their retrospective analysis showed that cryobiopsy might be able to substantially increase the number of NSCLC patients that could receive targeted therapy, by increasing the detection rate of molecular genetic alterations (TBLC, 21.6% vs. non-TBLC, 13.8%, respectively). Remarkably, an exploratory randomized study performed by Herath and colleagues suggested that all positive TBLC specimens for malignancy were capable of EGFR mutation analysis.⁷² Furthermore, freezing and thawing during TBLC had virtually no effect on the immunohistochemical results of the expression of HER2 and HER3, according to the study by Nishimatsu et al.⁸⁵ Importantly, prospective data from Udagawa and colleagues revealed the significantly higher success rates for whole-exome sequencing (TBLC, 90% vs TBFB, 15%, respectively) and RNA sequencing (75% vs 10%, respectively).⁵⁸ In other studies, that the success rate of NGS for TBLC specimens was 100% has also been reported.^{28,57} The aforementioned results could be explained by the fact that larger amounts of DNA and RNA could be extracted from TBLC specimens compared to TBFB specimens.^{57,68,86–87} Moreover, tumor cell necrosis that is not always a disadvantage when using immunohistochemical techniques may serve as a factor for failed NGS results, but r-EBUS avoiding TBLC in areas with necrotic lesions plays a role in increasing the NGS success rate, which could not be ignored.^{28,88,89}

For NSCLC patients with the absence of targeted molecular alterations, immune checkpoint inhibitor (ICI) could be essential for a better survival rate.⁹⁰ The expression of programmed death ligand 1 (PD-L1) serves as an important predictor for the effect of ICIs.⁹¹ Arimura et al.⁸⁶ attempted to evaluate the tumor cell count in specimens collected by TBLC and TBFB, in 16 patients with PPLs. The total and average numbers of tumor cells obtained by TBLC were significantly larger than those obtained by TBFB. TBLC also had the tendency to yield greater rates of both PD-L1 expression >1% (TBLC, 18.8% vs TBFB, 12.5%, respectively) and >50% (56.3% vs 37.5%, respectively), in line with another prospective study,⁵⁸ as well as the latest data from one participating institution.⁸⁵ It was noted that despite being cut in half one of the tissue samples obtained by TBLC contained sufficient

DNA and RNA to successfully perform molecular analysis, even the other tissue sample was sufficient for the evaluation of PD-L1 expression.^{57,86}

A research group from the German Centre for Lung Research reported the 5-year experience of prospective biomaterial acquisition in advanced NSCLC. They demonstrated that obtaining the cryoconserved biopsies was feasible in 89% of the treatment-naïve NSCLC patients and in particular, the highest tissue amounts received were through cryobiopsies compared to core- and forceps biopsies. In the future, routine collection of cryopreserved tissue specimens may play a promising role in significantly extending the possibilities of optimized molecular workup of NSCLC and maximizing the benefit of targeted therapy and immunotherapy, thereby improving the quality of life and prognosis of the patient.⁹² Also, lung cancer organoids (LCOs) mimicking the tumor microenvironment have the potential to predict the response to targeted and immunology therapies, and there are still many challenges, such as a low success rate for culturing LCOs due to small amounts of tissue specimens obtained by conventional lung biopsy techniques and few cancer cells in later passages of LCO culture owing to the overgrowth of normal lung cells.⁹³ Hopefully, LCOs derived from TBLC with the ability of providing enough specimens with high purity of cancer cells have been proven to be a breakthrough method for offering a promising solution to the critical limitations associated with conventional LCOs in the routine clinical practice,⁸⁷ which seems attractive and was worth all the effort.

Conclusions

Transbronchial lung cryobiopsy (TBLC) contributing not only to the increased success rate in reaching a conclusive diagnosis without affecting safety but also to improved biopsy quality for potential molecular-based selection of personalized therapeutic strategy, has been an important supplement to the armamentarium of interventional pulmonology and a promising first-line tool for the diagnosis of patients with PPLs. For a benign diagnosis in particular, the pathologist can obtain additional confidence in establishing a definite benign diagnosis due to the ample TBLC samples. Additionally, with the introduction of the 1.1 mm cryoprobe that will be more compatible with advanced bronchoscopic navigation techniques, the use of TBLC is expected to gain more popularity in the diagnosis of PPLs.

However, several technical issues related to TBLC remain to be addressed. First, the use of an endobronchial blocker, anesthesia and artificial airway varied across studies. Standardizing the procedural technique is, therefore, necessary for promoting widespread utilization of this procedure. Second, there is a learning curve for sampling PPLs using TBLC that improves with case experience. A structured education has been recommended for improving the operator's technical expertise.^{94–96} Udagawa et al.⁵⁸ suggested that approximately 20 procedures might be required for a pulmonologist to acquire the desired level of expertise in this technique, but 30 procedures were recommended in another study.⁴⁰ Accordingly, the learning curve of the procedure is still in need to be

clarified. Third, although TBLC has been demonstrated to increase diagnostic yield of PPLs in combination with other conventional biopsy methods, such as TBFB and TBNA,^{26,28,31,35,41} the optimal sequence of biopsy methods has not been established. Finally, for the optimum freezing times and number of TBLC performed to make a balance between larger specimen and fewer complications, various authors described different modalities. According to the clinical evidence of the published studies, the following recommendations can be made: the freezing time should be set at 2–5s for each biopsy and 2–4 biopsies should be performed in each procedure.^{23,25,40,43,44,48,60,86} In large-scale clinical practice, however, the optimum freezing times and number of TBLC for PPLs remain to be defined.

While much remains to be explored using the TBLC technique for diagnosing PPLs, hopefully the emergence of additional studies with larger data accrual will add to the body of evidence in this field. Furthermore, we have to emphasize that TBLC is solely a component of an integrated management for patients with PPLs; with the idea of incorporating the advantages and minimizing the disadvantages of every single technique, a multimodal approach for PPLs in which TBLC can be combined with other conventional devices and advanced bronchoscopy navigation techniques should be the preferred strategy.

Contributors

Y.T. contributed to conceptualization, data curation, and manuscript drafting. S.T. contributed to conceptualization, figure realization, manuscript drafting. H.C. contributed to literature search, data curation, and manuscript revision. X. L. contributed to conceptualization and table realization. X. P., X.Z., Y.Z. and Y.L. offered critical suggestions to this article. H.H. and C.B. contributed to supervision of this manuscript and reviewed the manuscript. All authors read and approved the final version of the manuscript.

Conflicts of interest

The authors declare no competing interest.

Consent to participate

Written informed consent was obtained from the patient with the provision of images.

Acknowledgements

This work was supported by the Collaborative Innovation Cluster Project of Shanghai Municipal Health Commission (no. 2020CXJQ03), 234 Climbing the Discipline Program of first affiliated hospital of Naval Medical University (no. 2020YXK026), the Clinical Research Plan of SHDC (no. SHDC2020CR1021B-005), and National Natural Science Foundation of China (no. 82270112).

References

1. Lu de Koning HJ, van der Aalst CM, de Jong PA, et al. Reduced lung-cancer mortality with volume CT screening in a randomized trial. *N Engl J Med*. 2020;382(6):503–13.
2. Lam S, Tammemagi M. Contemporary issues in the implementation of lung cancer screening. *Eur Respir Rev*. 2021;30(161):200288.
3. Lu CH, Hsiao CH, Chang YC, et al. Percutaneous computed tomography-guided coaxial core biopsy for small pulmonary lesions with ground-glass attenuation. *J Thorac Oncol*. 2012;7(1):143–50.
4. Heerink WJ, de Bock GH, de Jonge GJ, et al. Complication rates of CT-guided transthoracic lung biopsy: meta-analysis. *Eur Radiol*. 2017;27(1):138–48.
5. Wijmans L, Bonta PI, Rocha-Pinto R, et al. Confocal laser endomicroscopy as a guidance tool for transbronchial lung cryobiopsies in interstitial lung disorder. *Respiration*. 2019;97(3):259–63.
6. Kramer T, Annema JT. Advanced bronchoscopic techniques for the diagnosis and treatment of peripheral lung cancer. *Lung Cancer*. 2021;161:152–62.
7. Benn BS, Romero AO, Bawaadam H, et al. Cone beam CT guidance improves transbronchial lung cryobiopsy safety. *Lung*. 2021;199(5):485–92.
8. Zhu Q, Yu H, Liang Z, et al. Novel image features of optical coherence tomography for pathological classification of lung cancer: Results from a prospective clinical trial. *Front Oncol*. 2022;12:870556.
9. Hu Z, Tian S, Wang X, et al. Predictive value of the resistance of the probe to pass through the lesion in the diagnosis of peripheral pulmonary lesions using radial probe endobronchial ultrasound with a guide sheath. *Front Oncol*. 2023;13:1168870.
10. Tian S, Huang H, Zhang Y, et al. The role of confocal laser endomicroscopy in pulmonary medicine. *Eur Respir Rev*. 2023;32(167):220185.
11. Sryma PB, Mittal S, Madan NK, et al. Efficacy of Radial Endobronchial Ultrasound (R-EBUS) guided transbronchial cryobiopsy for peripheral pulmonary lesions (PPL...s): a systematic review and meta-analysis. *Pulmonology*. 2023;29(1):50–64.
12. Mondoni M, Rinaldo RF, Carlucci P, et al. Bronchoscopic sampling techniques in the era of technological bronchoscopy. *Pulmonology*. 2022;28(6):461–71.
13. Smeltzer MP, Wynes MW, Lantuejoul S, et al. The International Association for the Study of Lung Cancer Global Survey on molecular testing in lung cancer. *J Thorac Oncol*. 2020;15(9):1434–48.
14. Rodrigues I, Estêvão Gomes R, Coutinho LM, et al. Diagnostic yield and safety of transbronchial lung cryobiopsy and surgical lung biopsy in interstitial lung diseases: a systematic review and meta-analysis. *Eur Respir Rev*. 2022;31(166):210280.
15. Kronborg-White S, Bendstrup E, Gori L, et al. A pilot study on the use of the super dimension navigation system for optimal cryobiopsy location in interstitial lung disease diagnostics. *Pulmonology*. 2023;29(2):119–23.
16. Casoni GL, Gurioli C, Chhajed PN, et al. The value of transbronchial lung biopsy using jumbo forceps via rigid bronchoscope in diffuse lung disease. *Monaldi Arch Chest Dis*. 2008;69(2):59–64.
17. Schuhmann M, Bostanci K, Bugalho A, et al. Endobronchial ultrasound-guided cryobiopsies in peripheral pulmonary lesions: a feasibility study. *Eur Respir J*. 2014;43(1):233–9.
18. Goel MK, Kumar A, Maitra G, et al. Radial EBUS-guided cryobiopsy of peripheral lung lesions with flexible bronchoscopy without using guide-sheath. *J Bronchology Interv Pulmonol*. 2021;28(3):184–91.
19. Hetzel J, Hetzel M, Hasel C, et al. Old meets modern: the use of traditional cryoprobes in the age of molecular biology. *Respiration*. 2008;76(2):193–7.
20. Ravaglia C, Poletti V. Transbronchial lung cryobiopsy for the diagnosis of interstitial lung diseases. *Curr Opin Pulm Med*. 2022;28(1):9–16.

21. Ravaglia C, Wells AU, Tomassetti S, et al. Diagnostic yield and risk/benefit analysis of trans-bronchial lung cryobiopsy in diffuse parenchymal lung diseases: a large cohort of 699 patients. *BMC Pulm Med.* 2019;19(1):16.
22. Kheir F, Uribe Becerra JP, Bissell B, et al. Transbronchial Lung cryobiopsy in patients with interstitial lung disease: a systematic review. *Ann Am Thorac Soc.* 2022;19(7):1193–202.
23. Tanaka M, Matsumoto Y, Imabayashi T, et al. Diagnostic value of a new cryoprobe for peripheral pulmonary lesions: a prospective study. *BMC Pulm Med.* 2022;22(1):226.
24. Ravaglia C, Sultani F, Piciocchi S, et al. Diagnostic yield and safety of transbronchial lung cryobiopsy for diffuse parenchymal lung diseases diagnosis: comparison between 1.7-mm and 1.9-mm probes. *Pulmonology.* 2023;S2531-0437(23):00081–8. <https://doi.org/10.1016/j.pulmoe.2023.04.003>.
25. Jiang L, Xu J, Liu C, et al. Diagnosis of peripheral pulmonary lesions with transbronchial lung cryobiopsy by guide sheath and radial endobronchial ultrasonography: a prospective control study. *Can Respir J.* 2021;2021:6947037.
26. Torky M, Elshimy WS, Ragab MA, et al. Endobronchial ultrasound guided transbronchial cryobiopsy versus forceps biopsy in peripheral lung lesions. *Clin Respir J.* 2021;15(3):320–8.
27. Furuse H, Matsumoto Y, Nakai T, et al. Diagnostic efficacy of cryobiopsy for peripheral pulmonary lesions: a propensity score analysis. *Lung Cancer.* 2023;178:220–8.
28. Kinoshita K, Morikawa K, Tsuruoka H, et al. Efficacy of combined transbronchial lung cryobiopsy and conventional forceps biopsy for lung malignancies: a prospective cohort study. *Sci Rep.* 2023;13(1):1850.
29. Liu Y, Wang F, Zhang Q, et al. Diagnostic yield of virtual bronchoscope navigation combined with radial endobronchial ultrasound guided transbronchial cryo-biopsy for peripheral pulmonary nodules: a prospective, randomized, controlled trial. *Ann Transl Med.* 2022;10(8):443.
30. Kho SS, Chan SK, Yong MC, et al. Performance of transbronchial cryobiopsy in eccentrically and adjacently orientated radial endobronchial ultrasound lesions. *ERJ Open Res.* 2019;5(4):00135–2019.
31. Chung C, Kim Y, Lee JE, et al. Diagnostic value of transbronchial lung cryobiopsy using an ultrathin cryoprobe and guide sheath for peripheral pulmonary lesions. *J Bronchology Interv Pulmonol.* 2023. <https://doi.org/10.1097/LBR.0000000000000917>.
32. Nakai T, Watanabe T, Kaimi Y, et al. Diagnostic utility and safety of non-intubated cryobiopsy technique using a novel ultrathin cryoprobe in addition to conventional biopsy techniques for peripheral pulmonary lesions. *Respiration.* 2023;102(7):503–14.
33. Nasu S, Okamoto N, Suzuki H, et al. Comparison of the utilities of cryobiopsy and forceps biopsy for peripheral lung cancer. *Anticancer Res.* 2019;39(10):5683–8.
34. Hibare KR, Goyal R, Nemani C, et al. Radial endobronchial ultrasound for the diagnosis of bronchoscopically invisible lesions: first case series from India. *Lung India.* 2017;34(1):43–6.
35. Oki M, Saka H, Kogure Y, et al. Ultrathin bronchoscopic cryobiopsy of peripheral pulmonary lesions. *Respirology.* 2023;28(2):143–51.
36. Oberg CL, Lau RP, Folch EE, et al. Novel robotic-assisted cryobiopsy for peripheral pulmonary lesions. *Lung.* 2022;200(6):737–45.
37. Chen H, Yu X, Yu Y, et al. Diagnostic performance of cryobiopsy guided by radial-probe EBUS with a guide sheath for peripheral pulmonary lesions. *J Bras Pneumol.* 2023;49(1):e20220200.
38. Nakai T, Watanabe T, Kaimi Y, et al. Safety profile and risk factors for bleeding in transbronchial cryobiopsy using a two-scope technique for peripheral pulmonary lesions. *BMC Pulm Med.* 2022;22(1):20.
39. Kim SH, Mok J, Jo EJ, et al. The additive impact of transbronchial cryobiopsy using a 1.1-mm diameter cryoprobe on conventional biopsy for peripheral lung nodules. *Cancer Res Treat.* 2023;55(2):506–12.
40. Ankudavicius V, Miliauskas S, Poskiene L, et al. Diagnostic yield of transbronchial cryobiopsy guided by radial endobronchial ultrasound and fluoroscopy in the radiologically suspected lung cancer: a single institution prospective study. *Cancers.* 2022;14(6):1563.
41. Matsumoto Y, Nakai T, Tanaka M, et al. Diagnostic outcomes and safety of cryobiopsy added to conventional sampling methods: an observational study. *Chest.* 2021;160(5):1890–901.
42. Taton O, Bondue B, Gevenois PA, et al. Diagnostic yield of combined pulmonary cryobiopsies and electromagnetic navigation in small pulmonary nodules. *Pulm Med.* 2018;2018:6032974.
43. Pertzov B, Gershman E, Izhakian S, et al. The lungvision navigational platform for peripheral lung nodule biopsy and the added value of cryobiopsy. *Thorac Cancer.* 2021;12(13):2007–12.
44. Matus I, Patel J. Safety and feasibility of ultrathin probe transbronchial lung cryobiopsy without balloon blocker via robotic bronchoscopy in the evaluation of peripheral lung lesions: a retrospective pilot study. *ERJ Open Res.* 2023;9(3):00638–2022.
45. Ito T, Okachi S, Ikenouchi T, et al. The value of additional conventional transbronchial biopsy in the negative results of rapid on-site evaluation during endobronchial ultrasound with guide sheath to diagnose small peripheral lung cancer. *Technol Cancer Res Treat.* 2021;20:15330338211043040.
46. van Huizen LMG, Kalverda KA, Bugiani M, et al. Rapid on-site pathology visualization of COVID-19 characteristics using higher harmonic generation microscopy. *Am J Respir Crit Care Med.* 2023;208(2):199–200.
47. Muto Y, Uchimura K, Imabayashi T, et al. Clinical utility of rapid on-site evaluation of touch imprint cytology during cryobiopsy for peripheral pulmonary lesions. *Cancers.* 2022;14(18):4493.
48. Imabayashi T, Uchino J, Yoshimura A, et al. Safety and usefulness of cryobiopsy and stamp cytology for the diagnosis of peripheral pulmonary lesions. *Cancers.* 2019;11(3):410.
49. Yarmus LB, Semaan RW, Arias SA, et al. A randomized controlled trial of a novel sheath cryoprobe for bronchoscopic lung biopsy in a porcine model. *Chest.* 2016;150(2):329–36.
50. Kho SS, Chai CS, Nyanti LE, et al. Combination of 1.1 mm flexible cryoprobe with conventional guide sheath and therapeutic bronchoscope in biopsy of apical upper lobe solitary pulmonary nodule. *BMC Pulm Med.* 2020;20(1):158.
51. Jiang S, Liu X, Chen J, et al. A pilot study of the ultrathin cryoprobe in the diagnosis of peripheral pulmonary ground-glass opacity lesions. *Transl Lung Cancer Res.* 2020;9(5):1963–73.
52. Hetzel J, Linzenbold W, Boesmueller H, et al. Evaluation of efficacy of a new cryoprobe for transbronchial cryobiopsy: a randomized, controlled in vivo animal study. *Respiration.* 2020;99(3):248–56.
53. Kim SH, Mok J, Kim S, et al. Clinical outcomes of transbronchial cryobiopsy using a 1.1-mm diameter cryoprobe for peripheral lung lesions - a prospective pilot study. *Respir Med.* 2023;107338.
54. Shen YC, Chen CH, Tu CY. Advances in diagnostic bronchoscopy. *Diagnostics.* 2021;11(11):1984.
55. Lu M, Nath S, Semaan RW. A review of robotic-assisted bronchoscopy platforms in the sampling of peripheral pulmonary lesions. *J Clin Med.* 2021;10(23):5678.
56. Andreo Garcia F, Torky M, Centeno Clemente C, et al. Transbronchial cryobiopsy of peripheral pulmonary lesions guided with real-time transthoracic ultrasonography. *Arch Bronconeumol.* 2021;57(12):772–4.
57. Arimura K, Tagaya E, Akagawa H, et al. Cryobiopsy with endobronchial ultrasonography using a guide sheath for peripheral pulmonary lesions and DNA analysis by next generation sequencing and rapid on-site evaluation. *Respir Investig.* 2019;57(2):150–6.
58. Udagawa H, Kirita K, Naito T, et al. Feasibility and utility of transbronchial cryobiopsy in precision medicine for lung cancer: prospective single-arm study. *Cancer Sci.* 2020;111(7):2488–98.

59. Pannu JK, Roller LJ, Lentz RJ, et al. Cryobiopsy With Radial UltraSound Guidance (CYRUS): a pilot randomized controlled study. *J Bronchology Interv Pulmonol*. 2021;28(1):21–8.
60. Benn BS, Gmehlin CG, Kurman JS, et al. Does transbronchial lung cryobiopsy improve diagnostic yield of digital tomosynthesis-assisted electromagnetic navigation guided bronchoscopic biopsy of pulmonary nodules? A pilot study. *Respir Med*. 2022;202:106966.
61. Ernst A, Eberhardt R, Wahidi M, et al. Effect of routine clopidogrel use on bleeding complications after transbronchial biopsy in humans. *Chest*. 2006;129(3):734–7.
62. Giri M, Huang G, Puri A, et al. Efficacy and safety of cryobiopsy vs. forceps biopsy for interstitial lung diseases, lung tumors, and peripheral pulmonary lesions: an updated systematic review and meta-analysis. *Front Med*. 2022;9:840702.
63. DeMaio A, Thiboutot J, Yarmus L. Applications of cryobiopsy in airway, pleural, and parenchymal disease. *Expert Rev Respir Med*. 2022;16(8):875–86.
64. Huang H, Wu N, Tian S, et al. Application of bronchoscopy in the diagnosis and treatment of peripheral pulmonary lesions in China: a national cross-sectional study. *J Cancer*. 2023;14(8):1398–406.
65. Gupta A, Youness H, Dhillon SS, et al. The value of using radial endobronchial ultrasound to guide transbronchial lung cryobiopsy. *J Thorac Dis*. 2019;11(1):329–34.
66. Hetzel J, Eberhardt R, Petermann C, et al. Bleeding risk of transbronchial cryobiopsy compared to transbronchial forceps biopsy in interstitial lung disease - a prospective, randomized, multicentre cross-over trial. *Respir Res*. 2019;20(1):140.
67. Dhooria S, Sehgal IS, Bal A, et al. Transbronchial lung biopsy with a flexible cryoprobe during rigid bronchoscopy: standardizing the procedure. *Lung India*. 2016;33(2):248–9.
68. Herath S, Yap E. Novel hybrid cryo-radial method: an emerging alternative to CT-guided biopsy in suspected lung cancer. A prospective case series and description of technique. *Respirol Case Rep*. 2017;6(2):e00287.
69. Goel MK, Kumar A, Maitra G, et al. Safety and diagnostic yield of transbronchial lung cryobiopsy by flexible bronchoscopy using laryngeal mask airway in diffuse and localized peripheral lung diseases: a single-center retrospective analysis of 326 cases. *Lung India*. 2021;38(2):109–16.
70. Herath S. Using cryobiopsy with Radial EBUS in high-bleeding-risk, peripheral pulmonary lesions (PPL): description of cases and technique. *Respirol Case Rep*. 2023;11(4):e01125.
71. Madan K, Mittal S, Hadda V, et al. Cryoprobe transbronchial lung biopsy with flexible bronchoscope using Arndt endobronchial blocker. *Lung India*. 2019;36(3):241–3.
72. Herath S, Wong C, Dawkins P, et al. Cryobiopsy with radial-endobronchial ultrasound (Cryo-Radial) has comparable diagnostic yield with higher safety in comparison to computed tomography-guided transthoracic biopsy for peripheral pulmonary lesions: An exploratory randomised study. *Intern Med J*. 2023;53(8):1390–9. <https://doi.org/10.1111/imj.15833>.
73. Verhoeven RLJ, Vos S, van der Heijden EHF. Multi-modal tissue sampling in cone beam CT guided navigation bronchoscopy: comparative accuracy of different sampling tools and rapid on-site evaluation of cytopathology. *J Thorac Dis*. 2021;13(7):4396–406.
74. Herath S. Use of the 1.1 mm cryoprobe through the radial EBUS GS (without the need for a bronchial blocker) to obtain samples safely in diagnosing PPL. *Respirol Case Rep*. 2023;11(4):e01128.
75. Paver E, O'Toole S, Cheng XM, et al. Updates in the molecular pathology of non-small cell lung cancer. *Semin Diagn Pathol*. 2021;38(5):54–61.
76. Abdayem P, Planchard D. Update on molecular pathology and role of liquid biopsy in non-small cell lung cancer. *Eur Respir Rev*. 2021;30(161):200294.
77. Fernandes MGO, Vilarica AS, Fernandes B, et al. Improving non-small-cell lung cancer survival through molecular characterization: perspective of a multidisciplinary expert panel. *Pulmonology*. 2023;18:S2531. <https://doi.org/10.1016/j.pulmoe.2022.11.009>.
78. Bianchi R, Dubini A, Ascoli S, et al. Transbronchial cryobiopsy: an effective tool in the diagnosis of lymphoproliferative disorders of the lung. *ERJ Open Res*. 2020;6(3):00260–2019.
79. Genova C, Tagliabue E, Mora M, et al. Potential application of cryobiopsy for histo-molecular characterization of mediastinal lymph nodes in patients with thoracic malignancies: a case presentation series and implications for future developments. *BMC Pulm Med*. 2022;22(1):5.
80. Hetzel J, Mauti LA, Winkler J, et al. Only EBUS-guided mediastinal lymph node cryobiopsy enabled immunotherapy in a patient with non-small cell lung cancer. *J Clin Med*. 2023;12(6):2355.
81. Doglioni C, Ravaglia C, Chilosi M, et al. Covid-19 interstitial pneumonia: histological and immunohistochemical features on cryobiopsies. *Respiration*. 2021;100(6):488–98.
82. Ravaglia C, Doglioni C, Chilosi M, et al. Clinical, radiological and pathological findings in patients with persistent lung disease following SARS-CoV-2 infection. *Eur Respir J*. 2022;60(4):2102411.
83. Oldani S, Ravaglia C, Bensai S, et al. Pathophysiology of light phenotype SARS-CoV-2 interstitial pneumonia: from histopathological features to clinical presentations. *Pulmonology*. 2022;28(5):333–44.
84. Haentschel M, Boeckeler M, Ehab A, et al. Cryobiopsy increases the EGFR detection rate in non-small cell lung cancer. *Lung Cancer*. 2020;141:56–63.
85. Nishimatsu K, Matsumoto Y, Kashima J, et al. Concordance between cryobiopsy and forceps biopsy specimens in assessment of immunohistochemistry staining for non-small cell lung carcinoma. *Transl Lung Cancer Res*. 2023;12(6):1245–55.
86. Arimura K, Kondo M, Nagashima Y, et al. Comparison of tumor cell numbers and 22C3 PD-L1 expression between cryobiopsy and transbronchial biopsy with endobronchial ultrasonography-guide sheath for lung cancer. *Respir Res*. 2019;20(1):185.
87. Park D, Lee D, Kim Y, et al. Cryobiopsy: a breakthrough strategy for clinical utilization of lung cancer organoids. *Cells*. 2023;12(14):1854.
88. Casutt A, Kinj R, Ozsahin EM, et al. Fiducial markers for stereotactic lung radiation therapy: review of the transthoracic, endovascular and endobronchial approaches. *Eur Respir Rev*. 2022;31(163):210149.
89. Nishii Y, Yasuma T, Ito K, et al. Factors leading to failure to diagnose pulmonary malignant tumors using endobronchial ultrasound with guide sheath within the target lesion. *Respir Res*. 2019;20(1):207.
90. Huber RM, Kauffmann-Guerrero D, Hoffmann H, et al. New developments in locally advanced nonsmall cell lung cancer. *Eur Respir Rev*. 2021;30(160):200227.
91. Reck M, Rodríguez-Abreu D, Robinson AG, et al. Pembrolizumab versus chemotherapy for PD-L1-positive non-small-cell lung cancer. *N Engl J Med*. 2016;375(19):1823–33.
92. Wessels S, Muley T, Christopoulos P, et al. Comprehensive serial biobanking in advanced NSCLC: feasibility, challenges and perspectives. *Transl Lung Cancer Res*. 2020;9(4):1000–14.
93. Goldsteen PA, Yoseif C, Dolga AM, et al. Human pluripotent stem cells for the modelling and treatment of respiratory diseases. *Eur Respir Rev*. 2021;30(161):210042.
94. Du Rand IA, Barber PV, Goldring J, et al. British Thoracic Society guideline for advanced diagnostic and therapeutic flexible bronchoscopy in adults. *Thorax*. 2011;66(Suppl 3):iii1–21.
95. Lee HJ, Corbetta L. Training in interventional pulmonology: the European and US perspective. *Eur Respir Rev*. 2021;30(160):200025.
96. Guedes F, Ferreira AJ, Dionísio J, et al. Pre- and post-COVID practice of interventional pulmonology in adults in Portugal. *Pulmonology*. 2022;S2531-0437(22):00070–8. <https://doi.org/10.1016/j.pulmoe.2022.02.009>.