



**PE 001 A PLEASANT FINDING**

Page4

**PE 002 MALIGNANT CHEST PAIN**

Page4

**PE 003 AN ORGAN NOT TO FORGET**

Page5

**PE 004 PULMONARY ADENOCARCINOMA: *EGFR/ALK/ROS1*  
STATUS DID NOT CORRELATE WITH PD-L1**

Page5

**PE 005 PD-L1 AS A ROUTINE BIOMARKER IN ANATOMICAL PA-  
THOLOGY LABS**

Page6

**PE 006 THE TNM CLASSIFICATION FOR LUNG CANCER - WHAT  
CHANGES IN THE EIGHTH EDITION**

Page6

**PE 007 MANAGEMENT OF VERY ELDERLY PATIENTS WITH NON-  
-SMALL CELL LUNG CANCER: A SINGLE-CENTER EXPERIENCE**

Page7

**PE 008 AN OPPORTUNISTIC FINDING - A CASE REPORT**

Page7

**PE 009 PATIENTS HOSPITALIZED WITH PULMONARY CANCER -  
THE REALITY IN A PULMONOLOGY DEPARTMENT**

Page8

**PE 010 ENDOBRONCHIAL HAMARTOMA - FREQUENT TUMOR, RARE  
LOCATION**

Page8

**PE 011 MALIGNANT PLEURAL MESOTHELIOMA - 10 YEARS ANALYSIS**

Page9

**PE 012 BRAF-V600E ADVANCED LUNG ADENOCARCINOMA DE-  
TECTED BY NEXT GENERATION SEQUENCING - A NEW THERA-  
PEUTIC OPPORTUNITY**

Page9

**PE 013 PULMONARY NODULES - FOLLOW-UP PROTOCOL: MAKES  
SENSE IN ALL PATIENTS?**

Page10

**PE 014 MUCOEPIDERMOID CARCINOMA OF THE LUNG: A RARE  
ENTITY - CLINICAL CASE**

Page10

**PE 015 ATYPICAL METASTASIS OF LUNG CANCER - CASE REPORT**

Page11

**PE 016 ATYPICAL PRESENTATION OF LUNG CANCER - CLINICAL  
CASE**

Page12

**PE 017 MEDIASTINAL MASS IN A YOUNG ADULT**

Page12

**PE 018 REPORT ON TWO CASES OF ADENOCARCINOMA OF THE  
LUNG STAGE IV: SIMILAR IN APPROACH, DIFFERENT IN OUTCOME**

Page13

**PE 019 COLLISION TUMOR OF THE LUNG**

Page13

**PE 020 MENTAL CONFUSION AS A FIRST SIGN OF LUNG CANCER -  
CLINICAL CASE**

Page14

**PE 021 COMPLICATION OF INTRAVESICAL CALMETTE-GUERIN  
BACILLUS IMMUNOTHERAPY - CLINICAL CASE**

Page14

**PE 022 PULMONARY CARCINOSARCOMA - DIAGNOSTIC APPROACH  
OF THREE CASES**

Page15

**PE 023 PLEURAL MESOTHELIOMA: NEVER SAY NEVER**

Page15

**PE 024 LTIPLE LUNG CANCER - CASE REPORT**

Page16

**PE 025 INFECTED LUNG NEOPLASM - WHEN PET IS NOT ENOUGH!**

Page17

**PE 026 AN UNUSUAL METHOD TO DIAGNOSE MESOTHELIOMA - A  
CASE REPORT**

Page17

**PE 027 PERSISTENT HEMOPTYSIS WITH NO APPARENT CAUSE**

Page18

**PE 028 CHRONIC PULMONARY THROMBOEMBOLISM: A PARADIG-  
MATIC CASE OF THE DISEASE'S NATURAL HISTORY**

Page18

**PE 029 NODULES AND CAVITATIONS: NOT ALWAYS TB, NOT AL-  
WAYS MALIGNANCY**

Page19

**PE 030 PULMONARY ARTERIOVENOUS MALFORMATIONS: 3 CLINICAL  
REPORTS**

Page20

**PE 031 PULMONARY ARTERIAL HYPERTENSION PRESENTING WITH  
BILATERAL MICRONODULES AND ADENOPATHIES: A DIAGNOSTIC  
CHALLENGE**

Page20

**PE 032 SCHISTOSSOMIASIS ASSOCIATED PULMONARY HYPER-  
TENSION, A CASE REPORT**

Page21

**PE 033 PULMONARY EMBOLISM IN A GLANZMANN'S THROMBAS-  
THENIA PATIENT**

Page22

**PE 034 FALCIFORM CELL ANEMIA: A CAUSE OF PULMONARY  
HYPERTENSION, MULTIPLE MECHANISMS**

Page23

**PE 035 CHRONIC THROMBOEMBOLIC PULMONARY HYPERTENSION  
- CASE REPORT**

Page23

**PE 036 SARCOIDOSIS VS HEART INVOLVEMENT IN CVID. NEW  
HORIZONS**

Page24

**PE 037 SARCOIDOSIS: A DIFFICULT CONTROL CASE**

Page25

**PE 038 ACUTE FIBRINOUS AND ORGANIZING PNEUMONIA (AFOP),  
A RARE ENTITY - TWO CLINICAL CASES**

Page25

**PE 039 CHEMICAL PNEUMONITIS - A CLINICAL CASE**

Page26

**PE 040 A CASE OF PULMONARY FIBROSIS SECONDARY TO OXAL-  
IPLATIN: FROM RARITY TO REALITY**

Page26

**PE 041 DIFFUSE ALVEOLAR HEMORRHAGE (DAH) SECONDARY TO DABIGATRAN- A CASE REPORT**

Page27

**PE 042 THE DIAGNOSTIC CHALLENGE OF THE SOLITARY PULMONARY NODULE - CLINICAL CASE**

Page27

**PE 043 EOSINOPHILIC PNEUMONIA IN A PATIENT WITH BRONCHIAL ASTHMA**

Page28

**PE 044 SARCOIDOSIS INDUCED BY CAPECITABINE - A CASE REPORT**

Page28

**PE 045 PNEUMOLOGY AS A BRIDGE FOR THE DIAGNOSIS OF A SYSTEMIC PATHOLOGY: A CLINICAL CASE OF HYPEREOSINOPHILIC SYNDROME**

Page29

**PE 046 STUDY OF CAUSES OF HEMOPTYSIS IN A DISTRICT HOSPITAL**

Page29

**PE 047 MANAGEMENT OF PNEUMOTHORAX BY MEDICAL THORACOSCOPY: SMALL SERIES OF 5 CASES**

Page30

**PE 048 PERSISTENT COUGH AND BRONCHIAL OBSTRUCTION, "A ROCK IN THE SHOE"**

Page30

**PE 049 OSTEOCONDROPLASTIC TRAQUEOPATHY IN PATIENT WITH STRIDOR: REPORT OF A CLINICAL CASE**

Page31

**PE 050 DIAGNOSIS AND ENDOSCOPIC TREATMENT OF TWO RARE ENTITIES**

Page31

**PE 051 TRACHEOBRONCHOPATHIA OSTEOCHONDROPLASTICA: THE "ROCK GARDEN" OF BRONCOLOGY**

Page32

**PE 052 ENDOBRONCHIAL INVOLVEMENT OF LARGE B-CELL NON-HODGKIN'S LYMPHOMA**

Page33

**PE 053 CT - GUIDED TRANSTHORACIC LUNG BIOPSY COMPLICATIONS: A PULMONOLOGY DEPARTMENT EXPERIENCE**

Page33

**PE 054 MINERAL OIL ASPIRATION AS A DIFFERENTIAL DIAGNOSIS OF TAQUIPNEIA IN INFANTS**

Page34

**PE 055 URINOTHORAX, A RARE CAUSE OF PLEURAL EFFUSION**

Page35

**PE 056 THORACIC ENDOMETRIOSIS, A RARE CAUSE OF HAEMOTHORAX**

Page35

**PE 057 PLEURAL EFFUSION - AN UNEXPECTED CAUSE**

Page36

**PE 058 PSEUDOTUMOR OR FIBROUS TUMOR OF THE PLEURA, THAT'S THE QUESTION**

Page36

**PE 059 INTRAPLEURAL INSTILLATION OF FIBRINOLYTICS AND DNASE IN PLEURAL INFECTIONS - IS THIS AN OPTION? - TWO CLINICAL CASES**

Page37

**PE 060 RECURRENCE OF PULMONARY TUBERCULOSIS: A 10-YEAR RETROSPECTIVE STUDY IN A UNIT SPECIALISED IN THE MANAGEMENT AND TREATMENT OF TUBERCULOSIS IN PORTUGAL**

Page38

**PE 061 TUBERCULOSIS - RETREATMENTS FROM 2000 TO 2015 IN CDP SANTARÉM**

Page38

**PE 062 LATENT TUBERCULOSIS TESTING - THE CHANGING PARADIGM**

Page39

**PE 063 PULMONARY TUBERCULOSIS (PT) IN A PULMONOLOGY WARD - 5 YEAR OBSERVATIONS**

Page40

**PE 064 BREAST TUBERCULOSIS - A RARE EXTRA-PULMONARY PRESENTATION**

Page40

**PE 065 TUBERCULOUS OTITIS MEDIA: A REMINDER OF AN IMPORTANT CLINICAL LESSON**

Page41

**PE 066 CEREBRAL AIR EMBOLISM - CASE REPORT**

Page41

**PE 067 WHEN GUILLAIN-BARRÉ SYNDROME MEETS THE RESPIRATORY ICU: A DESCRIPTIVE STUDY OF PATIENTS ADMITTED OVER THE LAST 5 YEARS**

Page42

**PE 068 PNEUMOMEDIASTINUM IN A PATIENT ON HIGH FLOW OXYGEN THERAPY**

Page42

**PE 069 BRONCHODILATOR RESPONSE IN NORMAL BASE SPIROMETRY: IS IT REALLY NECESSARY?**

Page43

**PE 070 THE ROLE OF COMMUNITY PHARMACIES IN SCREENING AND SUBSEQUENT MANAGEMENT OF CHRONIC OBSTRUCTIVE PULMONARY DISEASE**

Page43

**PE 071 INCAPACITY CAUSED BY RESPIRATORY DISEASE IN THE LOURES - ODIVELAS ACES**

Page44

**PE 072 COMPARATIVE ANALYSIS BETWEEN ASTHMATIC AND CHRONIC OBSTRUCTIVE PULMONARY DISEASE SMOKERS ATTENDING A TOBACCO CESSATION PROGRAM**

Page44

**PE 073 PROLONGED STEROID THERAPY AND PULMONARY ASPERGILLOSIS**

Page45

**PE 074 NECROTISING PNEUMONIA BY NOCARDIA IN AN IMMUNOCOMPETENT PATIENT: CLINICAL CASE**

Page45

**PE 075 PNEUMONIAS IN A PNEUMOLOGY WARD**

Page46

**PE 076 ACTINOMYCETES AND LUNG: A RARE ASSOCIATION**

Page47

**PE 077 GOOD'S SYNDROME - A MYSTERIOUS DISEASE. REPORT OF 2 RARE CASES**

Page47



## POSTERS EXPOSTOS

**PE 078 PNEUMONIA POR PNEUMOCYSTIS JIROVECCI EM DOENTE NÃO-VIH**

Page48

**PE 079 BORDETELLA BRONCHISEPTICA IN AN IMMUNOCOMPROMISED PATIENT: CASE REPORT**

Page49

**PE 080 NECROTIZING PNEUMONIA VERSUS CAVITATING CARCINOMA**

Page49

**PE 081 IMPACT OF FUNGAL INFECTIONS IN LUNG TRANSPLANT**

Page50

**PE 082 PULMONARY ABSCESS BY METHICILLIN-RESISTANT *STAPHYLOCOCCUS AUREUS* AS COMPLICATION OF PULMONARY THROMBOEMBOLISM - CASE REPORT**

Page50

**PE 083 WHEN PAIN IS THE KEY TO A DIAGNOSIS**

Page51

**PE 084 RAMP: A MODE OF COMFORT OR CONFLICT?**

Page52

**PE 085 TREATMENT OF CENTRAL SLEEP APNEA WITH SERVO-VENTILATION IN ARNOLD-CHIARI SYNDROME TYPE I - CLINICAL CASE**

Page52

**PE 086 SLEEP BREATHING DISORDERS DIAGNOSIS: FROM HOSPITAL TO HOME. EXPERIENCE OF VILA FRANCA DE XIRA HOSPITAL**

Page53

**PE 087 QUALITY OF LIFE IN PATIENTS WITH OBESITY-HYPOVENTILATION SYNDROME (OHS) WHO PERFORM NON-INVASIVE VENTILATION (NIV)**

Page53

**PE 088 THE ROLE OF GENDER IN THE INTENSITY OF CLINICAL FOLLOW UP IN PATIENTS WITH APAP THERAPY**

Page54

**PE 089 CAN PATIENT AGE INFLUENCE APAP THERAPY CLINICAL FOLLOW INTENSITY?**

Page55

**PE 090 WHEN CHANGING THE VENTILATION MODE OPTIMIZES THERAPY**

Page55

**PE 091 A RARE CAUSE OF BRONCHIECTASIS: BASED ON A CASE REPORT**

Page56

**PE 092 SEVERE ASTHMA? IT'S "PEANUTS"...**

Page56





PE 001

### A PLEASANT FINDING

**A Pais, Al Coutinho, M Cardoso, A Pignatelli, C Bárbara**  
Centro Hospitalar de Lisboa Norte

Key-words: mass, debridement, hamartoma

37-year-old male patient, salesman. Sporadic smoker. With a past history of allergic rhinitis and chronic gastritis. With no usual medication. In January 2017, he was diagnosed with a respiratory infection, having completed ten days of empirical antibiotic therapy with amoxicillin / clavulanic acid, with clinical improvement. In May 2017, he underwent thoracic xray, which revealed homogeneous opacity of triangular morphology in the middle lobe of the right lung. He denied respiratory or systemic complaints, namely dyspnoea, cough, expectoration, hemoptysis, chest pain, fever, weakness or weight loss. He was referred to the Pneumology consultation for etiological study. He did a CT scan, which revealed collapse of the right lobe of the middle lung, with almost total occlusion of the corresponding bronchus, due to hypodense and spherical intraluminal lesion. Bronchofibrosocopy showed almost complete occlusion of the intermediate bronchus, by a polypoid mass. Subsequently, in rigid bronchoscopy, argon plasma therapy and mechanical debridement were performed, with reperfusion of the entire bronchial tree. The anatomopathological examination was compatible with hamartoma.

Hamartomas are the most common benign tumors of the lung. They are composed of tissues that are usually present in the respiratory tract (epithelial tissue, adipose tissue, smooth muscle, fibrous tissue and cartilage) but replicate in a disorganized way. The vast majority (> 90%) are located in the periphery, with endobronchial hamartomas being rare (~ 5%). They appear more frequently between the fourth and fifth decade of life, and in the male sex (M: F = 2.5: 1). They are usually asymptomatic. Occasionally, they may cause symptoms of bronchial obstruction such as dyspnoea, cough or hemoptysis. If symptomatic, surgical resection is recommended, with minimal recurrence rates. The prognosis is excellent with negligible malignant transformation risk.

The importance of these tumors is based on the differential diagnosis of other, more aggressive tumors, especially carcinomas or carcinoid lung tumors.

PE 002

### MALIGNANT CHEST PAIN

**A Pais, C Pereira, C Antunes, V Pereira, Al Coutinho, A Feliciano, C Quadros, A Ribeiro, L Carvalho, C Bárbara**  
Centro Hospitalar de Lisboa Norte

Key-words: pain, S100, sarcoma

26-year-old male patient, supermarket employee. Smoker of 10 pack-year. Past history of bronchial asthma in childhood. No relevant family history. Without usual ambulatory medication. With a history of dry cough and chest pain in the posterior region of the left hemithorax, for about two years, having had at that time, chest X-ray without pathological findings, and the clinical picture was interpreted as a muscular contracture. For nonspecific complaints of general malaise, weakness and weight loss of 5 kg in the last month, he consulted the general practitioner. For alterations in the chest xray, he underwent thoracic CT, which showed a massive solid mass, about 14 cm longer, partially occupying the mediastinum, and partially the left lung, with loss of cleavage planes with the aorta and the left pulmonary artery, associated with homolateral pleural effusion and lytic destruction of the posterior arch of an adjacent rib. The right lung had no alterations and there were no lymphadenopathy. He was hospitalized for an etiological investigation. He underwent bronchofibrosocopy that revealed inflammatory signs and extrinsic compression of the left bronchial tree, but airway permeability was maintained. Biopsies were performed at the lingula and at B1 / B2 levels, which revealed mesenchymal neoplasia constituted by spindle cells with S100 positivity, favoring the diagnosis of Malignant Tumor of the Peripheral Nerve. He was referred to the Oncology Department, for staging and treatment, having started chemotherapy and concomitant radiotherapy.

The Malignant Peripheral Nerve Sheath Tumor, previously called Malignant Schwannomma, is a rare sarcoma (10% of sarcomas, 1% of malignant neoplasms) and aggressive, originating from peripheral or cranial nerves. They may occur spontaneously, or in association with Neurofibromatosis type-1 (NF-1) or von Recklinghausen's Disease, in about 50% of cases. It is most common between the 3rd and 5th decade of life, and in patients with previous radiation exposure. Often, it presents as a painful, fast-growing mass and may be associated with other neurological symptoms such as weakness or paresthesias. The diagnosis is confirmed by the pathological and immunohistochemical examination (50 to 90% of the cases stain for the S100 protein). Staging is based on histological grade, tumor size and presence or absence of metastases. The treatments available are surgery, radiotherapy and chemotherapy.

They are neoplasms with a very reserved prognosis, highly resistant to chemotherapy and with a high rate of recurrence, so it is so important to perform a rapid and effective diagnosis.



PE 003

### AN ORGAN NOT TO FORGET

A Pais, W Videira, P Barradas, E Vitorino, A Pignatelli, C Bárbara  
Centro Hospitalar de Lisboa Norte

Key-words: swelling, anterior mediastinum, carcinoma, radiotherapy

39-year-old male, non-smoker. With diagnosis of multinodular goiter with hypothyroidism, since the eighteen years of age. Medicated with levothyroxine. No other relevant personal or family history. Referred by the General Practitioner, to the Emergency Department of the Santa Maria's Hospital, because of "new" heart murmur, and swelling in the left hemithorax. He reported fatigue for minor exertion and weight loss of 5 kg in the last six months. He also reported dry cough, of nocturnal predominance. He denied fever. He denied dyspnea, dysphagia, or dysphonia. At the physical examination, he was without fever, hemodynamically stable, eupnoeic and with peripheral oxygen saturation of 99%. He presented with left parasternal non painful swelling of stony consistency, as well as with, digital clubbing and a holosystolic cardiac murmur grade III / VI. The chest xray showed left parasternal mass of well delineated contours. Transthoracic echocardiography revealed circumferential pericardial effusion with no functional significance, and severe pulmonary hypertension (estimated PAP of 65 + 8 mmHg). He was hospitalized for further investigation. A thoracic CT scan revealed a large heterogeneous mass in the anterior mediastinum, with a larger diameter of about 9 cm, which invaded the thoracic wall, right ventricle, trunk of the pulmonary artery, and with associated pericardial effusion and bilateral pleural effusion. He underwent thoracoscopy with a biopsy that revealed slightly differentiated, non-keratinizing carcinoma. In an additional immunohistochemical study, GLUT1 and CD117 (c-kit) were positive, favoring the thymic origin of the tumor. Admitting a stage IVa thymic carcinoma, he was referred to the Oncology Department, and started thoracic radiotherapy, fulfilling 20 Gy, during five sessions, and is currently, undergoing chemotherapy, with paclitaxel and carboplatin.

Thymic carcinomas are rare tumors, accounting for 0.2 to 1.5% of malignant neoplasms. In its differential diagnosis, we should include other malignant lesions such as lymphomas, thyroid or parathyroid tumors, midline NUT carcinomas, germinal neoplasms, metastases, or benign lesions such as thymomas, retrograde goiter, cysts (pericardial, thymic, bronchial, esophageal), reactive lymphadenitis or vascular aneurysms. The definitive diagnosis is made by histological confirmation. First-line treatment depends on the stage of the disease. Thymic carcinomas are found, often in advanced stages, at the time of diagnosis, with radiotherapy being the treatment of choice. However, the prognosis remains very reserved, with a 5-year survival rate of 30 to 50%.

PE 004

### PULMONARY ADENOCARCINOMA: *EGFR/ALK/ROS1* STATUS DID NOT CORRELATE WITH PD-L1

L Carvalho<sup>1-3</sup>, A Alarcão<sup>1-3</sup>, AF Ladeirinha<sup>1-3</sup>, MR Silva<sup>1-3</sup>, L Teixeira<sup>1</sup>, F Silva<sup>4</sup>, JM Ruivo<sup>4</sup>, P Teixeira<sup>4</sup>, V Sousa<sup>1-3</sup>

<sup>1</sup>Institute of Anatomical and Molecular Pathology, Faculty of Medicine of the University of Coimbra, Coimbra; <sup>2</sup>CIMAGO - Research Center for Environment, Genetics and Oncobiology, Faculty of Medicine, University of Coimbra, Coimbra; <sup>3</sup>Centre of Pulmonology, Faculty of Medicine of the University of Coimbra; <sup>4</sup>Anatomical Pathology, University Hospital Coimbra

Key-words: PD-L1, *EGFR*, *ALK*, *ROS1*

**Introduction:** Anti PD/PD-L1 immunotherapy dependent from PD-L1 immunohistochemistry raises controversy due to low accuracy of PD-L1 scoring/immunohistochemistry staining. This biomarker runs together with *EGFR/ROS1/ALK* status for target therapy.

**Objective:** A series of 55 cases of pulmonary adenocarcinomas with Molecular Pathology determinations after clinicians demanding had PD-L1 (22C3 DAKO) immunostaining.

**Methods:** PD-L1 immunoexpression was correlated with *EGFR* (exons 19 and 21) and *ALK* and *ROS1* status through Bond Max<sup>®</sup> or Ventana Ultra<sup>®</sup>. *EGFR* mutations were search by Sanger sequencing and *ALK/ROS1* status were assessed by FISH (ZytoLight SPEC ALK/EML4 Tricheck and ZytoLight SPEC ROS1 Dual Color Break Apart Probe FISH assay, respectively).

**Results:** From the PD-L1 positive cases (<5% - 19), one case (5% positive cells) had *EGFR* L858R mutation. All cases were *ALK* and *ROS1* negative. From the 36 negative PD-L1 cases, 5 presented *EGFR* E746\_A750 or L858R mutations.

**Conclusion:** This work showed that there might not be concomitance between PD-L1 and *EGFR*, *ALK* or *ROS1* genes. Thereby more studies are needed to infer about PD-L1 and other genes status to identify patients who will benefit from anti-PD-1/anti-PD-L1 therapy or other therapy management.

**Conflict of interests:** MSD: PD-L1 22C3 DAKO





PE 005

### PD-L1 AS A ROUTINE BIOMARKER IN ANATOMICAL PATHOLOGY LABS

L Carvalho<sup>1-3</sup>, A Alarcão<sup>1-3</sup>, AF Ladeirinha<sup>1-3</sup>, MR Silva<sup>1-3</sup>, L Teixeira<sup>1</sup>, F Silva<sup>4</sup>, JM Ruivo<sup>4</sup>, P Teixeira<sup>4</sup>, V Sousa<sup>1-3</sup>

<sup>1</sup>Institute of Anatomical and Molecular Pathology, Faculty of Medicine of the University of Coimbra, Coimbra; <sup>2</sup>CIMAGO - Research Center for Environment, Genetics and Oncobiology, Faculty of Medicine, University of Coimbra, Coimbra; <sup>3</sup>Centre of Pulmonology, Faculty of Medicine of the University of Coimbra; <sup>4</sup>University Hospital Anatomical Pathology Coimbra

Key-words: PD-L1, 22C3, Bond Max, Ventana Ultra

**Introduction:** Some types of tumoural cells overexpress PD-L1 (Programmed Death Ligand 1). This ligand is a facilitator for tumour growth and metastasis. The blockage of either PD/PD-L1 is an actual targeted therapy in nearly 50% of pulmonary carcinomas.

**Objective:** PD-L1 immunostaining evaluation and validation in pulmonary carcinoma, by using two different immunostainers.

**Methods:** Bond Max® and Ventana Ultra® immunostainers, were used to follow 22C3 DAKO at 1:100 dilution, according with manufacturers recommendation after placenta/macrophages positive controls aferition.

**Results:** The 138 Lab positive cases immunostained for PD-L1 corresponded to Bond Max® 7/24 and Ventana Ultra® 58/114, scored trough the following cut-off: ++< 5%; ++ 5-50% and +++ >50%, to encompass the recognized therapy prescription. This series concerned Adenocarcinomas 22-Bond/ 70-Ventana and Epidermoid carcinomas 1-Bond/ 19-Ventana (occasional cases of Pleomorphic (+++), Large Cell (+++) and Adenosquamous Carcinomas (++) were also immunostained).

**Discussion:** The bronchial-pulmonary biopsies (bronchial/trans-thoracic) were not immunostained twice.

The positive controls (placenta and also macrophages internal positive control) were consistently applied in all runs of both immunostainers. The referred positive cells immunoscore was applied consistently in all cases and positive intensity was also consistent either as complete or incomplete cellular cytoplasmatic membrane immunostaining. We then advise both immunostainers for 22C3 DAKO antibody use for anti-PD-L1 therapy prescription (VA 2016; 468: 511-525 recommendations can also be added).

**Conflict of Interests:** MSD: 22C3 DAKO Antibody.

PE 006

### THE TNM CLASSIFICATION FOR LUNG CANCER - WHAT CHANGES IN THE EIGHTH EDITION

J Abrantes, C Fernandes, J Granadeiro

Centro Hospitalar Barreiro Montijo, EPE

Key-words: Lung, Cancer, TNM, CT, Oncology

**Objectives:** Present the proposals for the eighth edition of the TNM classification for lung cancer and TNM stage groupings.

Display the different characteristics of the pulmonary neoplastic pathology, its evaluation and imaging staging.

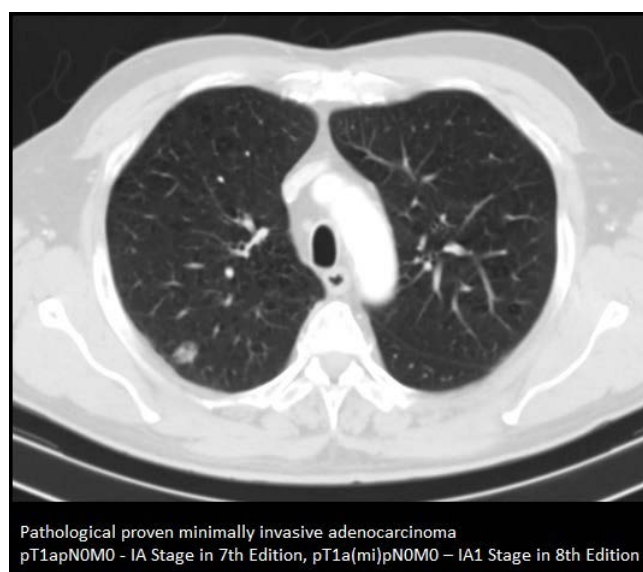
**Methods:** Exhibit the proposals for the eighth edition of the TNM classification for lung cancer and comparison with the current classification system.

Pictorial review with representative pathological cases, their characteristics and diagnostic importance.

**Results:** The adequate evaluation and classification of pulmonary neoplasms is a factor of recognized importance for the staging, treatment and prognosis of the disease, and one must update their knowledge, skills and competences in accordance to the current international consensus.

**Conclusions:** The adequate lung cancer staging is extremely important for the daily clinical practice, allowing for the establishment of a adequate treatment plan for the different stages of the disease and as predictor of survival.

It is crucial to offer patients a proper evaluation of the imaging studies, both for its profound diagnostic and prognostic impact for the patient and as a way to standardize clinical and imaging data, making it possible to compare clinical studies performed in different centers.



Pathological proven minimally invasive adenocarcinoma  
pT1apN0M0 - IA Stage in 7th Edition, pT1a(mi)pN0M0 - IA1 Stage in 8th Edition



PE 007

### MANAGEMENT OF VERY ELDERLY PATIENTS WITH NON-SMALL CELL LUNG CANCER: A SINGLE-CENTER EXPERIENCE

V Clérigo, D Hasmucrai, E Teixeira, P Alves, AS Vilarica, R Sotto-Mayor

Hospital de Dia de Pneumologia Oncológica - Serviço de Pneumologia, Centro Hospitalar Lisboa Norte, E.P.E.

Key-words: Non-small cell lung cancer, elderly, approach

**Introduction:** Lung cancer is a leading cause of cancer-related mortality. Despite high prevalence, high-level evidence specific to the elderly is sparse in lung cancer and there is no uniform age cut-off for classifying patients as elderly across the globe. Non-small cell lung cancer (NSCLC) accounts for about 80% to 85% of all lung cancers and is of particular interest, since the number of elderly is increasing all over the world, leading to a dramatic upturn in the incidence of this disease. It is therefore imperative to study and streamline the management of this disease.

**Objective:** Therefore, the aim of this study was to retrospectively evaluate the approach of NSCLC in very elderly patients aged  $\geq 80$  years.

**Material and methods:** The clinical files of all patients who consecutively underwent consultations at the Pulmonology Oncology Unit at Pulido Valente Hospital, between 1 January, 2013 and 31 December, 2016 were reviewed. Data on various patient characteristics were collected, including demographic data, non-small cell cancer characteristics, and treatment.

**Results:** We identified 86 elderly patients, corresponding to 11.1% of all NSCLC patients (n=778) followed during this period. The majority were male (67.4%), with previous or active smoking habits (68.6%), with a Charlson-age comorbidity index  $\geq 8$  (89.5%) and an Eastern Cooperative Oncology Group performance status (ECOG PS) 1 (55.8%). Arterial hypertension was the main identified comorbidity. Adenocarcinoma was the commoner pathologic type (65.1%). The majority of the patients had stage IV cancer (66.3%), mainly with one distant metastatic site (49.1%) at presentation. Chemotherapy was the first therapeutic option in 30.2% of patients, of which 11.5% completed up to three treatment lines. First-line single-agent therapy was administered more frequently in elderly patients (61.5%), being oral vinorelbine the most common.  $\leq 3$  cycles were performed at 38.5% of patients submitted to first-line QT mainly due to health deterioration (50.0%). Elderly had toxicities related to first-line chemotherapy, namely haematological (pancytopenia grade 3 and 4, 7.7%), namely; gastrointestinal (diarrhoea grade 3, 3.8%) and renal (acute renal insufficiency grade 4, 3.8%). Targeted therapy with EGFR tyrosine kinase inhibitors was the second more administered first-line treatment (17.4%), having 26.7% of these patients done  $\leq 3$  cycles due to health deterioration and toxicity. EGFR mutation evaluation was positive in 19.8% of patients. There was no case of positive ALK mutation. Curative surgery and radiotherapy, multimodal approach and support therapeutic were the first option in 8.1%, 8.1%, 10.5% e 23.6% of the patients, respectively. 69.7% of the study population died and the mean time of survival since diagnosis was 11.5 months. In the rest, the mean time of follow-up is 22.2 months.

**Discussion:** The elderly with more than 80 years although constituting a minority of the group of patients treated with NSCLC represent a population with multimorbidity and in an advanced state of the oncological disease that presents a challenge for its approach, reinforcing the need for scientific research in this age group.

PE 008

### AN OPPORTUNISTIC FINDING - A CASE REPORT

R Cabral<sup>1</sup>, A Madeira<sup>1</sup>, BG Gonçalves<sup>2</sup>

1- USF Viseu Cidade, ACES Dão Lafões; 2 - Serviço de Pneumologia A, Hospitais da Universidade de Coimbra, Centro Hospitalar e Universitário de Coimbra, EPE

Key-words: squamous cell carcinoma; opportunistic detection; smoking cessation

**Introduction:** Squamous cell carcinoma is one of the most common types of non-small cell lung carcinoma (NSCLC). It is actively related to smoking, and the risk is 15 times higher compared to non-smokers. It presents a multidisciplinary treatment and in stages I and II of NSCLC, surgery with curative intent is the therapy of choice, whereas adjuvant chemotherapy may be associated in patients at high risk.

**Case Report:** 48-year-old male, active smoker of 48 pack-years, worker in frozen and agricultural company, with exposure to birds, agricultural products and hay, with a fracture of left costal arches in 30/12/2016. He went to a General and Family Medicine consultation on 23/01/2017, with the result of control chest radiography of post-traumatic rib fracture. This identified a consolidated fracture of the left costal arches; however, in the middle floor of the right lung field a vaguely nodular density of about 35mm was projected into the pleura. He returned in 03/02/2017 with a thoracic CT result, which showed a solid nodular formation, with lobulated and spiculated contours, with cavitated areas, in the right upper lobe (RUL) of 40x35mm, without associated mediastinal adenopathies. He was immediately referred to the Department of Pulmonology where he initially performed bronchofibroscopy without alterations to direct visualization. The bronchial aspirate was negative for neoplastic cells and the BAL was suspicious for them. He was then submitted to a CT-guided TTNA whose histology revealed squamous cell carcinoma with PDL-1 expression in 70%. He also performed a PET-CT scan showing a hypermetabolic cavitated mass in RUL and nodular opacities dispersed by both lungs without increased uptake of FDG-F18 and a cranial CT without changes. The case was presented in a therapeutic decision meeting, where it was decided that on 26/04/2017 it would be performed a right upper lobectomy with mediastinal lymphadenectomy.

He presented good postoperative evolution. It was confirmed that it was an epidermoid carcinoma with invasion of the visceral pleura, without metastases (T2aNOMx). Given this same invasion, the patient will perform adjuvant chemotherapy with cisplatin and gemcitabine in cycles of 21 in 21 days.

**Discussion:** The role of General Practitioner is paramount in the opportunistic detection of possible lung neoplasms, so as to enable the patient to receive curative and not only palliative treatments. Another fundamental aspect within it, is the promotion of smoking cessation, which in the long run can prevent fatal events such as lung cancer.





PE 009

### **PATIENTS HOSPITALIZED WITH PULMONARY CANCER - THE REALITY IN A PULMONOLOGY DEPARTMENT**

**IC Oliveira, R Campanha, J Carvalho, AA Santos, M Raposo,  
JM Correia, C Matos, H Lucas, F Nogueira**  
Hospital Egas Moniz - CHLO

Key-words: pulmonary cancer; hospitalization

**Introduction:** Lung cancer is a frequent cause of hospital admissions, not only due to its usual diagnosis in a late stage but also due to its high morbidity and mortality.

**Objectives:** To analyze a group of hospitalized patients in a pulmonology department, who at the time of discharge had a diagnosis of lung cancer, in relation to the cause of admission, co-morbidities and hospital complications.

**Methods:** Retrospective, observational study, in which data were collected from clinical records of hospitalized patients with lung cancer in our Pulmonology Department between the 1 January 2016 and the 31 December 2016.

**Results:** During the period, 75 patients were hospitalized, corresponding to 93 admissions (25% of the total admissions). The majority were male (78%) with a mean age of 67 years-old. They were predominantly former smokers (57%), with a mean smoking load of 61 units pack-year. 71% had co-morbidities, the most frequent being: cardiac disease (27%) and COPD (20%). The most common histologic type was adenocarcinoma (60%) and the majority of patients presented at stage IV (83%). Regarding admission causes, the most frequent was infectious disease (38%) which was also a significant cause of hospital complications. Hospital complications occurred in 59% of admissions of which, 47% were due to infectious disease. Other frequent causes of hospital admissions were: general status deterioration, post chemotherapy pancytopenia and uncontrolled pain. On average, these patients were hospitalized for 22 days, in contrast to the mean hospitalization duration of our department which was 11 days. At discharge, 52% returned to the Oncology appointment, 9% went to palliative care and 1% went to another hospital. 38% of these patients died, in contrast to 13% in the department.

**Conclusions:** According to epidemiologic studies, lung cancer predominates in the male sex, stage IV and the most common histologic type is adenocarcinoma. Our results are in line with the scientific literature.

These patients are debilitated not only by the cancer itself, but also by the anti-neoplastic treatments and the great majority also presents other co-morbidities. This is reflected in the significant admission rates and the duration of stays. The lack of "out of hospital facilities" capable to promptly identify and treat complications as well as provide adequate end-of-life care is a problem, a necessity of the present and imperative in the future. Creating supportive networks, not only domiciliary but also out of hospital units, and a greater connection to primary care givers, is essential to avoid hospitalizations and its consequences, given the significant morbidity and mortality associated with hospitalizations in these patients.

PE 010

### **ENDOBONCHIAL HAMARTOMA - FREQUENT TUMOR, RARE LOCATION**

**M Costa, T Dias, B Ramos, P Carvalho, R Santos, A Carvalho**  
Centro Hospitalar e Universitário de Coimbra

Key-words: Endobronchial Hamartoma, Benign Tumors

Pulmonary hamartomas are the more common benign pulmonary tumors, accounting for 3% of all the pulmonary tumors. Typically, they involve the pulmonary parenchyma; endobronchial involvement is rare (1-19.5% of cases).

The authors present a case of an 80-years-old woman who presented to the emergency room with dyspnea and non-productive cough with 1 month of evolution, with aggravation in the 2 days prior to the arrival to the emergency room. There were no other remarkable symptoms. She had history of a stroke in 2013, total hysterectomy, left amaurosis, major depressive syndrome and osteoarticular pathology. In the emergency room, she presented with signs of respiratory difficulty, oxygen peripheral saturation of 79% with FiO<sub>2</sub> of 31%, tachycardia, without fever, normal blood pressure and left decreased vesicular murmur at pulmonary auscultation. The gasimetry analysis showed type 1 respiratory insufficiency (pO<sub>2</sub>/FiO<sub>2</sub> ratio=129). Analytically, she had elevated D-dimers (5.22 ug/mL [0.0-0.6]) and myocardial necrosis markers (Troponin 1.03 ng/mL [0.0-0.056], CK-MB 4.4 ng/mL [<3.6]). A Thorax CT Angiography showed multiple fill defects in the distal portion of the right pulmonary artery and in the left branches. Echocardiogram showed pronounced dilatation of the right cavities of the heart. She was admitted with the diagnosis of bilateral pulmonary thromboembolism of intermediate-high risk (PESI of 120 points) and started anticoagulation with endovenous enoxaparin 60 mg 2 times daily. The Doppler Ultrasonography of the lower extremities excluded deep vein thrombosis. A High-Resolution Thorax CT Scan was performed to clarify the maintained asymmetry of the vesicular murmur and signs of left pulmonary hyperinflation, identified on chest radiography, showing an oval image with 20 mm, hypodense, in the terminal portion of the left main bronchus. Bronchofibroscopy showed a vascularized lesion that conditioned total obstruction of the left main bronchus, whose anatomopathological study was compatible with endobronchial hamartoma. The lesion was completely resected by YAG laser bronchoscopy, with subsequent bronchial desobstruction. As complications of the procedure, of mention, are subcutaneous emphysema, pneumomediastinum, pneumopericardium and left pneumothorax requiring thoracic drainage. She presented a good clinical and radiological evolution, maintaining follow-up in external consultation.

Endobronchial hamartomas, due to their location, can manifest themselves in several ways, because of air obstruction, such as atelectasis or post-obstructive pneumonia; in the present case, the bronchial obstruction was translated as air trapping, with signs of pulmonary hyperinflation. The endoscopic approach was useful as first-line treatment, with surgical treatment being reserved for cases that lead to severe lung injury.





PE 011

### MALIGNANT PLEURAL MESOTHELIOMA - 10 YEARS ANALYSIS

D Maia, F Filipe, P Winckler, P Calvino, E Pinto, J Cardoso, R Luz  
Hospital de Santa Marta, Centro Hospitalar de Lisboa Central

Key-words: Malignant pleural mesothelioma

**Introduction:** Malignant Pleural Mesothelioma (MPM) is the most common primary malignancy of the pleura and it's usually associated with exposure to asbestos. The disease progresses insidiously and the prognosis is poor, being almost invariably fatal.

**Objective:** To describe the cases of MPM followed in our hospital, with particular emphasis on the treatment performed and overall survival.

**Methods:** The database of the pathology department was consulted and the clinical files of the patients with a primary diagnosis of MPM between 2007 and 2016 were analyzed. Patients who were not treated and followed up at our center were excluded.

**Results:** Twenty patients were included in the study, 70% (n=14) were males and the median age was 75 years (min 39 - max 84). It was found that 80% (n = 16) had been diagnosed in the last five years. Exposure to asbestos was reported in 45% (n=9) of the cases and in 40% (n = 8) had history of smoking. The most common symptoms were dyspnea (55%; n=11) and thoracalgia (45%; n=9); 15% (n=3) of the patients were asymptomatic.

The diagnosis was established mainly by video-assisted thoracic surgery (50%; n=10), followed by blind pleural biopsy (30%; n=6). The most frequent histological subtype was epithelioid mesothelioma, responsible for 80% (n=16) of the cases. The performance status was 0 or 1 in 60% (n=12) according to the classification of the Eastern Cooperative Oncology Group. Stage IV corresponded to 50% of cases, according to the International Mesothelioma Interest Group and 90% (n=18) of the patients were considered inoperable according to a multidisciplinary meeting. Treatment consisted of best supportive care in 50% (n=10) of the cases, followed by chemotherapy (CT) in 40% (n=8) and surgery (pleurectomy) preceded by neoadjuvant CT in 10% (n=2). Median survival was, respectively, 1.6, 11.4 and 17.8 months, with a median overall survival of 9.1 months. Regarding to patients treated with CT alone (n=8), first line of treatment included platinum plus pemetrexed (n=6), platinum plus gemcitabine (n=1) and vinorelbine (n=1). A median number of 4 cycles of treatment (3-6 cycles) was performed, obtaining: partial response (n=1), stable disease (n=3), disease progression (n=4), with median progression free survival of 4.9 months (range 2.1 - 10.1 months).

**Conclusions:** In this sample, the number of cases diagnosed in the last 5 years was higher than in the previous period, suggesting that the incidence of MPM may not have yet reached its peak in our country. The diagnosis was made at an advanced stage of the disease and half of the patients only underwent supportive therapy, with an overall survival inferior to which has been described in the literature (9.1 vs 12 months).

PE 012

### BRAF-V600E ADVANCED LUNG ADENOCARCINOMA DETECTED BY NEXT GENERATION SEQUENCING - A NEW THERAPEUTIC OPPORTUNITY

R Paupério, M Jacob, JL Costa, J Reis, H Queiroga, CS Moura, JC Machado, V Hespanhol, G Fernandes

Serviço de Pneumologia, Centro Hospitalar de São João, EPE, Porto

Key-words: BRAF-V600E mutation; Next generation sequencing

**Introduction:** BRAF mutations occur in around 3% of non-small cell lung cancers (NSCLC) and V600E accounts for 50%. Currently, the detection of BRAF-V600E mutation become clinically relevant as kinase inhibition with Vemurafenib or Dabrafenib + Trametinib demonstrated superiority over conventional chemotherapy. The authors describe 3 clinical cases with a BRAF-V600E mutation detected by NGS (Ion Torrent PGM technology), highlighting the respective therapeutic options.

**Case 1:** Male patient, 65 years old, non-smoker, with adenocarcinoma, TTF1 +, stage IV, with pleural effusion. The initial molecular study was negative for EGFR mutation and ALK- EML4 translocation. Four cycles of chemotherapy with Pemetrexed and Carboplatin were done, followed by maintenance with Pemetrexed for 5 cycles. 2<sup>nd</sup> line chemotherapy with Navelbine was initiated, with disease stability. A BRAF-V600E was detected in the initial tumor sample. Given the stability of the disease, no target molecular therapy has yet been initiated.

**Case 2:** Female patient, 58 years old, non-smoker, with adenocarcinoma TTF1 positive, without EGFR mutation or ALK-EML4 translocation, with multi-organ metastatic disease (bone, lung and thyroid). Four cycles of chemotherapy with Pemetrexed and Carboplatin were done. Afterwards, leptomeningeal disease was confirmed. A BRAF-V600E was detected in the initial tumor sample and in plasma circulating free DNA. An *off-label* treatment with Vemurafenib 960 mg q12hr was done, with partial response during 9 months. Overall survival was 12 months.

**Case 3:** Male patient, 58 years old, former smoker, (31 pack years), with adenocarcinoma TTF1 positive, ALK negative and EGFR negative, with metastatic disease (diffuse bone metastatic disease) and lung lymphangitis. Six cycles of chemotherapy with Pemetrexed and Carboplatin were done, with partial response, followed by maintenance chemotherapy with Pemetrexed. After 6 cycles, there was disease progression (cerebral and hepatic metastasis). A BRAF-V600E was detected in the initial tumor sample. Dual inhibition treatment was initiated with Dabrafenib 150 mg q12hr + Trametinib 2mg q24hr (*off-label*). A clear improvement in the overall condition and in the neurological clinic was achieved, with an objective response to therapy. The patient is in the third month of treatment.

**Discussion:** The authors highlight the necessity of using a multiplex screening strategy to detect targetable mutations in advanced lung cancer patients. The application of next generation sequencing to the tumour and/or plasma cfDNA allowed the detection of a BRAF-V600E mutation and treatment with target agents with high clinical efficacy, as Vemurafenib and dual inhibition with Dabrafenib and Trametinib.

PE 013

### **PULMONARY NODULES - FOLLOW-UP PROTOCOL: MAKES SENSE IN ALL PATIENTS?**

**JSJ Barata, R Silva, M Baptista, E Magalhães, I Vicente,  
MJ Valente, MS Valente**  
Centro Hospitalar Cova de Beira

Key-words: Nodules, lung, cancer, diagnosis

**Introduction:** Pulmonary nodules are defined as focal, round or oval areas in the lung parenchyma with a diameter of less than 30mm. They are frequently detected accidentally on chest radiography or computed tomography (CT), and although most are benign, sequential temporal surveillance is required.

**Objectives:** To characterize the population of patients with pulmonary nodule (s) and to evaluate the diagnostic profitability of the screening protocol proposed by the National Comprehensive Cancer Network (NCCN).

**Methods:** Retrospective analysis of demographic and clinical data a convenience sample of patients followed in consultation pneumology by single or multiple pulmonary nodules since its detection, evaluating its morpho-dimensional evolution.

**Results:** Including 44 patients, 72.7% males, with mean age 61.6 years (majority between 60 and 70 years). Of the total, 65.9% were smokers or former smokers, and 77.3 had occupational inhalation exposure at risk.

Regarding the comorbidities presented, 11.4% had chronic obstructive pulmonary disease (COPD) and 11.4% had previous history of extrapulmonary neoplasia.

In terms of classification, the majority (88.6%) had solid nodule characteristics, 56.8% had multiple nodules and 75% had no associated adenopathies in the first CT-chest performed.

As to morphology, 72.7% of the nodules presented benign characteristics, the majority (43.5%) of diameter less than 6 mm, 33.6% greater than 8 mm, of which 2 were above 15 mm.

The preferred location was the right lung (63.9%) and the upper lobe (27.8%).

After the first computed tomography scan, 15.9% of the patients had positron emission tomography - Fluorodeoxyglucose 18 (PET-CT-FDG18), with only 2 with discrete metabolic acceptance. After the first CT-thorax control, 88.6% of the nodules maintained the stability of their characteristics and 12 of follow-up ceased. Of the patients submitted to the second thorax of the control CT, 81.3% of the nodules remained stable, 13 ceased follow-up and only 1 presented growth, continuing the evaluation with transthoracic lung biopsy.

Of the 19 patients who remained on follow-up, 89.5% of the nodules remained stable and the remainder reduced their size. On average, each patient performed 3.7 TC and maintained an average follow-up of 22.6 months.

**Conclusions:** We conclude that, in our sample, the majority of patients are male, have exposure to tobacco and / or other inhaled risk factors and have millimetric nodules. Most patients maintained morpho-dimensional stability in the evaluation of the series, so the diagnostic profitability of this approach is questioned considering the benefit / risk of radiation exposure, since the national availability of low computed tomography is reduced. Of no less important, it adds unnecessary anxiety inculcated to users.

PE 014

### **MUCOEPIDERMOID CARCINOMA OF THE LUNG: A RARE ENTITY - CLINICAL CASE**

**E Brysch, C Antunes, R Macedo, I Correia, C Bárbara**  
Serviço de Pneumologia, Centro Hospitalar Lisboa Norte

Key-words: lung cancer, mucoepidermoide carcinoma of the lung, salivary glands tumour, respiratory infection

Mucoepidermoid carcinoma of the lung is a tumour of the salivary glands that originates from the submucosal glands of the tracheobronchial tree. It is an extremely rare tumour, accounting for 0.1 to 0.2% of all primary lung tumours.

The authors describe a case of a 51-year-old black female, non-smoker, with no prior significant diseases. The patient went to the Emergency Department with dyspnoea and cough with mucopurulent expectoration with 7 days of evolution, after a long course plane trip. At baseline examination the patient was febrile, with peripheral oxygen desaturation (91% in ambient air) and decreased vesicular murmur in the right base for pulmonary field. The laboratorial analysis showed an increased C Reactive Protein and negative d-dimers. Arterial blood gas showed hypoxemia with hypocapnia without alterations in the acid-base balance. Chest x-ray showed no significant changes. The hypothesis of tracheobronchial infection was assumed maintaining however the suspicion of pulmonary embolism (PE), despite the presence of negative d-dimers. Empirical antibiotic therapy and anticoagulation at therapeutic doses was initiated. Blood cultures were negatives but serotypes of atypical agents were positive for *Chlamydia pneumoniae*. Also, in the sputum bacteriological examination *Staphylococcus Aureus Methicillin-Resistant* was isolated. Antibiotic therapy was adjusted according to the Antibiotic Sensibility Tests. A Computed Tomography (CT) with contrast was performed and revealed a nodular lesion with luminal occlusive component of the Right Main Bronchus (RMB) conditioning a valvular phenomenon. There were no signs attributable to PE or right ventricular overload findings, no pulmonary artery trunk dilation suggesting pulmonary hypertension along with pulmonary artery calibre asymmetry at the expense of the hyperinflated right lung. During a rigid bronchoscopy a total occlusion of the right bronchial tree by a rounded and vascularized mass in RMB was observed. Laserization and resection of the mass with prosthesis placement in RMB was performed. Histopathology was compatible with mucoepidermoid carcinoma with an intermediate malignancy degree. After stabilization of the clinical condition, the patient was discharged from the hospital, referred to Oncology for guidance and therapeutic strategy decision.

Mucoepidermoid carcinoma of the lung is a rare neoplasm, which occurs mainly in young patients. It usually presents as a central endobronchial polypoid lesion, which can cause obstructive airway symptoms and recurrent respiratory infections or obstructive pneumonia.





PE 015

## ATYPICAL METASTASIS OF LUNG CANCER - CASE REPORT

J Barbosa, TS Santos, AL Martins, L Carvalho  
Centro Hospitalar Lisboa Norte

Key-words: Lung neoplasms; Subcutaneous nodules; TTF1

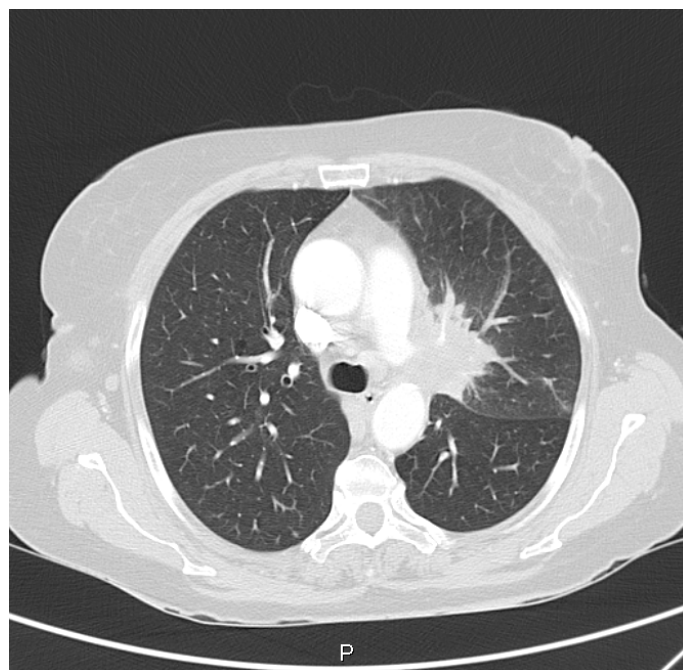
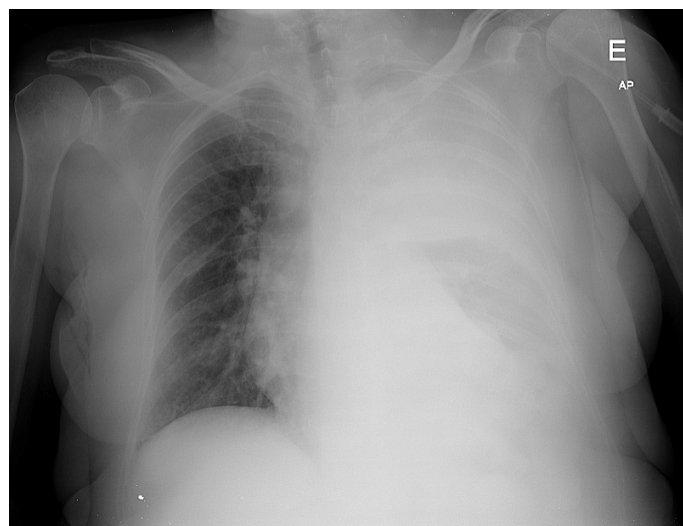
Lung neoplasms are one of the leading causes of death world-wide. They are classified in non-small cells lung carcinoma and small cells (about 15%). The former can be divided in three histologic types: squamous cells, adenocarcinoma and large cells. They are all associated with previous smoking history, namely small cells and squamous cells carcinoma. Adenocarcinoma, on the other hand, is more common in non-smoking patients. Lung neoplasms can virtually metastasize to all organs, but the most frequent locations are liver, adrenal glands, bone, brain and hilar nodules.

Although rare, with an incidence of 1-12%, skin metastasis can occur as the initial presentation of lung neoplasms, namely adenocarcinoma. These kind of metastasis have a poor prognosis when accompanied by other metastasis, reducing the overall survival by three months.

Renal and colorectal neoplasms too can metastasize to the skin either above or below the diaphragm. The organ of metastasis is believed to be under genetic influence.

The recommended treatment regimens include surgery plus chemo or radiotherapy. Generally, skin lesions are nodular, soft or hard, fixed or flexible, and there can be one or more, usually painless. Histologically, they have poor differentiation which means that TTF and CK/20 can be useful to identify this kind of tumors. We present the case of a 61-year-old caucasian woman, with history of cigarette smoking, admitted with obstructive jaundice. The patient had a history of low back pain, weight loss, painful subcutaneous nodules and normocytic normochromic anemia for three months. We performed a biopsy of one of the subcutaneous nodules which was suggestive of a primitive tumor of the pancreas or ovary, but unable to exclude lung tumor. The etiological study showed a primitive lesion of the central / parahilar left lung with multiple metastasis. No adnexal mass was documented. Bronchofibroscopy revealed the presence of an "infiltrated appearance of the left main bronchus, mainly at the left upper lobe", and the pulmonary biopsy was that of a non-small cell carcinoma, with little differentiation, with an immunohistochemical study of a TTF1 negative adenocarcinoma. During hospitalization, there was a progressive worsening of the clinical status, with partial respiratory insufficiency associated with tumor growth and subsequent evidence of complete occlusion of the left main bronchus.

We herein report an atypical case of skin metastasis in a patients with lung adenocarcinoma (TTF1 negative) with a rapid and fatal evolution.





PE 016

### **ATYPICAL PRESENTATION OF LUNG CANCER - CLINICAL CASE**

**S Lucas\*, C Gaspar\*\*, T Almodovar\*\*, JD Costa\*\***

\* Hospital de Faro - Centro Hospitalar do Algarve; \*\*Instituto Português de Oncologia Francisco Gentil de Lisboa

Key-words: Lung Cancer; Subcutaneous metastasis;

Lung cancer is the main cause of death due to cancer worldwide, with more than 50% of cases presenting metastatic lesions at the time of diagnosis. The initial presentation through symptomatology triggered by metastatic lesions is not uncommon and the sites most frequently described in literature are central nervous system and bone.

The authors describe a clinical case of lung cancer with right forearm subcutaneous tissues metastasis presentation.

The case is about a male individual, smoker of 50 pack units / year, with no personal antecedents. In 2017 June was referred to our hospital Surgery appointment due to suspected sarcoma. The patient had a mass on the right forearm with two months evolution with pain. He also reported anorexia, unquantified weight loss, asthenia, and tiredness for medium efforts. The patient presented mass in anterior, superior and external slopes of the right forearm, with stony consistency, adherent to the superficial and deep planes with about 8 cm of greater axis. A CT scan of the limb revealed adjacent muscles invasion and probable radius invasion. He performed a biopsy of limb mass whose histology showed a p40 positive cell carcinoma (CPC), desmin and actin negative. On suspicion of metastatic lesion the patient was referred to Dermatology Group Consultation and was requested a Thorax CT. In Group Consultation the CT Thorax showed a massive left hilar lesion with superior lobar bronchus invasion with atelectasis of this lobe and compromise of the left pulmonary artery, multiple mediastinal adenopathies and secondary deposits in the contralateral lung by which it was referenced for Pulmonary consultation as suspicion of metastatic lesion from pulmonary origin. He underwent bronchofibroscope (BF) that shows total occlusion of the left upper lobar bronchus with polyploid mass and signs of infiltration at the level of the inferior lobar mucosa. Bronchial biopsies confirmed pulmonary CPC (p40 positive and TTF1 negative). Clinical worsening with fever after BF led to hospitalization with a obstructive pneumonia diagnosis. The patient presented clinical improvement after antibiotic therapy. Performance status Eastern Cooperative Oncology Group (ECOG) was 1.

He performed palliative radiotherapy on limb metastasis (20 grays in 5 fractions). In group thoracic tumours consultation, CPC of the left upper lobe on stage IV (bone metastasis, soft tissues, lung and supra renal) was admitted and pembrolizumab (PD-L1 expression 80%) was proposed. The patient died before starting treatment.

The authors describe this case by the rarity of clinical presentation of lung cancer through subcutaneous metastasis. Rare cases are described in literature, being the most common sites the thoracic wall, dorsum and abdomen. This form of presentation may lead to delayed diagnosis and consequently delay of appropriate therapy. The prognosis of these patients is usually quite reserved.

PE 017

### **MEDIASTINAL MASS IN A YOUNG ADULT**

**AL Fernandes<sup>1</sup>, I Cruz<sup>2</sup>, J Ferreira<sup>1</sup>, AP Vaz<sup>1</sup>**

<sup>1</sup> - Pulmonology Departement, Unidade Local de Saúde de Matosinhos; <sup>2</sup> - Internal Medicine Departement, Unidade Local de Saúde de Matosinhos

Key-words: mediastinal mass, seminoma

**Introduction:** The extragonadal germ cell tumors are infrequent neoplasms that typically occur in young adults and are located in the midline. It accounts for 15% of all anterior mediastinal masses in adults.

**Case report:** Male, 25 years-old, student, with a history of allergic asthma and rhinitis, smoker (2 pack-year) and with occasional use of hashish. Without any relevant family history.

The patient was admitted to the Emergency Department due to a 3-month history of dry cough, left pleuritic pain and weigh loss. The physical examination did not present any significant change. Laboratory tests were within the normal ranges. The chest radiography showed a left paracardiac opacification. Additionally, the cervico-thoracic computerized tomography (CT) showed a 8,70x7,6cm heterogeneous, mainly solid mass, located in the anterior mediastinum. The tumor seemed to adhere to the heart border and had a compressive effect on the pulmonary artery. Enlarged cervical lymph nodes were identified, the largest with 13x40mm, with enhancement after intravenous contrast. Transthoracic lung biopsy was performed which demonstrated the presence of malignant cells with positivity for PLAP and CD117, but negative for AE1/AE3 and LCA, suggesting the diagnosis of extragonadal germ cell tumor, compatible with seminoma.

$\beta$ -human chorionic gonadotropin ( $\beta$ -HCG) level was elevated (9.1 mUI/mL), serum  $\alpha$ -fetoprotein level was normal (1.071 UI/mL) and lactate dehydrogenase (LDH) was slightly augmented (282 U/L). The bilateral testicular ultrasound was normal. For staging purposes, abdominopelvic CT was performed and did not reveal any significant change. The diagnosis of mediastinal seminoma stage IIIB, intermediate risk, was assumed. The patient then started chemotherapy (bleomycin, etoposide and cisplatin regimen). After 4 cycles, the laboratorial study showed normalization of the  $\beta$ -HCG level, the tumor decreased in size on the thoracic CT and no FDG uptake was evident on <sup>18</sup>F-FDG-PET. After 3 months, the patient had no evidence of tumor recurrence and was referred for regular follow-up.

**Conclusion:** Although around 60-70% of mediastinal seminomas are diagnosed in advanced stages, a good response to chemotherapy is usually observed and the 5-year survival rate is about 90%.





PE 018

### REPORT ON TWO CASES OF ADENOCARCINOMA OF THE LUNG STAGE IV: SIMILAR IN APPROACH, DIFFERENT IN OUTCOME

I Moreira<sup>a</sup>, S Alfarroba<sup>a</sup>, P Winkler<sup>b</sup>, AS Santos<sup>a</sup>, MA Cardoso<sup>c</sup>, A Magalhães<sup>a</sup>, J Cardoso<sup>a</sup>

<sup>a</sup> Serviço de Pneumologia do Centro Hospitalar Lisboa Central (CHLC), Hospital de Santa Marta / Faculdade de Ciências Médicas da Universidade Nova de Lisboa; <sup>b</sup> Serviço de Oncologia Médica do Centro Hospitalar Lisboa Central (CHLC), Hospital de Santo António dos Capuchos; <sup>c</sup> Serviço de Medicina Paliativa do Centro Hospitalar Lisboa Central (CHLC), Hospital de Santo António dos Capuchos

Key-words: Adenocarcinoma of the lung; Imunosuppression; Pneumocystosis; Aspergilosis

**Introduction:** Adenocarcinoma of the lung is the most frequent form of lung cancer and complications depend on the state of immunosuppression of the patient, being that infections are the most common.

**Clinical case:** We report cases of two previously healthy caucasian male patients, with 50 years of age, previous smoking habits, who were diagnosed with adenocarcinoma of the lung in the last year. Both resorted to the emergency department due to inaugural neurological deficits, which resulted in the identification of brain metastasis in CT, from an unknown primary tumor. The subsequent diagnostic workup resulted in the identification of pulmonary solitary nodules in the superior lung lobes, whose histological evaluation (by bronchofibroscopy and transthoracic aspiration biopsy respectively) revealed adenocarcinoma of the lung, in stage IV due to brain metastasis with no other signs of disease in distant sites. Both had no indication for surgical intervention of the cerebral metastases and underwent corticotherapy with dexamethasone and holocranial radiotherapy. Both patients subsequently developed extensive hypoxemic bilateral pneumonia with standard imaging suggestive of Pneumocystis pneumonia, likely in the context of immunosuppression.

In the first patient, the presumptive diagnosis was possible from imaging, and the patient began empirical antibiotherapy. Despite the good clinical and imagiologic improvement, rapid progression of the pulmonary and adrenal tumour sites led the patient to worsen rapidly and he eventually died at home waiting for integration into a palliative care unit.

In the second patient, the thoracic CT revealed signs compatible with Pneumocystis pneumonia, plus a possibly inhabited left upper lobe cavitation. The patient underwent bronchofibroscopy with isolation of Pneumocystis jirovecii and Aspergillus. He then started antibiotherapy and voriconazole, plus corticosteroid therapy, with clinical, analytical and imagiologic improvement. The tumor mutational study only revealed a positive Kras mutation and the patient underwent systemic therapy with cisplatin/pemetrexed. Until this date, the patient fulfilled 6 cycles of chemotherapy with good response and control of the disease, no new outbreaks of tumour sites, awaiting the beginning of stereotactic radiation of the pulmonary injury.

**Conclusion:** This report compares two clinical cases of infectious diseases in immunosuppressed patients due to oncologic status whose initial presentation, treatment and complications were similar, but with distinct outcomes.

PE 019

### COLLISION TUMOR OF THE LUNG

C Matos<sup>1</sup>, M Felizardo<sup>1</sup>, A Catarino<sup>3</sup>, F Martelo<sup>4</sup>, JP Coelho<sup>2</sup>, ST Furtado<sup>1</sup>

<sup>1</sup>Serviço de Pneumologia do Hospital Beatriz Ângelo e Hospital da Luz, <sup>2</sup>Serviço de Oncologia Médica do Hospital da Luz e Hospital Beatriz Ângelo, <sup>3</sup>Serviço de Anatomia Patológica do Hospital da Luz, <sup>4</sup>Serviço de Cirurgia Torácica do Hospital da Luz

Key-words: neoplasm, lung, prostate

**Introduction:** Collision tumours are defined by the presence of two tumours of different histological origin in the same organ. These tumors are extremely rare and their diagnosis constitutes a challenge.

**Case Report:** A 70-year-old man, non-smoker, presented with a cardiac tamponade and was submitted to an emergency pericardiocentesis, with aspiration of 600 cc of hematic fluid. The cytologic exam showed adenocarcinoma cells (PSA-, CK7+, TTF1+, CK20-) of probable pulmonary origin.

The patient had a prior diagnosis (9 years before) of prostate adenocarcinoma with bone metastasis in the ischium and sacrum and underwent radiosurgery and complete androgen block.

A thoracoabdominal CT scan was performed with bilateral pleural effusion, enlarged mediastinal and hilar lymph nodes, multiple nodules in the left upper lobe and atelectasis of the left lower lobe. The PET-CT revealed local recurrence of the prostatic cancer with probable invasion of the bladder wall, multiple bone lesions, bilateral pleural effusion and hilar, mediastinal and supraclavicular lymphadenopathies.

The patient was submitted to left hemithorax video-assisted thoracoscopic surgery (diagnostic and therapeutic), with atypical resection of the upper left lobe and ganglionic biopsies (groups 5 and 7). A chronic indwelling pleural catheter was placed.

The macroscopic exam showed 4 pulmonary nodules in the surgical specimen; the histologic exam of the nodules revealed 2 malignant epithelial populations: 1 consisting of solid aggregates of epithelial cells with vast eosinophilic cytoplasm, with occasional morular configuration (TTF1+, CK7+, CK34Be12+, CK20-, PSA-) and another consisting of epithelial proliferation of acinar and cribriform pattern (PSA+, TTF1- and CK7-, CK20-, CK34Be12-), in favor of adenocarcinoma of the lung with solid and acinar pattern and pulmonary metastases of acinar prostate adenocarcinoma. The ganglionic biopsies showed metastasis of pulmonary and prostatic cancers.

Chemotherapy with platinum and pemetrexed was given, with partial response. After 6 cycles maintenance treatment was started. The patient maintained usual treatment with goserelin; the serum PSA remained stable.

The patient died 14 months after diagnosis of an infectious complication.

**Conclusion:** Collision tumours are extremely rare; there are no statistics or specific treatment reported. Histopathology has a key role in its diagnosis.



PE 020

### MENTAL CONFUSION AS A FIRST SIGN OF LUNG CANCER - CLINICAL CASE

JD Cardoso, C Martins, C Bárbara

Serviço de Pneumologia, Centro Hospitalar Lisboa Norte

Key-words: Lung Cancer, Hypercalcemia, Paraneoplastic syndrome

**Introduction:** Hypercalcemia can result of too much calcium entering the extracellular fluid or insufficient renal excretion. It is the most common paraneoplastic syndrome, and it is commonly observed in patients with pulmonary cancer, especially non-small cell lung cancer.

The severity of the symptoms depends not only from the level of calcium, but also on the rate of increase of serum calcium. Hypercalcemia affects all organ systems, but especially the central nervous system (CNS) causing fatigue, lethargy, mental confusion and coma (if calcium is above 14 mg / dL); and the renal system causing polyuria, dehydration and renal failure.

The mechanisms involved in hypercalcemia in patients with lung cancer are the production of parathyroid hormone - related peptide (PTHrP), increase of active metabolite of vitamin D and metastatic osteolytic lesions.

Measurements of levels of parathyroid hormone (PTH), PTHrP, calcitriol, vitamin D, calcium, albumin, magnesium and phosphorus, as well as bone imaging are part of the diagnostic evaluation.

**Case:** We describe a case of an 80-year-old woman admitted to the emergency room due to lethargy and mental confusion. She presented a Glasgow scale index of 10, isoreactive pupils, absence of deficits, reduction of the vesicular murmur in the lower half of the right hemithorax.

Analytically presenting a calcium of 16.1mg/dL, PCR 0.12mg/dL, Creatinine of 1.07mg/dL. Normal serum levels of PTH, PTHrP, vitamin D, calcitriol, phosphorus and magnesium.

In the chest x-ray, there was heterogeneous hypotransparency in the lower right half.

She underwent cranioencephalic computed tomography (CT) scan showing multiple lithic infiltrative nodular lesions in the skull and skull base with rupture of the internal and external cortical suggesting metastasis, showing an endophilic lesion in the left frontal region. She performed a thorax and abdominal CT scan, observing a solid mass of 6x2.8 cm conditioning destruction of the 3rd posterior costal arch and adjacent vertebral body; destructive lesion in sacrum and lytic lesion in the vertebral body of L2; right supraclavicular adenopathies with dimensions between 1.3 and 1.6 cm, adenopathic mass with 4.3 cm adjacent to the aortic cross, adenopathic conglomerate in the retro-cavus pretracheal space invading the right pulmonary hilum and left adrenal nodule with 1.2 cm. She was submitted to bronchofibrosocopy with bronchial biopsies in which was possible to identify lung adenocarcinoma.

**Conclusion:** Hypercalcemia is a common paraneoplastic syndrome in lung cancer. However, the authors emphasize that values above 14mg/dL are less frequent and are associated with neurologic symptoms and signs and poor prognosis and 1 to 3 months survival rates.

PE 021

### COMPLICATION OF INTRAVESICAL CALMETTE-GUERIN BACILLUS IMMUNOTHERAPY - CLINICAL CASE

JD Cardoso, AT Castro, T Mourato, MC Gomes

Serviço de Pneumologia do Centro Hospitalar Lisboa Norte; Centro de Diagnóstico Pneumológico Dr. Ribeiro Sanches

Key-words: Bacillus from Calmette-Guerin, Immunotherapy, Cystitis

**Introduction:** Intravesical administration of Bacillus from Calmette-Guerin (BCG), an attenuated form of *Mycobacterium bovis*, is usual treatment for superficial bladder cancer. Immunotherapy with BCG is generally well tolerated however infectious complications may arise.

The immunologic mechanism is not fully understood but appears that BCG leads to the development of a Helper T cell cytokine profile. This response potentially leads to alteration of suppressor / helper T cell ratios and consequently predisposition to infectious complications.

The most common complication is cystitis but systemic complications such as sepsis, hepatitis and osteomyelitis may occur.

**Clinical case:** We describe the case of a 67-year-old male with the diagnosis of multifocal non-invasive high-grade bladder endothe-lial carcinoma since June 2015, submitted to vesicular trans-urethral resection and intravesical mitomycin C treatment.

In December 2016 disease recurrence occurred in multiple sites, the patient was proposed for a new trans-urethral vesical resection and intravesical BCG immunotherapy in February 2017.

In March 2017, he began to suffer from dysuria, urinary incontinence, and hypogastric pain with progressive worsening of complaints over 2 months. During this period he performed several urine cultures that were persistently negative, performing numerous cycles of antibiotic therapy, including quinolones. During this time the analytical inflammatory parameters remained negative and prostate specific antigen (PSA) values remained normal.

In June 2017, molecular detection of *Mycobacterium* is carried out, being positive with subsequent positive cultural exam for *Mycobacterium tuberculosis* complex.

The diagnosis of BCG cystitis was admitted and the patient started isoniazid and short period of systemic corticosteroid therapy with rapid improvement.

**Conclusion:** Intravesical BCG immunotherapy is an established treatment and an effective alternative to usual chemotherapy regimens for the treatment of superficial bladder cancer.

BCG cystitis is the most common complication and it may be difficult to differentiate from cystitis caused by other microbiological agents. Treatment with quinolones may be enough but in refractory cases the use of isoniazid associated with short cycle of corticosteroid therapy is necessary.





PE 022

### **PULMONARY CARCINOSARCOMA - DIAGNOSTIC APPROACH OF THREE CASES**

**M Fernandes, V Pereira, T Abreu, A Ribeiro, P Barradas, R Sotto-Mayor, C Bárbara**

Centro Hospitalar Lisboa Norte

Key-words: pulmonary carcinosarcoma, lung cancer

**Introduction:** Pulmonary carcinosarcoma is a rare lung neoplasm (<1%), histologically characterized by the presence of carcinoma cells (squamous cell or adenocarcinoma) and a sarcomatous component (rhabdomyosarcoma, osteosarcoma, or chondrosarcoma). It usually occurs in smokers between 50 and 70 years. The most frequent initial radiological finding is a pulmonary nodule, which can be central or peripheral, and the diagnostic approach (endoscopic versus surgical) depends on its location.

**Objective:** To characterize the clinical, radiological and histopathological presentation at the time of diagnosis of carcinosarcoma.

**Methods:** We retrospectively studied the clinical records of three patients diagnosed with carcinosarcoma admitted to the Pulmonary Oncology Unit of Hospital Pulido Valente between August and December of 2016.

**Results:** Three patients were included, two male and one female, with a mean age of 64 years, of whom 2 were smokers. Two patients underwent clinical investigation because they presented symptoms, such as asthenia, non-productive cough, dyspnea and thoracalgia, with a mean duration of 1.5 months. One patient was asymptomatic and initiated investigation after accidental radiological findings. In the chest computed tomography, 2 patients had a lesion in the left and right upper lobes, with a central location and 11 and 3 cm of diameter, respectively. One patient had a lesion with 15 mm of diameter located in the subpleural region of the right lower lobe. Two patients underwent bronchofibroscopy with evidence of bronchial wall infiltration. Bronchial biopsies were performed, with histological confirmation of primary lung neoplasm. The patient with the nodule located in the subpleural region was diagnosed by transthoracic biopsy. On the anatomicopathological examination, all fragments showed neoplastic infiltration by carcinoma cells with cytokeratine positivity, as well as cells marked for mesenchymal markers. Of these, 2 were marked with vimentin and 1 with desmin and myogenin (subpleural nodule). At the time of diagnosis, 2 patients were in stage IVa and 1 in stage IIB, according to the TMN classification (8th edition) of International Association for the Study of Lung Cancer.

**Conclusions:** Pulmonary carcinosarcoma is a rare lung neoplasm and its initial clinical presentation and diagnostic approach depends on the location of the primary lesion. The diagnosis is histological with evidence of carcinoma cells, usually non-small cells, and cells with positivity for sarcoma markers. Due to its heterogeneity, the suspicion of carcinosarcoma is imagiologically impossible and even after performing biopsies, a full immunohistochemical study is essential to confirm the diagnosis.

PE 023

### **PLEURAL MESOTHELIOMA: NEVER SAY NEVER**

**C Antunes<sup>1</sup>, V Durão<sup>1</sup>, T Calado<sup>2</sup>, D Hasmucrai<sup>3</sup>, L Mota<sup>4</sup>, F Paula<sup>5</sup>, R Sotto-Mayor<sup>3</sup>, J Semedo<sup>4</sup>, F Froes<sup>5</sup>, F Félix<sup>2</sup>**

<sup>1</sup>Serviço de Pneumologia do Centro Hospitalar Lisboa Norte, <sup>2</sup>Serviço de Cirurgia Torácica do Hospital Pulido Valente do Centro Hospitalar Lisboa Norte; <sup>3</sup>Serviço de Oncologia Pneumológica do Hospital Pulido Valente do Centro Hospitalar Lisboa Norte; <sup>4</sup>Unidade de Pneumologia de Intervenção do Hospital Pulido Valente do Centro Hospitalar Lisboa Norte; <sup>5</sup>Unidade de Cuidados Intensivos Médico Cirúrgicos Respiratórios do Hospital Pulido Valente do Centro Hospitalar Lisboa Norte

Key-words: mesothelioma, surgical approach, opportunistic infection

The malignant pleural mesothelioma is a rare and insidious condition that arises from the mesothelial cells of the pleural cavity. Its prognosis is poor given its late presentation and its treatment defying, involving a multimodal strategy.

The authors submit the clinical case of a 71 year old non-smoker female patient with no known exposure to asbestos and with a personal history of scleronodular Hodgkin Lymphoma stage IIIA in complete remission since 2001, arterial hypertension, uterine myoma and complete right hip prosthesis. In 2016 is admitted to the hospital due to unilateral pleural effusion which investigation through medical thoracoscopy concludes epithelioid malignant pleural mesothelioma. The patient is referred to the Oncology Pneumology consultation in June 2016. The thoracic computed tomography reveals massive chest pleural effusion with irregular thickening of the parietal pleura and left fissure and multiple solid nodules of the mediastinal and costal pleura, with increased uptake in the Positron Emission Tomography (PET) scan, compatible with stage III disease. After multidisciplinary decision, the patient undergoes six cycles of chemotherapy with cisplatin and pemetrexed, with significant reduction of the tumor burden in the pleural seat. Given the favorable response to chemotherapy and the limited cardiopulmonary reserve (ergometry with a maximum O<sub>2</sub> consumption of 14mL/kg/min) the patient is proposed for pleurectomy/decortication with diaphragm removal. The pathological exam of the surgical specimen reveals surgical margin infiltrated by neoplasia with invasion of the lung parenchyma and soft tissues of the mediastinum, compatible with the postoperative pathological stage III.

In the postoperative the patient develops hemorrhagic shock requiring aminergic and transfusional support and invasive mechanical ventilation, as well as broad spectrum antibiotic therapy due to refractory shock. The difficulty in the ventilation weaning and extubation process, due to ineffective cough and abundant purulent bronchial secretions, determines the performance of semi-rigid bronchoscopy at D7, which reveals extensive whitish plaques scattered throughout the bronchial tree, suggestive of fungal infection. Admitting the diagnosis of invasive bronchopulmonary aspergillosis in an immunocompromised patient, voriconazole and caspofungin are initiated on the same day, with clinical, analytical and endoscopic improvement allowing safe extubation.

This clinical case demonstrates the complexity of the pathology associated with the malignant pleural mesothelioma. This entity may be associated with haematological malignancies submitted to radiotherapy. However, in the presented case the patient had only undergone chemotherapy for the treatment of Hodgkin's Lymphoma. The late presentation of the disease would determine

the adoption of cytoreductive procedures with chemotherapy. The favorable response with significant reduction of the tumor burden allowed the surgical approach in order to promote improved quality of life and reduction of symptoms. However, the treatment of this entity may be associated to a series of complications, and the authors highlight in the presented case the development of fungal infection, only endoscopically identified, that would favorably respond to early and aggressive treatment.

PE 024

#### LTIPLE LUNG CANCER - CASE REPORT

**D Coelho, A Szantho, T Almodovar, D Costa**

Serviço de Pneumologia. Centro Hospitalar Nossa Senhora do Rosário.  
Centro Hospitalar Barreiro Montijo, E.P.E

Key-words: Primitive Tumor; Multiple Tumor; Lobectomy; Recidive

**Introduction:** Lung cancer occurs in an increasing number of cases with two (or more) malignant lung lesions. In these cases ambiguity is generated in its staging and the difficulty in the interpretation of its classification. More importantly, it is not clear how to think conceptually about the nature of these injuries and how to manage these patients.

**Case Report:** We present case report of women 53 years old with history of smoking 35 pack-year without any professional exposition. In 2012, in the context of investigation of headache, dizziness and imbalance, the patient underwent chest computed tomography which showed nodule with 16mm in the left lower lobe and another 7mm nodule in the right lower lobe. CT- guided percutaneous fine-needle aspiration of left lower lobe biopsies was performed and show histologic diagnostic of lung Adenocarcinoma (TTF1+) cT1N0M0.

The patient was purpose to lobectomy with mediastinal lymphadenectomy. The pathological diagnosis was Adenocarcinoma poorly differentiated (pT1aN0M0).

On chest computed tomography follow-up in 2013 and 2014 show disappearance of nodular shadow in right lower lobe and the appearance of ground glass opacity on the right upper lobe and middle lobe without pathologic lymph nodes.

Chest computed tomography in September 2015 showed stability of ground glass image, appearance of multiple infra-centimetric nodules with higher expression in the upper and middle lobes, low subpleural density in right lower lobe and dimensional increase of lymph nodes of 4R and 4L. The Broncofibroscopy was performed and showed bronchial tumpt without recidive and linear endobronchial ultrasound-guided transbronchial needle aspiration (EBUS) at lymph node station 4R and 4L show heterogeneous cell population.

January 2016 chest computed tomography show disappearance of micronodular pattern but dimensional increase of ground glass opacity on right upper lobe and dimensional increase of subpleural density, micronodule 6mm on right lower lobe and 10mm on middle lobe, right hilar adenopathy.

In May 2016 the positron emission tomography (PET) show metabolic activity in ground glass opacity on right upper lobe with SUV 1.5, subpleural nodule SUV 3.9 and right hilar adenopathy SUV 4.1.

In July 2016 the surgery was performed with sleeve resection of antero-basal segment of right lower lobe with histologic result of big cells neuroendocrine pulmonary carcinoma (pT1aN0,RO) and wedge resection of upper right lobe show Adenocarcinoma invasive (pT1aN0, RO). Two syncrone tumors were admitted and the patient underwent QT adjuvant with carboplatin and etoposide 3 cycle.

In November 2016 chest computed tomography (CT) show dimensional increase of right lower lobe nodule. In January 2016 PET scan show metabolic activity in this nodule. In March 2017 the patient underwent right lower wedge resection. Postoperative pathological examination revealed lung Adenocarcinoma with acinar and lepidic pattern ypTxNxM1a (?) (AJCC 8th edition)

**Conclusion:** This case clearly illustrates the difficulties in the management of patients with multiple synchronous or metachronous pulmonary tumors and the differential diagnosis between second primary and metastization.





PE 025

**INFECTED LUNG NEOPLASM - WHEN PET IS NOT ENOUGH!**

**T Calado, M Alvoeiro, D Cabral, M Antunes, F Félix**

Serviço de Cirurgia Torácica do Hospital Pulido Valente, CHLN

Key-words: mediastinal staging, PET-CT, surgery

**Introduction:** Ganglionic staging is one of the most important factors of prognosis and its essential for the therapeutic decision. PET CT is currently a fundamental tool in the staging of lung tumours, presenting a sensitivity and specificity for nodal disease of 70.4% and 94.5%, respectively.

However, in patients with associated infectious pathology, the risk of false positives in the metabolic assessment of ganglionic disease (cN) may be increased and pathological staging should be considered.

We present two clinical cases of patients undergoing surgery to control infectious outbreak in the context of lung neoplasm, whose surgical staging did not confirm the clinical staging that initially defined the therapeutic attitude.

**Case 1:** A 50-year-old female smoker (30pack-year) with a personal history of total thyroidectomy by thyroid microcarcinoma at 44 years. In 01/2017, she starts complaints of productive cough and fatigue for medium efforts. After an etiological investigation, the diagnosis of right upper lobe epidermoid carcinoma in stage IIIB - cT4N2 - hypermetabolic mass of RUL with invasion of the mediastinum and homolateral hilar and mediastinal involvement is presented. Hospitalized in 03/2017 due to fever and dyspnea, presenting in thoracic CT a large abscess/necrotic RUL lesion. Considering the impossibility of performing neoadjuvant chemotherapy due to maintenance of the infectious condition, the patient underwent extrapleural upper bilobectomy with mediastinal lymph node dissection, without complications and with good clinical evolution. Histological analysis revealed to be an extensively necrotic squamous cell carcinoma of the lung - pT4NO (IIIA).

**Case 2:** A 55 year old male smoker (65pack-year) with a personal history of COPD. In 05/2016, he starts complaining of tiredness and present a hypotransparency in the left base on chest radiography. The remaining etiological investigation revealed a heterogeneous and hypermetabolic mass of 9 cm (SUV 35 - 49) in left lower lobe with ipsilateral mediastinal and hilar, right paratracheal and subcarinal lymph nodes hypermetabolic (SUV > 5). Bronchoalveolar lavage in bronchobioscopy suspected of squamous cell carcinoma. Staged in IIIB - cT3N3M0 and submitted to first-line chemotherapy (Gemcitabine + Cisplatin), to which it presented weak response with overlapping lesion and mediastinal nodes with hypercapture of FDG. Considered a surgical approach due to poor response and superinfection, having undergone left inferior lobectomy with mediastinal ganglionic dissection and mediastinoscopy, without complications and with good clinical evolution. Histological analysis revealed to be an inflammatory myofibroblastic tumor - pT4NO (IIIA).

**Conclusion:** The two clinical cases presented illustrate the importance of histological confirmation of mediastinal pathology with surgical biopsy in patients with cN2 and cN3. The presence of superinfection of tumor lesions can itself lead to lymph nodes enlargement and the diagnosis of false positives in PET-CT. Thus, in the presence of any necrotic and / or abscess lung neoplasm, a multidisciplinary discussion is mandatory and considered the performance of surgical mediastinal staging, under the risk of over-staging and making it impossible of primary surgical therapy.

PE 026

**AN UNUSUAL METHOD TO DIAGNOSE MESOTHELIOMA - A CASE REPORT**

**M Fernandes, A Pais, N Pinto, A Ribeiro, I Claro, T Abreu, A Oliveira, A Coutinho, L Mota, J Semedo, L Carvalho, C Bárbara**  
Centro Hospitalar Lisboa Norte

Keywords: mesothelioma, transbronchial cryobiopsy

**Introduction:** Pleural mesothelioma is a rare neoplasm that arises from the mesothelial cells of the pleural cavity. It is more common in males and strongly associated with asbestos exposure. Diagnosis is usually by pleural biopsy and treatment depends on the stage of the disease.

**Clinical case:** Male patient, 62 years old, caucasian, worker at an isolation factory (contact with asbestos) for 45 years, ex-smoker (15 pack-year), with type 2 diabetes mellitus, submitted to thyroidectomy due to nodular pathology and prostatectomy due to benign prostatic hyperplasia, treated with vildagliptin/ metformin and levothyroxine. The patient went to the emergency department with dyspnea on exertion, productive cough with mucopurulent sputum, pleuritic chest pain and weight loss, with 3 months of evolution. At the physical examination, the patient had polypnea, 93% oxygen saturation in room air and lung auscultation with diminished breath sounds at the left base and bibasilar crepitant crackles. Laboratory tests showed elevated c-reactive protein (11,2 mg/dL) and arterial blood gas analysis on room air with partial respiratory failure. A radiograph of the chest showed hypotransparency of the lower two thirds of the left lung with air bronchogram and diffuse accentuation of the right peribronchovascular reticulum. In this context, he was admitted to the Pulmonology Department of the Hospital Pulido Valente (HPV) and started empirical antibiotic with a slight clinical improvement. Thoracic computerized tomography revealed diffuse thickening of the left mediastinal pleura and marked thickening of the interstitial interlobular and centrilobular septa, aspects attributable to exuberant pulmonary fibrosis. He underwent bronchobioscopy with evidence of generalized inflammatory signs and bronchoalveolar lavage showed lymphocytic (26%) alveolitis, negative for neoplastic cells and asbestos bodies. The respiratory function tests showed a moderate restrictive ventilatory alteration and a moderate reduction in diffusing capacity of the lungs for carbon monoxide. The bacteriological exams and autoimmune tests were negative. In order to clarify the clinical and radiological findings, the patient was submitted to pulmonary biopsy by transbronchial cryobiopsy at the right lower lobe and middle lobe. The histological results showed malignant neoplasm with organoid morphology and an immunohistochemical marking for calretinin, which was suggestive of epithelial mesothelioma. The patient was referred to a Pulmonary Oncology Day Hospital. Because of a performance status of 3, he was not submitted to treatment and was referred to palliative care.

**Conclusion:** Pleural mesothelioma is a rare neoplasm, associated with exposure to asbestos, with poor prognosis. Transbronchial cryobiopsy allows the histological characterization of pulmonary diseases, including neoplastic pathology.



PE 027

### PERSISTENT HEMOPTYSIS WITH NO APPARENT CAUSE

**FV Machado, A Marinho, M Sucena**

Centro Hospitalar São João

Key-words: Hemoptysis; Bronchial arteriography

**Introduction:** Large volume hemoptysis can be the presenting symptom in a large variety of diseases, and a fast diagnostic and therapeutic approach is called for due to its high mortality. Contrasted CT, bronchial arteriography with embolization and endoscopic studies of the airways can identify and treat the cause of hemoptysis in most cases.

We present a case of persistent, large-volume hemoptysis with no apparent precipitating factor, in which only at the third bronchial arteriography diagnosis and appropriate therapy could be made.

**Clinical case:** 55-year-old man, smoker (40 pack-years), obese, with a history of anxiety, dyslipidemia and peptic ulcer disease, visited the emergency room due to hemoptysis and wheezing for one week. The patient denied fever or any other symptom and had no known contacts with sick individuals or any previous respiratory disease. Physical examination and the analytic study had no relevant alterations. During his stay in the ER he had a new episode of large volume hemoptysis. He underwent a contrasted thoracic CT scan, which showed centrilobular emphysema with an upper lobe predominance, but no other findings, particularly suggestive of alveolar hemorrhage. He was then admitted for clinical vigilance and study of the etiology of hemoptysis.

During his stay he was submitted to a bronchial arteriography which found no relevant anatomic changes and no embolization was made. Bronchofibroscopy and rigid bronchoscopy found hematic residue and blood clots with a partial obstruction of the right upper lobar bronchus, but no active hemorrhage. Due to a period of clinical stability without further hemoptysis, the patient was discharged with a short-term scheduled reevaluation.

Two days later the patient underwent another bronchofibroscopy, in which after aspiration of a blood clot an active bleeding was observed. He was then readmitted and repeated a contrasted thoracic CT scan and bronchial arteriography, which still didn't show an apparent cause for hemoptysis. Due to the normality of the exams the case was presented to a thoracic surgeon for a possible surgical approach in case of worsening. The patient maintained hemodynamic stability and progressively lower blood loss, until the 12th day, in which he has a new episode of large volume hemoptysis. He then underwent a new bronchial arteriography which showed a bronchopulmonary arterio-arterial fistula, which was embolized. Since then the patient had no further hemoptysis and maintains follow-up in a Pneumology consultation.

**Discussion:** First line exams in the study of hemoptysis may not always be able to identify and treat the cause of the hemorrhage. In this case, the insistence in the repetition of bronchial arteriography due to the persistence and worsening of hemoptysis allowed the cause to be found and a minimally invasive therapeutic approach, avoiding an eventual surgical approach.

PE 028

### CHRONIC PULMONARY THROMBOEMBOLISM: A PARADIGMATIC CASE OF THE DISEASE'S NATURAL HISTORY

**S Heleno, M Afonso, R Abreu, T Gomes, A Fernandes**

Centro Hospitalar Trás-os-Montes e Alto Douro, EPE

Key-words: Pulmonary hypertension, Chronic thromboembolism

In a significant proportion of patients who develop acute pulmonary embolism – even with appropriate treatment – occurs an incomplete resolution of the event, placing them at risk of development of chronic thromboembolic disease. Previously considered a rare condition, chronic thromboembolic pulmonary hypertension is documented in 3,8% of patients affected by acute pulmonary embolism.

It is presented the case of a 68 year-old woman, with cardiovascular risk factors, peripheral venous insufficiency, and previous pulmonary thromboembolism – without an obvious subjacent factor – which motivated three hospital admissions, with the patient being under oral anticoagulation. The patient is admitted at urgency department reporting a three-week clinical picture of dyspnea with progressively smaller efforts, orthopnea and anorexia; she denied fever, dyspnea at rest, thoracic pain or peripheral edema. At physical examination, she showed central and peripheral cyanosis, hypotension (blood pressure of 93/64 mmHg), and severe hypoxemic respiratory failure. The analytical study demonstrated increased serum levels of myocardial necrosis markers and pro-BNP, as well as deterioration of renal function. At chest x-ray it was evident a right pleural effusion of moderate volume. She was admitted in a ward with the diagnosis of acute right cardiac decompensation with pulmonary and kidney dysfunction. Following the investigation, echocardiogram has identified pulmonary hypertension, with marked dilation of right cardiac chambers and depression of right ventricular function; venous Doppler of lower limbs excluded deep vein thrombosis. Despite efforts, the patient deteriorated with persistence of hypotension, enhancement of pulmonary and peripheral congestion, and increased requirements of oxygen supplementation. In short, it is a patient with chronic pulmonary thromboembolism conditioning pulmonary hypertension, and subsequently, severe right cardiac failure.

The presenting case illustrates the progressive nature of this condition; also, highlights the difficulty in identifying the precipitating event of clinical deterioration, in a patient with underlying chronic thromboembolic disease. Given the availability of specific potentially effective therapeutics, it becomes essential the early recognition of these cases, allowing the referral to an experienced specialized center.





PE 029

## **NODULES AND CAVITATIONS: NOT ALWAYS TB, NOT ALWAYS MALIGNANCY**

**R Viana, JC Costa**

Hospital de Santo André, Centro Hospitalar de Leiria

Key-words: granulomatosis; nodules; vasculitis

Vasculitides are uncommon conditions that can frequently involve lung vasculature. Granulomatosis with polyangiitis is the systemic vasculitis that more frequently involves the lungs with an estimated incidence of 0.7/million inhabitants.

The present case report is about a 72 years-old male with a history of a 100 packs-year smoking, arterial hypertension and hypercholesterolemia. He recurred to the urgency department of our hospital with complaints of right chest pain, without any other symptoms. His physical examination had no abnormal findings. Chest x-ray showed bilateral nodular infiltrates and chest CT revealed "(...) numerous nodular lesions, with centriacinar infiltrates showing spiculated margins, predominantly on the right upper lobe (...)".

The patient was admitted to the Internal Medicine ward. Bronchoscopy showed no endoscopic abnormal findings: *S. aureus* was isolated from bronchial aspirate; mycobacteriology and cytology were negative; histological findings from bronchial biopsy showed congestive vessels and hemorrhage. Cranial CT revealed ethmoid and maxillary sinusitis and abdominal CT presented an 18mm nodule on the left adrenal gland. Serum tumor markers were negative. He was started on levofloxacin for new-onset fever and paniculitis, showing partial clinical improvement.

Transthoracic biopsy was performed revealing areas of caseous necrosis, palisading histiocytes and multinucleated giant cells, "consistent with granulomatous inflammation with necrosis".

Tuberculosis (TB) diagnosis was assumed (not confirmed) and the patient started a therapeutic trial with 4-drug regimen (HRZE). Two months later, he presented with a four-day history of fever, nausea (associated with TB treatment), abdominal pain and diarrhea, without respiratory symptoms. In addition, he had conjunctivitis, palate petechial lesions and gingival hemorrhage. Chest radiological abnormalities and signs of paniculitis were still present at that time.

The patient was admitted to the Pneumology ward. TB treatment was stopped after three months (2 sputum samples + bronchial lavage + bronchial aspirate + bronchial biopsy with negative microscopy and cultures); therapeutic trial with TB drugs showed no clinical/radiological benefits. He was started on piperacilin-tazobactam (6 days) plus vancomycin (3 days). Drugs were suspended due to nephrotoxicity. C-ANCA PR3 were positive.

Re-evaluation of the previous biopsy samples was performed and another biopsy was done due to the suspicion of granulomatosis with polyangiitis: "multinucleated giant cells, dispersed eosinophils, microabscesses with focal necrosis of the connective tissue and signs of capillaritis - these aspects are compatible with the diagnosis of Wegener's Granulomatosis".

The patient was treated with intravenous pulses of methylprednisolone and transferred to other hospital Nephrology's department because of severe acute renal failure. Renal biopsy showed "(...) histological aspects of leukocytoclastic vasculitis, (...) consistent with ANCA-associated glomerulonephritis".

The patient was treated initially with methylprednisolone pulses, plasmapheresis and cyclophosphamide. Currently he is on maintenance treatment with azathioprine.

At the latest clinical evaluation, eight months after the beginning of treatment, the patient is significantly better with resolution of most pulmonary lesions and normalization of renal function.

The present case-report alerts to this rare condition, which may easily be confounded with other diseases like tuberculosis or malignancy. The clinical findings, together with radiological and histological results are the key to a correct diagnosis and treatment.



PE 030

### **PULMONARY ARTERIOVENOUS MALFORMATIONS: 3 CLINICAL REPORTS**

JN Caldeira, SR Sousa, Y Martins, O Santos, F Barata

Centro Hospitalar e Universitário de Coimbra - Hospital Geral

Key-words: Pulmonary arteriovenous malformations; pulmonary arteriovenous fistula; embolization therapy.

**Introduction:** Pulmonary arteriovenous malformations (PAVMs) are structurally abnormal vessels that form a capillary-free direct communication between the pulmonary and systemic circulations, providing an anatomic right-to-left shunt. PAVMs prevalence is estimated of approximately 1 per 2630. Although normally asymptomatic, their complications may be serious, such as paradoxical embolic strokes and cerebral abscesses. Hemorrhage is rare but the main contributor for the 1% maternal death rate in pregnancy. The majority of complications occur in individuals with undiagnosed PAVMs, enlightening the importance of diagnosis, management and follow-up of these patients.

**Clinical Reports:** The authors report 3 clinical reports of PAVMs in different stages of management/follow-up. The first is a 40-years-old woman, non-smoker, with a personal history of transient ischemic attack, who was referred to the Pneumology department by suggestion of PAVMs on abdominal computed tomography (CT), which was performed to study epigastralgia: two arteriovenous fistulas were detected, one in the lateral segment of medium lobe (6 mm) and the other in the posterior basal segment of right inferior lobe (10 mm). The lesions were confirmed latter by thoracic computed tomography (CT-T). The patient only complained of dyspnea during exercise. Pulmonary function tests (PFT) revealed DLCO 60/71%. Embolization of PAVMs was proposed, which she is waiting. The second refers to a 47-years-old man, non-smoker, with obstructive sleep apnea. PFT were normal. Lateral chest radiograph revealed an opacity above the cardiac silhouette. Posterior CT-T identified 3 PAVMs on the left lung, better characterized in posterior angio-CT: one in the superior lingular segment, one in the inferior lingular segment, and one in the posterior basal segment. The patient had no cough nor hemoptysis. He is waiting for reevaluation and therapeutic decision. The third is a 40-years-old woman, ex-smoker (10 UMA), who is being followed in Pneumology after an acute cholecystitis complicated by sepsis, pneumonia and right pneumothorax. She complained of progressive dyspnea with physical activity. CT-T showed a lesion on the posterior basal segment of the right inferior lobe with 6,7 mm - simple PAVM. The patient undergone embolization of the PAVM. She is currently well, symptom-free.

**Conclusion:** PAVMs are usually asymptomatic but may have serious complications. Early diagnosis and careful management and follow-up are essential to prevent those complications.

PE 031

### **PULMONARY ARTERIAL HYPERTENSION PRESENTING WITH BILATERAL MICRONODULES AND ADENOPATHIES: A DIAGNOSTIC CHALLENGE**

A Dias<sup>1</sup>, A Mineiro<sup>1</sup>, AC Santos<sup>1</sup>, N Lousada<sup>2</sup>

<sup>1</sup>Serviço de Pneumologia do Centro Hospitalar Lisboa Norte; <sup>2</sup>Serviço de Cardiologia do Centro Hospitalar Lisboa Norte; Centro de Referência de Tratamento Hipertensão Pulmonar do Centro Hospitalar Lisboa Norte

Key-words: pulmonary hypertension, micronodules

**Introduction:** vascular remodelling leads to right cardiac failure and death in pulmonary arterial hypertension (PAH). Reversibility of these changes has been field of investigation in this area.

**Case report:** male, 42-years-old, ex-smoker of tobacco and hashish, diagnosed with PAH in December 2015. At presentation, he was in functional class IV with cardiogenic shock and severe type 1 respiratory failure (FiO2 100%), mean pulmonary artery pressure (mPAP) 60 mmHg, pulmonary capillary wedge pressure 12 mmHg. Pulmonary embolism was excluded by CT angiogram. He was started on intravenous epoprostenol and ambrisentan, with clinical improvement. Sildenafil start was delayed because the patient had chronic hepatitis C (without portal hypertension) and needed to start antiviral treatment. Epoprostenol dose was progressively increased with tolerance and the patient improved to functional class II needing oxygen supplementation just during night period. About 9 months after the beginning of PAH treatment, there was clinical deterioration with dyspnea, without cough, fever, sudoresis, loss of weight or thoracic pain. He had type 1 respiratory failure (pO2=53 mmHg, O<sub>2</sub> 5L/min); chest X-ray showed a right pleural effusion and a micronodular bilateral infiltrate; C-reactive protein was elevated (10,3 mg/dL), NT-ProBNP 2510 pg/mL, auto-immune screening was negative.

The patient was admitted to the hospital and echocardiogram showed worsening pulmonary hypertension (PSAP 70 mmHg). Thoracic CT showed diffuse bilateral micronodules and small mediastinal adenopathies mostly hilar, subcarinal and pre-vascular. Pleural fluid was an exsudate with lymphocyte predominance (92%), ADA 13,7 U/L. Bacteriological and mycobacteriological exams were negative.

Blood cultures and bacteriological, mycological and mycobacteriological exams of the broncho-alveolar-lavage were negative.

Because of the bleeding risk no transbronchial biopsies were performed and the patient underwent surgical biopsy with videothoracoscopy. Macroscopically, the pulmonary parenchyma had multiple white nodules (0,1 to 0,3 mm). Microscopically, the nodules represented the bronchovascular bundle with muscular plexiform hypertrophy, mostly; occluded with necrotic fibrinoid material and infiltrated with mononucleated cells bronchiectasis with bronchiolitis and diffuse reactive lymphoid nodules. These lesions were suggestive of stage 4 hypertensive vascular pulmonary disease. No microorganisms were found.

Patient improved with diuretics reinforcement and was discharged. Epoprostenol dose was further increased at the ambulatory setting. Right-heart catheterization was repeated in December 2016 showing mPAP=42 mmHg. Hepatitis C treatment was concluded and sildenafil was associated to the treatment.





The patient is now at functional class II, without oxygen supplementation and NT-ProBNP has normalized. Thoracic CT performed in March 2017 shows major improvement of the micronodular infiltrate.

**Conclusion:** parenchymal changes secondary to idiopathic PAH are not frequent. Despite a few case reports, micronodular bilateral infiltrate is not a common radiological presentation of this disease and differential diagnosis is challenging. Histological confirmation was obtained in this case and there was improvement of the radiological changes with PAH treatment.

#### PE 032

### SCHISTOSSOMIASIS ASSOCIATED PULMONARY HYPERTENSION, A CASE REPORT

A Dias<sup>1</sup>, A Mineiro<sup>1</sup>, M Neto<sup>2</sup>, AC Santos<sup>1</sup>, N Lousada<sup>3</sup>

<sup>1</sup>Serviço de Pneumologia do Centro Hospitalar Lisboa Norte (CHLN); <sup>2</sup>Serviço de Imunoalergologia do CHLN; <sup>3</sup>Serviço de Cardiologia do CHLN  
Centro de Referência de Tratamento de Hipertensão Pulmonar (HP) do CHLN

Key-words: pulmonary hypertension, schistosomiasis

**Introduction:** chronic schistosomiasis often presents with hepatosplenic involvement.

When there is portal hypertension with porto-systemic circulation, parasite eggs can migrate to the pulmonary arterioles and originate plexiform lesions which lead to pulmonary arterial hypertension (PAH).

**Case report:** female, 47 years-old, non-smoker, born in Angola, evacuated to Portugal in 2004 when she was diagnosed with idiopathic PAH. She had been initially treated with Bosentan and Riociguat had been added later (2012 - estudo PATENT). The patient was referred to the Pulmonary Hypertension center in Centro Hospitalar Lisboa Norte in 2014. She was at functional class III. Echocardiogram showed PSAP=81 mmHg, right heart chambers dilation and pulmonary artery dilation. Right-heart catheterization showed mean pulmonary artery pressure (mPAP) of 55 mmHg, capillary pulmonary wedge pressure of 15 mmHg. She had hypoxemia at rest (pO<sub>2</sub> 62,9 mmHg) and the six-minute walking test was stopped at 2 minutes because of desaturation to 79%.

Functional respiratory assessment showed severe bronchial obstruction (FEV<sub>1</sub> post-bronchodilation 44%) and DLCO=59,2%. CT-angiogram excluded pulmonary embolism and showed huge dilation of the pulmonary artery and its branches (8,0 cm at bifurcation). It also showed diffuse septal enlargement and interstitial edema, liver enlargement and mild splenomegaly. Abdominal ultrasound was suggestive of chronic liver disease. Doppler evaluation showed no portal hypertension signs. A transesophageal echocardiogram performed at the patient's previous hospital had no signs of congenital cardiopathy. NT-ProBNP was of 306 pg/mL and there was elevation of the liver enzymes and GGT; total IgE was of 4674 uU/L (without monoclonal spike on serum protein electrophoresis). Blood eosinophil count was of 200/QL.

After excluding atopy and intestinal parasite infection, the patient was referred to the immunoallergy clinic. Etiological investigation of the IgE elevation showed 2 positive serologies for *Schistosoma mansoni*. Praziquantel was administered in September 2016 with reduction of total IgE (1368 uU/L). Epoprostenol was added to the PAH treatment.

At this stage, schistosomiasis associated pulmonary hypertension was considered because of the patient's epidemiological background and in the presence of "giant" pulmonary arteries. The patients didn't have symptoms suggestive of asthma and the bronchial obstruction was probably due to reduced bronchial caliber by the dilated branches of the pulmonary artery.

Presently, the patient is at functional class II with triple therapy. Right-heart catheterization repeated in January 2017 showed mPAP=52 mmHg. Lung transplantation has been suggested to the patient and is now under her consideration.

**Conclusion:** schistosomiasis associated PAH treatment with praziquantel may induce hemodynamic improvement, if administered early in the course of disease. When there is remodelling of the pulmonary vasculature, efficacy is reduced. With patients coming from countries where schistosomiasis is endemic, this etiology must be reminded and investigated when there is PAH and epidemiological link.



PE 033

## **PULMONARY EMBOLISM IN A GLANZMANN'S THROMBASTHENIA PATIENT**

**F Ferro, M Fernandes, P Falcão, F Caeiro, I Correia, C Bárbara**  
Centro Hospitalar Lisboa Norte - Serviço de Pneumologia

Key-words: thrombasthenia, Glanzmann, pulmonary embolism

**Introduction:** Glanzmann's thrombasthenia is an autosomal recessive disease caused by a defect in  $\alpha\text{IIb}\beta 3$  platelet's integrin. It is characterized by a decrease in platelet aggregation, predisposing to episodes of spontaneous mucocutaneous hemorrhage, variable on severity.

Despite being a hemorrhagic disease, several cases of deep venous thrombosis and pulmonary embolism have been described.

**Clinical case:** A 43-years-old female, non-smoker, with Glanzmann's thrombasthenia. She is a hypertensive and overweight patient submitted to gastric sleeve in 2011. In the last two years, she had three episodes of alveolar hemorrhage and two pneumonias. She was medicated with bisoprolol and oral contraceptive and, whenever hemorrhage episodes were present, platelets transfusions or factor VIIa was administrated.

She went to the Emergency Department for sudden dyspnea and dry cough. No fever, thoracalgia or hemoptysis was reported. She was conscious and oriented with scattered bruises. Physical examination included TA 91/58mmHg, FC 104bpm, 97% saturation in ambient air, and decreased vesicular murmur and crackling at lung's bases. Blood tests showed: Hg 14g/L, without leukocytosis, PCR-9mg/dL, D dimers-0.48ug/mL, negative troponin, NTproBNP-362pg/mL, GSA(2L): pH-7.41, pCO<sub>2</sub>-30.4, pO<sub>2</sub>-85.5, HCO<sub>3</sub>-22.4, lact-9.

The patient also presented an unaltered electrocardiogram and showed heterogeneous opacity in the lower half of the right lung, as evaluated by chest radiography. The AngioTC documented small defects of repletion on the subsegmental branches of the bilateral pulmonary arteries and areas of densification at lung bases. An echocardiogram showed a non-dilated right ventricle, preserved systolic function and low probability for pulmonary hypertension.

She was admitted to the Pulmonology Department where she started unfractionated heparin and suspended oral contraceptive. Due to the high risk of hemorrhage, platelets transfusions were performed twice a day. A new oral contraceptive was initiated due to menorrhagia.

She also underwent antibiotic treatment with amoxicillin clavulanic acid and azithromycin for community-acquired pneumonia. The thrombophilia study was negative.

AngioTC reevaluation indicated a total resolution of the defects of repletion of the segmental and subsegmental branches of the pulmonary arteries as well as of the pulmonary infiltrates.

In conjunction with the Immunotherapy Department, and after a discussion with the patient, it was decided to use warfarin as anticoagulation strategy. However, a week later, the patient developed extensive petechiae in the lower limbs and warfarin was suspended. Since then, no thrombotic episodes occurred despite two new episodes of alveolar hemorrhage.

**Conclusion:** Although Glanzmann's thrombasthenia is a hemorrhagic disease, venous thrombosis can occur, obliging to maintain a high level of clinical suspicion.

In cases described in the literature, it is common the use of unfractionated heparin as initial strategy of anticoagulation given the rapid reversibility of this drug. However, there is no consensus about the best anticoagulant in the outpatient setting.

Given the patients previous episodes of alveolar hemorrhage, warfarin was chosen due to the easy access to its antidote. However, the appearance of extensive petechiae in the subsequent days lead to reevaluation and to the consequent suspension of anticoagulation. Hence, case-by-case decisions with multidisciplinary teams, based on the patient's hemorrhagic risk are advocated.





PE 034

### FALCIFORM CELL ANEMIA: A CAUSE OF PULMONARY HYPERTENSION, MULTIPLE MECHANISMS

FG Oliveira<sup>1</sup>, A Dias<sup>1</sup>, A Mineiro<sup>1</sup>, AC Santos<sup>1</sup>, N Lousada<sup>2</sup>

Serviço de Pneumologia do Centro Hospitalar Lisboa Norte; Serviço de Cardiologia do Centro Hospitalar Lisboa Norte; Centro de Referência de Tratamento de Hipertensão Pulmonar do Centro Hospitalar Lisboa Norte

Key-words: Pulmonary Hypertension, sickle-cell disease, pulmonary thromboembolism

**Introduction:** Pulmonary Hypertension (PH) has an incidence of 6 to 10% in adults diagnosed with sickle cell disease. Its existence increases the morbidity and mortality of its underlying disease, especially in the presence of homozygous genotype (HbSS). Its early identification and appropriate treatment is quite important.

**Clinical case:** The authors present the case of a 52-year-old black female, native of Cape Verde, resident in Portugal since the age of 34, diagnosed with sickle-cell disease (HbSS genotype) since 1994 who is accompanied by the Hematology Department since 1999. In 2003 and 2007, she was hospitalized for vaso-occlusive crisis. In 2009, she started hydroxyurea with apparent control of episodes of falciparization. In 2011, she performed a thoracic contrast-enhanced CT scan that was compatible with segmental and subsegmental pulmonary thromboembolism (PTE); the echocardiogram performed at that time showed PSAP= 110 mmHg. In 2012 she is referred to the Cardiology Department and performs right-heart catheterization that shows PmAP= 25 mmHg. Since there was functional deterioration, she repeated Right-heart catheterization in 2013, which revealed an increase of PmAP to 35 mmHg; she started sildenafil in the dose of 20 mg tid and later 40 mg tid. In 2015, the patient initiates long-term oxygen therapy. She also developed renal failure and began follow-up at the Nephrology Department. At this point, she was referred to our hospital's Pulmonary Hypertension Referral Center, with the diagnoses of PH group 1 and 4, sickle-cell anemia HbSS, chronic renal failure and hemochromatosis secondary to multiple transfusions. Right-heart catheterization performed in November 2016 showed PmAP of 33 mmHg, PECP 10 mmHg, CI 5.15 L/min/m<sup>2</sup>, RPT 2.61 uWood and RVP 2.61 uWood, revealing hemodynamic stability. The case is then discussed with Immunohemotherapy and the patient was subject to a chronic transfusion program for an hemoglobin target of 10 g/dL. Possible endarterectomy is considered but not implemented, due to the high surgical risk and peripheral location of PTE. Ambrisentan is associated with tight initial monitoring for possible hemoglobin drop, which does not occur.

The patient remains in functional class II, under oxygen therapy, maintaining an active life.

**Conclusion:** The relevance of the clinical case due to its rarity is highlighted by the complexity and importance of a multidisciplinary follow-up of these patients, in whom the diagnosis of PH must be early and whose sickle cell therapy, particularly transfusion, is altered by concomitant diagnosis. The target value of hemoglobin is usually 8 g/dL however, since it is associated to PH and after discussion with the Immunohemotherapy Department, a new target value of 10 g/dL was established.

Optimizing the control of both diseases is essential to guarantee patients' quality of life and avoid serious multisystemic complications.

PE 035

### CHRONIC THROMBOEMBOLIC PULMONARY HYPERTENSION - CASE REPORT

D Silva<sup>1,3</sup>, D Maia<sup>1,3</sup>, V Caldeira<sup>1,3</sup>, M Emiliano<sup>1,3</sup>, R Cerejo<sup>2,3</sup>, A Agapito<sup>2,3</sup>, J Cardoso<sup>1,3</sup>, J Fragata<sup>2,3</sup>

<sup>1</sup>Department of Pulmonology of the Hospital Center of Central Lisbon (CHLC), Santa Marta's Hospital; <sup>2</sup>Department of Cardiothoracic Surgery of the Hospital Center of Central Lisbon (CHLC), Santa Marta's Hospital; <sup>3</sup>Nova Medical School / Faculty of Medical Sciences, New University of Lisbon

Key-words: cteph, thromboendarterectomy, pulmonary hypertension, chronic thromboembolism

**Introduction:** CTEPH is a uncommon disease, with an incidence of 0.5 to 3.8% following an initial episode of acute pulmonary thromboembolism.

**Case report:** Man, 74 years old, non-smoker, locksmith. No personal background. The patient referred dyspnea (mMRC=3) with eight months of evolution, with no other sign or symptom. The functional respiratory study revealed parameters within normality, and gasometrically presented hypocapnia and slight hypoxemia in ambient air (PaCO<sub>2</sub> = 31.2mmHg, PaO<sub>2</sub> = 65mmHg and SatO<sub>2</sub> = 95%). He walked 375 meters on 6MWT with a minimum saturation of 89%. In this context, he performed a chest radiography showing an exuberant bilateral hilar engorgement and later he performed a thoracic angio-CT, which documented pulmonary parenchyma with a mosaic pattern, an enlarged pulmonary artery trunk, and filling defects attributable to pulmonary thromboembolism in the right pulmonary artery and in all lobes, bilaterally, involving interlobar, segmental and subsegmental branches, and initiated oral anticoagulation. Transthoracic echocardiography revealed right cavity dilatation and severe pulmonary hypertension, with an estimated PSAP of 86 mmHg. The study of thrombophilia was negative, such as the echo-doppler of the lower limbs. Pulmonary angiography revealed predominantly right embolic obstruction. The diagnosis of Chronic Thromboembolism Pulmonary Hypertension (CTEPH) was admitted, and the patient was submitted to a permanent filter placement in the inferior vena cava and pulmonary thromboendarterectomy, with significant clinical improvement, resting gasometric normalization and 50-meter increase in 6MWT of reevaluation.

**Discussion:** Early diagnosis of CTEPH is hard, due either to the low specificity of the symptoms or the high rate of patients without a previous history of deep vein thrombosis or pulmonary embolism, that is estimated at around 30%. Beyond the hypocoagulation, the treatment of CTEPH is surgical, and for most patients, a successful pulmonary thromboendarterectomy is curative, which has occurred in this patient.



PE 036

## **SARCOIDOSIS VS HEART INVOLVEMENT IN CVID. NEW HORIZONS**

**P Americano, SL Silva, K Cunha, M Barbosa, U Brito**  
Hospital de Faro, Centro Hospitalar do Algarve

Key-words: CVID, GLILD, granulomatous disease, sarcoidosis, cardiac, involvement

**Introduction:** Common Variable Immunodeficiency (CVID) is the most frequent primary immunodeficiency and in the last few years, after the introduction of intravenous immunoglobulin G (ivIgG) replacement therapy, there was a reduction in early mortality due to opportunistic infections and an increase in chronic complications, the lung being the organ most frequently affected by a range of alterations commonly referred to as granulomatous lymphocytic interstitial lung disease (GLILD). The authors describe a case that illustrates the different characteristic changes in CVID and where the concomitant diagnosis of sarcoidosis is questioned.

**Clinical Case:** Female patient, 27-years-old, without relevant exposures, started in the first years of life repetitive upper respiratory tract infections, until she was 8-years-old, when she went to the Emergency Department with a clinical picture interpreted as pneumonia, being referenced to Pediatrics consultation. At the first observation, there were small cervical ganglia and palpable splenomegaly 6 fingers below the rib cage. Analytically with anemia, thrombocytopenia, pan-hypogammaglobulinemia and ECA 117U/L. Thoracic radiography with right paratracheal adenopathies and multiple diffuse nodular condensation areas.

Later thoracic-CT showed hilar, paratracheal and subcarinal adenopathies, and multiple micronodular and nodular parenchymal lesions. Bronchofibroscopy without endobronchial changes. Bronchoalveolar lavage with increased cellularity, 46% lymphocytes and CD4/CD8: 2.2. Transbronchial lung biopsy with lymphoid hyperplasia of peribroncovascular and alveolar predominance and non-caseous granulomas.

Sarcoidosis was diagnosed and corticotherapy was started with progressive resolution of adenomegaly, splenomegaly, and cytopenias. Next year, considering persistent hypogammaglobulinemia, no response to vaccination, maintenance of respiratory infections with isolates of *H.influenzae* and *M.catarrhalis*, she was diagnosed with IDCIV and initiated ivIgG replacement therapy at 5g/month. One year later, corticotherapy was discontinued due to iatrogenic Cushing's syndrome.

Over the next 9 years she maintained stable lung function, 3-4 respiratory infections per year, one Herpes zoster infection and two peri-orbital cellulites. Although pre-infusion IgG doses were consistently <300mg/dL, subtherapeutic dose was maintained.

At 18-years-old, she noticed worsening tiredness and palpitations and began to be followed in the differentiated consultations of sarcoidosis and primary immunodeficiencies. The dose of ivIgG was adjusted to 20mg/month with normalization of pre-infusion dosages and complementary exams were repeated, highlighting echocardiogram with myocardial sarcoid infiltration, later confirmed by magnetic resonance imaging. Corticotherapy was reinitiated.

Three years later, due to new clinical, radiological and functional deterioration, with maintained cardiac involvement, methotrexate was initiated.

Since then she maintained stable with 2-3 upper respiratory tract infections per year and chronic diarrhea with recurrent *Campylobacter* isolations in feces.

**Conclusion:** The similarity between the pulmonary manifestations of sarcoidosis and CVID makes the differential diagnosis between the two entities difficult. In this case, which is very characteristic of CVID, it's assumed the concomitant diagnosis of sarcoidosis due to cardiac involvement, which has never been reported in CVID. No pathophysiological mechanism is known that excludes cardiac involvement in GLILD. The authors underline the constant updating of medicine and the possibility of new presentations, especially in a field of recent development such as primary immunodeficiencies, in which the introduction of new therapies had a profound impact on the natural history of the disease.





PE 037

### SARCOIDOSIS: A DIFFICULT CONTROL CASE

D Rodrigues, M Valério, T Costa, A Arrobas

Serviço de Pneumologia B, CHUC

Key-words: Sarcoidosis, Infliximab, corticotherapy

**Introduction:** Sarcoidosis is a systemic granulomatous disease of unknown etiology that can reach any organ or system, with the lungs and lymphatic system being most commonly affected. There is currently no curative treatment option, and corticoid therapy is indicated in cases of chronic and/or progressive sarcoidosis for symptomatic relief and to reduce the progression of the disease. Even with optimized treatment, the clinical response is variable, and the treatment is often associated with secondary effects. So, New drugs are being used.

Infliximab is a monoclonal antibody that inhibits tumor necrosis factor  $\alpha$  (TNF- $\alpha$ ). In the case of active sarcoidosis, there is evidence of a correlation between TNF- $\alpha$  release and disease progression. The use of Infliximab has shown good results in terms of efficacy and safety.

**Clinical Report:** Female patient, 56-year-old, professional activity at a fuel supply station, with a diagnosis of Sarcoidosis (Documented by Biopsy and Bronchoalveolar lavage), which was sent to the Pulmonary Interstitial Pathology due to imaging aggravation, with presence of fibrosis and spiculate nodule (new finding); And clinical, with worsening dyspnea, on treatment with Deflazacorte 6mg on alternate days.

At our first observation, the patient presented complaints of dyspnea (mMRC 3) and recurrent episodes of hemoptysis.

An analytical study was performed, which showed high SACE and VS, with negative microbiological study; Respiratory functional study documented mixed ventilatory alteration and decreased DLCO, arterial gasimetry without alterations; High resolution CT scan with scattered nodular pattern, areas of ground glass and fibrosis, and with a spiculated, juxta-pleural node on RUL.

The dose of Deflazacorte was increased and then Azathioprine was also introduced, and the patient responded with clinical stability.

The nodular image was approached by biopsy (Transbronchial and transthoracic), which did not show malignant cells.

A scintigraphy was performed with shown pulmonary, lymph node and splenic involvement, raising doubts about cardiac involvement. She underwent transthoracic echocardiography with excluded functional or morphological alterations compatible with cardiac sarcoidosis.

After the initial period of clinical improvement and imaging stability, there were other periods of clinical degradation, with progressively greater dose Deflazacorte and Azathioprine needed for clinical stabilization. Despite the high doses of these drugs (75 mg of Deflazacort and 150 mg of azathioprine), the patient continued to present frequent periods of aggravation, having developed a branch block pattern on the ECG. It was decided to propose for treatment with biological agent (Infliximab).

After the introduction of Infliximab, clinical improvement and sustained imaging stability were achieved, allowing reduction of corticoid and Azathioprine dose (15mg + 75mg, respectively). There was an improvement in quality of life, with a reduction in the number and severity of exacerbations, better tolerance to exertion, absence of hemoptyses, and a return to normal day life activity. Therefore, this case report intends to affirm the efficacy of Infliximab treatment in a patient with Stage IV sarcoidosis with poor response to conventional therapy (corticosteroid + corticosteroid sparing agents).

PE 038

### ACUTE FIBRINOUS AND ORGANIZING PNEUMONIA (AFOP), A RARE ENTITY - TWO CLINICAL CASES

JSJ Barata, R Silva, M Baptista, E Magalhães, I Vicente, MJ Valente, MS Valente

Centro Hospitalar Cova de Beira

Key-words: Fibrin, pneumonia, biopsy, steroid therapy

**Introduction:** AFOP is a rare, recently described entity characterized histologically by deposits of intra-alveolar fibrin and organizing pneumonia but without the classical presence of hyaline membranes typically associated with diffuse alveolar disease. Despite the histological diagnosis, the spectrum of clinical presentation, therapeutic outcomes and prognosis are widely variable.

**Clinical cases:** We report a case of a male patient, 54 years old, a construction worker, a smoker (40 packs a year), with a clinical condition with about 2 weeks of evolution characterized by constitutional syndrome (nocturnal sweating, asthenia, anorexia and weight loss) with progressive worsening and within 2 days prior to the emergency department, productive cough of purulent expiration and rapidly progressive exertional dyspnea. The complementary evaluation identified elevation of inflammatory parameters, parenchymal area of consolidation with 60mm with depolished glass pattern in the right lower lobe and mediastinum-hilar adenopathies. Despite a favorable clinical course with antibiotics, the persistence of the imaging alterations led to the transthoracic pulmonary biopsy, which evidenced the diagnosis. Serial repetition of computed tomography of the thorax revealed total resolution of the lesion without institution of corticoterapia. The second case refers to a 69-year-old woman with diffuse sequelae bronchiectasis of pulmonary tuberculosis who is referred to the emergency department for a clinical presentation with a 3-day course characterized by hyperthermia, rapidly progressive exertional dyspnea, productive expiratory cough purulent and right thoracalgia of pleuritic characteristics. Analytically, there was an elevation of inflammatory parameters, partial respiratory insufficiency and the imaging study identified multiple bilateral nodular formations, some cavitated, with adjacent depolarized glass and mediastinal adenopathies. During hospitalization, he performed broad spectrum antibiotic therapy with clinical and analytical improvement. The patient refused to perform bronchofibroscopy then was proposed for transthoracic lung biopsy, whose anatomopathological study evidenced the diagnosis. He underwent systemic steroid therapy in a regressive scheme for one year, presenting clinical improvement, resolution of respiratory failure and reduction of lung nodules volume.

**Conclusions:** The authors present these cases by the rarity of the pathological entity, distinct therapeutic approach and different evolution verified.



PE 039

### CHEMICAL PNEUMONITIS - A CLINICAL CASE

**AA Santos, C Guimarães, JM Correia, F Nogueira**

Serviço de Pneumologia, Hospital de Egas Moniz, Centro Hospitalar de Lisboa Ocidental

Key-words: chemical pneumonitis, aspiration

**Introduction:** The hydrocarbons are a number of chemical compounds that consist entirely of hydrogen and carbon, united by covalent bond. When aspirated their effect on the respiratory system occurs mainly through direct lesion. The main finding is necrotizing pneumonia. Other finding include: direct epithelial lesion, alveolar septae and pulmonary capilar, as well as surfactant solubilization. Secondary effects may include atelectasis and interstitial inflammation. The systemic response to the chemical aggression frequently causes fever.

**Clinical case:** 27 year old, caucasian male, actor, without known clinical history, smoker (mean pack years estimated in 10), goes to the emergency room complaining of dry cough after accidental ingestion and aspiration of a small volume of "fire-water" - a combination of hydrocarbons used in pyrophagy. He presented without signs of respiratory distress, with peripheral oxygen saturation of 99%, had oropharyngeal redness and frequent cough. Pulmonary auscultation showed a maintained and symmetrical vesicular murmur, without adventitious sounds. Of the complementary exams performed in the ER we highlight: normal arterial blood gases, summary analytical evaluation without alterations, chest X-ray with an heterogeneous opacity of ill-defined limits on the right heart border that made the silhouette sign with the cardiac edge and an heterogeneous opacity of ill-defined limits on the left cardiac border also making silhouette sign. In order to clarify these findings, he underwent thoracic CT that presented: "confluent alveolar condensations with ground glass densification at the periphery, with bilateral distribution with anterior predominance and in the lower lobes. These reach the middle lobe, the lingula and the anterior segment of the LSE and the anterior basal segment." A high probability of bacterial overinfection was assumed and antibiotic therapy with Clindamycin was initiated. He was transferred to the Pulmonology Department. During hospitalization, initial aggravation was observed, with hypoxemia at rest (PaO<sub>2</sub> 60 mmHg) and fever. To evaluate the repercussions in the respiratory and digestive tract, he underwent bronchofibroscopy and upper digestive endoscopy - both without alterations. After the initial worsening, there was a consistent clinical improvement, with a reduction in O<sub>2</sub> supply requirements. He was discharged asymptomatic with normal gasimetry in room air. The chest x-ray at the time showed improvement of both condensations, maintaining the opacity on the right (although improved) in topography referring to the middle lobe. In the outpatient reassessment after 4 months, he was asymptomatic and had a normal respiratory functional study.

**Conclusion:** We present this clinical case due to its unusual nature and imaging richness. We'd like to emphasize that the fact that the repercussion were exclusively pulmonary, with no systemic or digestive toxicity, and also the fact that a complete recovery was observed.

PE 040

### A CASE OF PULMONARY FIBROSIS SECONDARY TO OXALIPLATIN: FROM RARITY TO REALITY

**AC Moreira, R Gomes, J Soares, JR Vieira, H Mansinho**

Serviços de Pneumologia e Oncologia, Hospital Garcia de Orta

Key-words: oxaliplatin; fibrosis; interstitial

Oxaliplatin currently integrates the standard therapeutic regimen of colorectal carcinoma at different stages. The most commonly observed adverse effects are peripheral neuropathy, haematological toxicity, and allergic reactions. Although rare, some cases of acute pulmonary fibrosis secondary to Oxaliplatin therapy have been reported. The true incidence of pulmonary toxicity is unknown but has been associated with respiratory failure and pulmonary infiltrates with subsequent evolution to fibrosis.

The authors present a case of pulmonary fibrosis of a rapidly progressive evolution following initiation of oxaliplatin and capecitabine (Xelox) therapy.

A 71-year-old male patient with a previous history of smoking (tobacco pack 60 units-pack / year), arterial hypertension, dyslipidemia, duodenal ulcer and femoro-popliteal venous thrombosis in 2009. Since January 2014 under treatment with Auto-CPAP, for Severe Sleep Obstructive Apnea Syndrome (apnea / hypopnea index 67 / hour), under consultation of Pulmonology with annual surveillance. In the functional respiratory study initially performed in consultation, in May 2014, there were no changes in ventilatory mechanics, lung and gas volumes. In March 2016, after the diagnosis of rectal adenocarcinoma (T1N1M0), he underwent sigmoidectomy and ileostomy. He underwent adjuvant chemotherapy with Oxaliplatin and Capecitabine in April, having completed 8 cycles, until October 2016. Concomitant with the last cycle of chemotherapy, he started a rapidly progressive dyspnea associated with productive cough of muco-purulent expiration and quantified weight loss of 18 kg in 8 months. At that time he was medicated with amoxicillin-clavulanic acid and clarithromycin, with improved complaints of coughing and expiration. When observed at a Pulmonology consultation in November 2016, he had complaints of dyspnea (mMRC class 4), with evidence of partial respiratory insufficiency (PaO<sub>2</sub> 53mmHg, SO<sub>2</sub> 88.9%). Ventilation / perfusion scintigraphy was performed, with no evidence of pulmonary thromboembolism. In the respiratory functional study, evidence of a mild restrictive pattern (FVC 2.47 / 78.9%, CPT 4.69 / 78.9%) and diffusion to carbon monoxide (DLCOc 35.4) severely decreased. He underwent home oxygen therapy in January 2017. Thoracic computed tomography (CT) was performed in February 2017, with evidence of pulmonary fibrosis predominant at the periphery, more pronounced at the lung bases and more on the right lung, with interstitial reticular pattern and bronchiectasis, compatible with usual interstitial pneumonia (UIP). After discussion at a Multidisciplinary Meeting on Interstitial Pathology, regarding the temporal association between clinical and imaging findings and the initiation of chemotherapy, the most likely hypothesis was that of pulmonary fibrosis secondary to oxaliplatin. Currently the patient remains stable from the point of view of cancer disease, with evidence of remission. When evaluated in a Pulmonology consultation in May 2017, an overall clinical and gasimetric improvement was evident, with a clear reduction in dyspnea (mMRC 2), absence of cough and a PaO<sub>2</sub> 66.3 mmHg and SO<sub>2</sub> 93.2% in ambient air.

This case demonstrates a rare complication of Oxaliplatin therapy compared to pulmonary infectious complications, and the clinical suspicion of pulmonary toxicity is essential given the associated morbidity and mortality.





PE 041

### DIFFUSE ALVEOLAR HEMORRHAGE (DAH) SECONDARY TO DABIGATRAN- A CASE REPORT

IS Pereira, A Alves, C Ribeiro, E Silva, T Shiang, M Vanzeller  
Centro Hospitalar de Vila Nova de Gaia/Espinho

Key-words: Alveolar hemorrhage, Dabigatran

**Introduction:** In our clinical practice we are confronted with a large number of hypocoagulated patients. Within the different anticoagulant agents the new oral anticoagulants (NOAC) are increasingly used. Hypocoagulation can be a cause of hemoptysis, and can have fatal consequences.

**Case Report:** 69-year-old male, retired, former smoker. Previous history of COPD (group B), heart failure, atrial fibrillation, alcoholic liver disease and type 2 diabetes mellitus. Chronically medicated with amiodarone, dabigatran, gliclazide, furosemide and glycopyrronium bromide with indacaterol.

He went to the emergency room (ER) with complaints of asthenia, worsening of the usual pattern of dyspnea, hemoptoic sputum, nocturnal cough, orthopnea and pleuritic chest pain for the past 3 days. He also referred weight loss of 8-10 kg in the last year. Objectively, he was afebrile, tachypneic, with no other signs of respiratory difficulty, peripheral saturations of 95% in room air and hemodynamically stable with arrhythmic pulse. Blood tests showed normal hemogram and renal function, mild hyponatremia (Na 134 mmol / L) and C-reactive protein 5.57 mg / dl. Chest X-ray showed heterogeneous infiltrates on the medium 1/3 of the right hemithorax and homogenous opacity of the left base compatible with small volume pleural effusion. Community acquired pneumonia was admitted and the patient was started on empiric antibiotic therapy completing 10 days of treatment. Despite clinical and analytical improvement, persistence of radiological changes led to chest - CT. This revealed a poorly systematized area of consolidation in the posterior segment of the right upper lobe, apical segment of the right lower lobe and, less expressively, in the basal segments with slight thickening of the interlobar septa, raising the hypothesis of alveolar hemorrhage. Bronchoalveolar lavage (BAL) was performed without macroscopic criteria for alveolar hemorrhage but whose hemosiderin search was compatible with mild alveolar hemorrhage.

Given the suspected alveolar hemorrhage due to dabigatran, the case was discussed in a multidisciplinary manner and the patient was discharged with indication to maintain oral anticoagulation with warfarin. Oral hypocoagulation was subsequently discontinued at a reevaluation due to inability to comply therapeutically. Despite this indication, the patient resumed dabigatran and, about 2 weeks after this resumption, resorted to the ER again due to exacerbation of dyspnea and hemoptysis. The patient presented with type 1 respiratory failure, hemoglobin drop of 2.2 g / dl from previous hospitalization (1 month before) and worsening of radiological findings: heterogeneous infiltration of the left lung field and the middle 1/3 of the right lung field. Hypocoagulation was suspended with resolution of hemoptysis and respiratory failure and with radiological improvement.

**Conclusion:** Although being considered a rare complication of NOAC, DAH is a potentially fatal consequence and should be considered in the differential diagnoses of patients undergoing NOAC who present with hemoptysis or bilateral pulmonary infiltrates. Early recognition and intervention is critical as reversing the action of these agents can be difficult.

PE 042

### THE DIAGNOSTIC CHALLENGE OF THE SOLITARY PULMONARY NODULE - CLINICAL CASE

SC Silva<sup>1</sup>, N Caires<sup>1</sup>, RD Coelho<sup>1</sup>, AS Santos<sup>1</sup>, T Lopes<sup>1</sup>, L Semedo<sup>1</sup>, J Cardoso<sup>1,2</sup>

<sup>1</sup>Pneumology Department of Hospital Santa Marta; <sup>2</sup>NOVA Medical School

Key-words: pulmonary nodule, interstitial diseases, desquamative interstitial pneumonia

**Introduction:** The pulmonary nodule is a common radiologic finding. In smoking patients it is mandatory to exclude neoplasia, but other possible lung manifestations of smoking should not be ignored, such as interstitial diseases.

**Clinical case:** 41-year-old caucasian woman, previously autonomous, active smoker (20 PYU), with moderate ethanolic habits and untreated HCV infection. Interned at the Department of Neurology to study a clinical condition with a year of evolution of pain and paresthesias of the lower limbs with significant gait limitation in the last 6 months and cognitive deterioration in the last month. She performed an electromyogram that confirmed the diagnosis of predominantly axonal and sensitive polyneuropathy, especially at the lower limbs and distal limb segments. A thoraco-abdominal-pelvic CT scan revealed a spiculated nodular lesion (18x19mm) in the apical segment of the right lower lobe (RLL), as well as a micronodule of 3mm and another micronodule in the apex of the posterior segment of the left superior lobe (LSL) of 2mm. A bronchofibroscopy was performed and the endoscopic aspects were normal and the cytology of bronchoalveolar lavage (BAL) was negative for neoplastic cells. The functional respiratory study revealed a slight obstructive ventilatory alteration with pulmonary insufflation. She was proposed for atypical resection of the RLL with extemporaneous exam that was negative and, therefore, it was continued for segmentectomy of segment 6. The histological result excluded the hypothesis of neoplasia, favoring aspects suggestive of Desquamative Interstitial Pneumonia (DIP). The neurological condition was then interpreted in the context of HCV infection and the patient evolved well with recovery of gait control and cognitive alterations under treatment with gabapentin, thiamine, sertraline and diazepam. She remained under surveillance and asymptomatic after cessation of smoking habits.

**Conclusions:** This case aims to demonstrate the difficulty of approaching the solitary node of the lung. The diagnosis has become particularly interesting because, unlike to what has been found in this patient, DIP is an infrequent diagnosis that mainly affects male smokers between the 4th and 5th decades of life.

PE 043

## **EOSINOPHILIC PNEUMONIA IN A PATIENT WITH BRONCHIAL ASTHMA**

**A Magalhães, I Moreira, D Silva, V Caldeira, R Coelho, L Semedo, J Cardoso**

Serviço de Pneumologia do Centro Hospitalar Lisboa Central (CHLC) - Hospital de Santa Marta; Nova Medical School - Faculdade de Ciências Médicas da Universidade Nova de Lisboa

Key-words: Eosinophilic pneumonia, bronchial asthma

**Introduction:** Eosinophilic Pneumonias are a heterogeneous group of diseases with infrequent diagnosis. Characterized by pulmonary eosinophilia superior to 25% with or without peripheral eosinophilia. They can be classified as primary/idiopathic or secondary when a well established etiology is identified. The spectrum of presentation of these diseases varies from a clinical picture of indolent installation to the acute respiratory failure with a need for mechanical ventilation.

**Clinical case:** Describes the case of a 56-year old male, non-smoker, civil engineer, with previous diagnosis of bronchial asthma and rhinitis, well controlled under treatment with formoterol/budesonide 160/4.5 ug, montelukast 10 mg and bilastine 20mg. Referenced to a Pulmonology Consultation due to a clinical frame with about a month of evolution of dyspnoea to progressively smaller efforts, dry cough, night sweats and non-quantified weight loss, without other associated symptoms. No new medication was recently initiated and there was no history of travels to endemic regions for parasite infections. There was a reference to a recent exposure to inorganic dust in an occupational context. Objectively, there was a normal pulse oximetry, pulmonary auscultation with extended expiratory time, without adventitious noises, and absence of positive articular or cutaneous signals.

Of the complementary diagnostic study to be highlighted: peripheral eosinophilia of 17.4%, total IgE 383 KUI/L and ESR 18 mm/h, being the renal and the hepatic function and other inflammatory parameters normal; chest radiograph with diffuse interstitial infiltrate of predominance on the left and thoracic CT confirming extensive interstitial changes in the entire left lung and lower expression in the right upper lobe; respiratory functional study, under bronchodilator therapy with FEV1/FVC 73%, FEV1 89%, FVC 95%, TLC 86%, DLCO 71.5%, DLCO/VA 91%; Bronchofibroscopy showed no endoscopic alterations, with eosinophilia > 30% in bronchoalveolar lavage, with negative microbiological exams; No lung biopsy was carried out by cough during the procedure. Subsequently conducted study of autoimmunity, infectious serologies and dosing of specific IgE and precipitins to Aspergillus which were negative. In this clinical context the diagnosis of Eosinophilic Pneumonia with a subacute evolution in a patient with bronchial asthma was admitted. Treatment with prednisolone 0.5mg/kg/day was initiated, maintaining the remaining usual medication. After about 4 weeks there was significant clinical and radiological improvement, and therefore weaning from systemic corticosteroid therapy was started until a maintenance dose, without recurrence of the condition until now.

**Discussion:** Eosinophilic pneumonias are a group of diseases that are difficult to diagnose among themselves, and their possible association with previous diagnosis of bronchial asthma is well known. Due to an unspecific clinical presentation, it is essential to maintain a high degree of suspicion for the diagnosis to be rapidly established and the therapy instituted, being in these cases the prognosis favorable.

PE 044

## **SARCOIDOSIS INDUCED BY CAPECITABINE - A CASE REPORT**

**IS Pereira, A Alves, C Marques, S Neves, I Ladeira**

Centro Hospitalar de Vila Nova de Gaia/Espinho

Key-words: sarcoidosis, capecitabine

**Introduction:** Sarcoidosis is a multisystemic granulomatous disease. The cause remains unknown most of the times but there are some descriptions of associations with some chemical products, genetic or immunologic factors. There is only one Case Report published of sarcoidosis induced by Capecitabine.

**Case Report:** 61-year-old male, bank employee, non-smoker. Previous history of colon adenocarcinoma T3N0R0, underwent surgery in October 2015 and adjuvant chemotherapy with Capecitabine for 6 cycles. In the post-op he was diagnosed with a pulmonary thromboembolism and chronically medicated with dabigatran. No relevant exposures known.

The patient was sent to the Gaia CDP due to thoracic CT lesions (CT performed in a follow-up context of colon adenocarcinoma). CT scans showed scattered micronodules with subpleural predominance. Clinically asymptomatic with no relevant examination changes.

He underwent bronchofibroscopy - no visible endobronchial changes. Bronchoalveolar lavage (BAL) did not identify any microbiological or mycobacteriological agent. In BAL there was a lymphocitic and neutrophilic alveolitis with a CD4/CD8 ratio of 10/17. Cryobiopsy presented a chronic granulomatous inflammatory process without necrosis. His functional respiratory test (FRT) was normal (FEV1 112%, FVC 99%, DLCO 95%).

Therefore, the diagnosis of sarcoidosis with pulmonary involvement was made. As the patient maintained asymptomatic and without changes in the FRTs it was decided not to start medication for now and he remains in vigilance.

**Conclusion:** The cause of sarcoidosis is still unrevealed, and it is essential to doubt this diagnosis in an early stage. There is an increasing association of sarcoidosis with certain drugs and a case of Capecitabine-induced sarcoidosis was published in 2012. It is therefore important to be alert to the possibility of developing sarcoidosis in patients undergoing or who have already undergone chemotherapy.





**PE 045**

**PNEUMOLOGY AS A BRIDGE FOR THE DIAGNOSIS  
OF A SYSTEMIC PATHOLOGY: A CLINICAL CASE OF  
HYPEREOSINOPHILIC SYNDROME**

**A Alves, I Sucena, E Silva, C Ribeiro, T Shiang, M Vanzeller**

Serviço de Pneumologia do Centro Hospitalar de Vila Nova de Gaia/Espinho

Key-words: Hypereosinophilic syndrome

**Introduction:** Hypereosinophilic syndrome (HES) is rare and may occur in the context of a heterogeneous group of disorders that cause excessive and sustained production of eosinophils. It is characterized by peripheral hypereosinophilia ( $> 1500$  cells/QL) in two evaluations separated for at least one month and by organ lesion/dysfunction due to eosinophilic infiltration. It may occur in the context of recognized causes of hypereosinophilia (parasitic infections, drug allergy and neoplasms), but in about 75% of cases it is not possible to identify the underlying etiology. Pulmonary involvement is common and may be the form of presentation of HES.

**Clinical case:** Man, 37 years old. History of asthma and chronic rhinosinusitis. He reported an increase in the frequency of upper airway infections in the last six years and had documented peripheral blood hypereosinophilia in the last three years. The patient went to the Emergency Department for a two-week course of sustained fever, dyspnea and mildly hemoptoic cough. He presented leukocytosis with exuberant eosinophilia ( $7850/\mu\text{L}$ ) and CRP  $10.38$  mg/dL. The chest CT showed bilateral opacities, some with ground-glass opacification, bibasal reticular thickening and adenomegaly. A diagnosis of pneumonia was assumed and the patient was hospitalized for treatment and continuation of the study of hypereosinophilia. He fulfilled seven days of levofloxacin  $750$  mg once a day with clinical and radiological improvement. The patient maintained marked peripheral hypereosinophilia (maximum  $19.480/\mu\text{L}$ ). There were no skin or neurological changes. From the complementary study, negative autoimmunity, negative stool parasitology, normal tryptase serum level, normal karyotype and bronchoalveolar lavage with eosinophilia  $> 35\%$  were observed. Pulmonary biopsy was compatible with interstitial pneumonia with a significant number of eosinophils. Transthoracic echocardiography documented a granular-like myocardium. Bone marrow biopsy showed hyperplasia of the myeloid line at the expense of only the eosinophilic series, without phenotypic anomalies, without fibrosis and without evidence of neoplasia. Immunophenotyping of the bone marrow showed no evidence of lymphoproliferative disease. The search for genetic mutations (FIP1L1-PDGFR $\alpha$ , JAK2, BCR-ABL, FGFR1 and C-KIT) was negative. A diagnosis of idiopathic hypereosinophilic syndrome with pulmonary, cardiac and haematological involvement was established and the patient was treated with systemic corticosteroid therapy (prednisolone  $1$  mg/kg/day), with clinical and analytical improvement.

**Conclusion:** The diagnosis of HES can be complex and challenging, but should not be forgotten in patients with sustained peripheral hypereosinophilia and/or evidence of tissue hypereosinophilia. After exclusion of secondary causes requiring targeted treatment (such as parasitic infections), diagnostic investigation should be continued regardless of the presence or absence of symptoms. This evaluation implies a multidisciplinary approach in which the various specialties necessary to evaluate the potential multiorganization involvement must be involved, since virtually any organ can be affected.

With the present clinical case, the authors intend to demonstrate that Pneumology can play an important role in the diagnosis and orientation of patients with pathologies less frequent in daily clinical practice, such as HES.

**PE 046**

**STUDY OF CAUSES OF HEMOPTYSIS IN A DISTRICT  
HOSPITAL**

**E Alves, F González, A Castro, L Santos**

Centro Hospitalar Póvoa de Varzim/Vila do Conde

Key-words: Hemoptysis

**Introduction:** Hemoptysis is the expulsion of blood from the lower respiratory tract, most often in the form of a cough with blood or pulmonary secretion with blood. We analyzed a sample of 103 patients diagnosed with hemoptysis hospitalized at Internal Medicine and followed at the Pneumology consultation between January 2012 and June 2017.

**Objective:** To determine the main causes of hemoptysis in patients admitted to an Internal Medicine Service and Pneumology consultation.

**Results:** There was a predominance of males ( $n = 60$ , 58%), mean age of 63.9 years and 26.8% with active smoking and 16.5% ex-smokers. 81.4% of patients underwent bronchofibroscopy.

Infections were the main cause of hemoptysis (40%), most of them related to bronchiectasis (26%). The main non-infectious cause was neoplasms (26%), of which pulmonary neoplasia (20%) and pulmonary metastases (6%) were extra-pulmonary tumors. Bronchiectasis was the most frequent diagnosis in the internment of Internal Medicine and the neoplasias in the consultation of Pneumologia. The most frequent neoplasms were non-small cell carcinomas.

Regarding the volume, the small volume hemoptysis, diagnosed in 97.9% in the Pneumology consultation and 96.3% in the hospitalization of Medicine, were the most found.

**Conclusion:** The incidence of hemoptysis is influenced by several factors, including the geographic area of the study, as well as the institution where the research is carried out. In our case, hemoptysis continues to be an important cause of hospitalization and a reason to consult pneumology in a district hospital with a general internment in Internal Medicine and Pulmonology with only an outpatient department. The infectious causes in our sample were the most frequent, followed by the neoplasms. We can conclude that hemoptysis are a common and non-specific sign, occurring in a wide variety of diseases. The identification of the etiology of hemoptysis and its classification in relation to volume play a fundamental role in the definition of the treatment to be instituted and in the necessity or not of hospitalization. This manifestation always requires investigation, although the amount of blood eliminated is small.



PE 047

## MANAGEMENT OF PNEUMOTHORAX BY MEDICAL THORACOSCOPY: SMALL SERIES OF 5 CASES

E Seixas, P Ferreira, G Teixeira, A Saraiva

Centro Hospitalar do Baixo Vouga

Key-words: Pneumothorax, Medical thoracoscopy

**Introduction:** In cases of recurrent primary spontaneous pneumothoraces and inaugural secondary spontaneous pneumothoraces general consensus dictates that a recurrence prevention technique should be performed.

Thoracoscopic talc *poudrage* has already proven to be superior to the classic pleurodesis by talc slurry, with the additional advantage of providing endoscopic staging. Although Video-Assisted Thoracoscopic Surgery (VATS) was considered the *gold standard*, medical thoracoscopy with talc *poudrage* pleurodesis has already been shown as safe and effective procedure with recurrence rates similar to VATS, at least in Vandershuieren stages I and II. In addition, regarding recurrence risk bullectomy and apical pleurectomy still have a low level of evidence.

We present a description and characterization of the pneumothoraces managed by medical thoracoscopy in the last year, at the Pulmonology Department of Centro Hospitalar do Baixo Vouga.

**Results:** Five cases were found, three male and two female patients with a mean age of 31.2 years (SD±12.6 years). About 80% were active smokers and the average tobacco consumption was 20 pack-year. All patients were approached by semi-flexible thoracoscopy under conscious sedo-analgesia and spontaneous ventilation, performed by pulmonologists without anesthetist.

Of the five cases, four corresponded to primary spontaneous pneumothorax. Of these, three were recurrences, one with a small bronchopleural fistula, and the fourth one was a first episode also with a small bronchopleural fistula. All cases presented radiographically as free pneumothoraces. Endoscopically three of the cases were staged as Vandershuieren I and one as Vandershuieren III (subpleural blebs/bullae <2 cm). All cases underwent pleurodesis by talc *poudrage*.

The case of secondary spontaneous pneumothorax (underlying COPD) was an inaugural episode and presented as radiographically septated. It was staged as Vandershuieren III and was managed with intrapleural adhesiolysis and talc *poudrage*.

None of the patients had any complications during or after the procedure. Until the present date none of the cases relapsed, although the follow-up time is still short.

**Conclusions:** Medical thoracoscopy can offer definitive treatment in a large proportion of patients with pneumothorax. In this small series it proved to be an effective and safe technique, even in cases confirmed as Vandershuieren III and in cases with small bronchopleural fistulas, with no recurrence in any of the cases. In the near future, it is expected that medical thoracoscopy will become an increasingly used method for the treatment of pneumothorax.

PE 048

## PERSISTENT COUGH AND BRONCHIAL OBSTRUCTION, "A ROCK IN THE SHOE"

M Ramalho, V Sacramento, S Granadeiro, S Furtado

Pulmonology Department, Beatriz Ângelo Hospital, Lisbon

Key-words: Persistent cough, bronchial obstruction, bronchiolitis, rigid bronchoscopy

**Introduction:** The imagiological evidence of a bronchial obstruction in a patient with persistent symptoms must lead to an aetiological investigation and the exclusion of a cancer is important.

**Case report:** We present the case of a 68-year-old male, former civil locksmith (during 30 years), non smoker, with a known personal history of spinal fracture (L1-L3) in a work-related accident. He had no history of respiratory diseases, namely tuberculosis.

The patient was referred to a pulmonology consultation for complaints of dry cough, pharyngeal irritation and mMRC2 dyspnea, following a respiratory infection five months before.

From the complementary study that had been done, we underline a spirometry with obstructive ventilatory changes, with no response to bronchodilation (FEV1 57.6%, FEV1 / FVC 59.81) and a chest computed tomography (CT) suggestive of silicosis vs sarcoidosis (calcified adenopathic compromise with focal egg shell expression localized to almost all mediastinal and bilateral hilar lymph nodes). A new thorax CT was performed which additionally revealed a significant reduction in the caliber and irregularities in the lining of the segmental bronchial branches, with amputation of the internal basal segment of the right lower lobe and a peripheral homogeneous condensation area with a grossly macronodular configuration, more than 6.5 cm in diameter in the axial plane as well as a condensation with air bronchogram of the peripheral segments of the basal pyramid, and of the internal segment of the middle lobe. A bronchofibroscopy showed a marked decrease of the caliber of the main right and intermediate bronchus due to infiltrative aspects of the mucosa (atypia?, bronchial biopsies were inconclusive). To clarify those findings, a rigid bronchoscopy was performed, which confirmed the previously described mucosal infiltration where biopsies were executed and allowed for the repermeabilization of the intermediate bronchus by debulking. Three foreign bodies of stone consistency were identified as broncholiths, two of which were removed and a third probably aspirated.

Clinical improvement was obtained after the procedure. Neoplastic tissue was not identified in the bronchial biopsies but rather granulocyte infiltrate and colonies that were morphologically compatible with actinomyces so directed antibiotic therapy was started (cytology and Ziehl-Neelsen staining were negative and the bronchoalveolar lavage had no bacteriological isolation). The patient maintains follow-up in Pulmonology consultations with the diagnosis of silicosis and is nowadays asymptomatic.

**Discussion:** Bronchiolitis results from the presence of calculi in the bronchial tree almost always resulting from inflammatory or infectious processes that affect the hilar lymph nodes. We underline tuberculosis, aspergillosis, histoplasmosis, actinomycosis and nocardiosis as infectious causes and silicosis as a rare non-infectious cause of lithoptysis. Bronchiolitis manifests as cough, wheezing, hemoptysis and lithoptysis and recurrent pneumonia with identification of calcified endo or peri-bronchial lymph nodes on thoracic CT. With this case we emphasize the difficulty of the differential diagnosis of this pathology resorting to the clinical evaluation and imaging findings, with rigid bronchoscopy being key for both diagnosis and treatment.





PE 049

### OSTEOCHONDROPLASTIC TRACHEOPATHY IN PATIENT WITH STRIDOR: REPORT OF A CLINICAL CASE

T Abrantes, J Silva, J Correia, M Conceição, A Cunha, B Rodrigues, AS Torres

Centro Hospitalar Tondela-Viseu

Key-words: stridor; Tracheopathy; Chondroplastic; thyroid; trachea

**Introduction:** Osteochondroplastic Tracheopathy is a benign and rare condition, characterized by the presence of osteocartilaginous nodules, located mainly in the submucosa of the anterior and lateral walls of the trachea. As a general rule, it is asymptomatic and consists of an endoscopic or autopsy finding.

**Clinical Case:** Woman, 72 years, retired, previously domestic, non-smoker, with history of Hypertension, Obesity, Dyslipidemia, Hyperthyroidism, Pneumonia at 26 years. Chronically medicated with tiotropium, enalapril, atorvastatin and salbutamol in SOS. Complaints of wheezing, dyspnea, nasal obstruction and recurrent sneezing, with persistent seasonal worsening. Objective examination with slight inspiratory stridor. Thorax X-ray with tracheal deviation to the left and normo-positioned lower mediastinal column. Analysis without notable changes. Ventilatory function test with slight airway obstruction, air-trapping and positive broncho-dilatation test. Neck and thorax CT: nodule in the lower half of the right lobe of the thyroid, 28x31x43mm, smooth and well defined margins, partially calcified, conditioning slight contralateral deviation of the trachea. Bronchofibroscopy with bulging of the upper right wall with a reduction of about 50% of its lumen at this level and tracheal nodulariform pattern of hard consistency, sparing the membranous wall, until the bronchial emergence. Biopsies with signs of ossification of the lamina propria, probably translating osteochondroplastic tracheopathy. Cytology, tracheal brush, micro and mycobacteriology negative. Changed therapy for fluticasone and vilanterol, with improvement of dyspnoea and wheezing. Oriented to Surgery Consultation: after thyroid ultrasonography and aspiration puncture, it was concluded the existence of a benign follicular thyroid nodule and surgery was proposed. In this context, thyroid nodule was considered the most probable reason for stridor.

**Conclusion:** Treatment of Osteochondroplastic Tracheopathy is rarely necessary and surgery is restricted to cases of moderate to severe obstruction or complications such as recurrent infections. Despite the characteristic endoscopic findings, the biopsy allows the differential diagnosis of these lesions.

PE 050

### DIAGNOSIS AND ENDOSCOPIC TREATMENT OF TWO RARE ENTITIES

R Pereira<sup>1</sup>, G Fernandes<sup>2</sup>, A Magalhães<sup>2</sup>

<sup>1</sup>Serviço Pneumologia, Hospital de Braga; <sup>2</sup>Serviço Pneumologia, Centro Hospitalar São João

Key-words: endoscopic techniques; intravascular papillary endothelial hyperplasia; pseudoepitheliomatous hyperplasia

**Introduction:** Bronchoscopy and Rigid Bronchoscopy are endoscopic techniques that allow visualization of the bronchial tree, and are often crucial to obtain a definitive diagnosis. We report two cases in which bronchoscopy was important for the diagnosis and treatment of bronchial lesions.

**Case reports:** A 53 year old woman, active smoker (80 UMA). Personal history of AMI submitted to myocardial revascularization surgery (2015), hypertension and obesity. No respiratory symptoms. She performed chest CT at the request of the Assistant Physician, that revealed a polypoid lesion on the left wall of the trachea (medial region). Rigid bronchoscopy was performed, showing a polypoid lesion, about 1 cm long, at the junction of the posterior with the left lateral wall and at the level of the middle 1/3 of the trachea. The lesion was totally removed in block, the remaining examination did not show any changes. The anatomopathological result revealed a lesion with features of papillary pavement hyperplasia, without dysplasia - intravascular papillary endothelial hyperplasia (IPEH).

A 67 year old male, non-smoker, with tracheostomy placed after ischemic stroke due to left vocal cord hemiparesis (2004). Asymptomatic from the respiratory point of view. One finding in routine observation by Otorhinolaryngology was the presence of a lesion that occluded the tracheostomy cannula, and it was suspected that it was a granuloma. A bronchoscopy was performed and, on inspection, the presence of a granuloma was identified at the distal end of the cannula, which caused obstruction of the lumen in ~ 90%. Rigid Bronchoscopy was performed and laser photocoagulation was applied with almost total destruction of the granuloma. Biopsies of the lesion were performed. The anatomopathological result revealed a pseudoepitheliomatous hyperplasia (PEH).

**Discussion:** IPEH and PEH are two rare, benign and reactive conditions and generally with good prognosis. Its clinical and histopathological aspects may present similarities with malignant lesions, namely squamous cell carcinoma and angiosarcoma, respectively. The differential diagnosis with these entities is crucial, since they present a completely different treatment and prognosis.

PE 051

## TRACHEOBRONCHOPATHIA OSTEOCHONDROPLASTICA: THE "ROCK GARDEN" OF BRONCOLOGY

**T Oliveira, MI Costa, F Guedes, J Gomes, JP Braga**  
Centro Hospitalar do Porto

Key-words: Tracheobronchopathia osteochondroplastica. Benign pathology of the central airways. Fibreoptic bronchoscopy.

**Introduction:** The benign pathology of the central airways is a diagnostic challenge since it is often asymptomatic. Not infrequently, diagnosis happens as an incidental finding in the investigation of other respiratory pathologies. In these cases, respiratory endoscopy is fundamental in its diagnosis and characterization.

Two clinical cases of incidental bronchoscopic diagnosis of tracheobronchopathia osteochondroplastica (TO) are described.

**Clinical cases: Case 1:** 86-year-old woman with aortic biologic prosthesis and NYHA class II heart failure, antiaggregated with acetylsalicylic acid, with no known chronic pulmonary pathology or relevant inhalation exposure. Referred to outpatient consultation due to repeated small volume haemoptysis during 5 months. Chest computed tomography without relevant changes. Fibreoptic bronchoscopy (FB) was performed, showing a large number of submucosal nodules, especially at the beginning of the trachea. Nodule biopsy showed trabecular bone tissue, intertrabecular adipose tissue and cylindrical ciliated epithelium, compatible with TO. Remaining study without evidence of blood clots or recent haemorrhage. No new episodes of hemoptysis or respiratory symptoms happened during follow-up, thus the patient has been discharged from the outpatient consultation.

**Case 2:** 52-year-old man, ex-smoker (45 pack-years), former occasional *cannabis* consumer, retired carpenter, with clinical manifestations of chronic bronchitis, without directed medication. Admitted in the Porto Hospital Centre for subacute clinical manifestations of respiratory infection and constitutional syndrome with 6 months of evolution. Analytically with inflammatory syndrome and arterial blood gas analysis revealing acute hypoxemic respiratory failure. Radiography and computed tomography of the chest compatible with necrotizing pneumonia of the lower left lobe. Diagnostic FB was performed with observation of numerous scattered nodules on the anterior and lateral walls of the trachea, especially to the carina, without significant repercussion on the airway calibre, suggestive of TO. Microbiological and mycobacteriological examination of bronchial aspirate and bronchoalveolar lavage without isolation of infectious agents; cytological examination was negative for malignant cells. Empirically completed 20 days of amoxicillin/clavulanic acid and clindamycin, with favourable clinical, analytical and imaging evolution.

**Discussion:** TO is an uncommon and benign pathology of the central airways, more frequent in men between the fifth and seventh decades of life. Etiopathogenesis is controversial; a possible association with recurrent lower respiratory tract infections is described, as it potentiates bacterial colonization of the airways.

It is characterized by the development of multiple rock-garden-like cartilaginous and bony nodules in the submucosa of the anterior and lateral walls of the central airways, typically sparing the posterior membranous wall. FBFFB is the *gold standard* for diagnosis.

It is usually asymptomatic, requiring no treatment. However, depending on the degree of nodule projection for the lumen of the central airways, it may present with varied respiratory symptoms, obstructive respiratory physiology or even difficult airway, requiring endoscopic resection.

The incidental nature of the diagnosis in most of the described cases and the simultaneous occurrence with common obstructive pathologies or symptoms suggest that its incidence is underestimated. TO should always be contemplated in the differential diagnosis of the central pathology of the airways.





PE 052

### ENDOBRONCHIAL INVOLVEMENT OF LARGE B-CELL NON-HODGKIN'S LYMPHOMA

**CB Forte, M Guia, J Boléo-Tomé, F Rodrigues**  
Hospital de São Bernardo, Setúbal

Key-words: Large B-cell non-Hodgkin's Lymphoma, Endobronchial involvement

**Introduction:** Non-Hodgkin's lymphomas belong to a heterogeneous group of lymphoproliferative malignancies with differences in behavior, prognosis and recommended treatment. In most cases they may affect the mediastinum and the pulmonary parenchyma, the endobronchial involvement is extremely uncommon.

**Case Report:** A 56-year-old man, former smoker, went to emergency department after falling in the street with traumatism of the right upper limb, which resulted in an irreducible distal radius fracture. Proposed for elective surgery. In the pre-operative evaluation, the patient reported cough with hemoptysis, associated with fever, anorexia and weight loss (10 kg) in the last 2 months. Physical examination evidenced decreased vesicular breath sounds in the upper third of the right hemithorax. No palpable enlarged peripheral lymph nodes were found. The chest X-ray, revealed an opaque mass in the upper lobe of the right lung and elevation of the homolateral diaphragmatic hemi-cupula. The chest computed tomography scan revealed a large consolidation involving almost all segments of the right upper lobe, partial invasion of the right pulmonary artery, partial occlusion of the intermediate bronchus and extensive mediastinal adenopathies. The rigid bronchoscopy showed complete collapse of the right upper lobar bronchus by tumor, and obstruction of 70% of the intermediate bronchus lumen by a bronchial "cauliflower" mass. Biopsies of the tumor revealed a large B-cell non-Hodgkin's lymphoma, subtype "Germinal Center" (GC) (a rare morphological variant).

The patient was referred to the Oncology department, for a suitable therapeutic approach, with favourable clinical evolution.

**Discussion:** The clinical severity of malignant endobronchial lesions is correlated with the possibility of bronchial obstruction and subsequent pulmonary collapse. Patients usually present with nonspecific symptoms. Diagnosis is defined by bronchoscopy followed by the biopsy of the lesion. Treatment depends on the extent of the disease, as well as on the condition of the patient.

PE 053

### CT - GUIDED TRANSTHORACIC LUNG BIOPSY COMPLICATIONS: A PULMONOLOGY DEPARTMENT EXPERIENCE

**RE Gomes, M Barata, C Moreira, C Monge, JR Vieira, J Duarte**  
Hospital Garcia de Orta

Key-words: Fine needle aspiration, Core biopsy, Complication, Pneumothorax, Lesion

**Introduction:** computerized tomography (CT) - guided transthoracic diagnostic procedures are safe, effective and minimally invasive techniques used in the diagnosis of lung lesions, particularly lesions suspected of malignancy. Fine needle aspiration (FNA) and **core** biopsy (CB) provides material for cytological and histological examination, respectively, avoiding the need for more invasive procedures, such as thoracic surgery.

**Objectives:** the aim of the study was to evaluate the complication rate of both FNA and CB in pulmonary lesions suspected of malignancy as well as look over possible complication predictive factors.

**Materials and Methods:** patients submitted to CT-guided transthoracic lung biopsies, both AAF and CB between January 2015 and December 2016 in the Pulmonology Department of Hospital Garcia de Orta, were selected. Data related to patient gender, age, distance to the pleural layer, type of procedure, number of biopsies, presence of emphysema and complications after the procedures, were collected from patient's information sheets. Binary logistic regression was used in multivariate analysis of complications predictive factors.

**Results:** from the selected sample 81 procedures were included. From those, 33% performed CB, 61% FNA and 6% performed both procedures. The mean size of the observed lesions was 44mm with a standard deviation of 22.3 mm and the mean distance to the pleural layer was 6,3 mm with a standard deviation of 11,2 mm. Pneumothorax was the unique complication observed in 31% of the procedures (n = 25), of which, 6 (24% of the complicated procedures and 7,4% of the total of performed procedures) needed thoracic tube drainage. In multivariate analysis, distance to the pleural layer was the only predictive factor for the occurrence of complications ( $p = 0,011$ ), with pneumothorax.

**Conclusions:** the results were similar to the literature in almost every point, which supports the conclusions made out of this study, including those that correlate the distance to the pleura and the occurrence of complications. In the end, we concluded that complications occurred in one third of the procedures; that 7,4% of the procedures are complicated with severe pneumothorax with the need for thoracic tube drainage and that the distance between the lesion and the pleura is the only predictive factor for a complicated procedure, as a higher distance contributed to a greater complication rate.



PE 054

### MINERAL OIL ASPIRATION AS A DIFFERENTIAL DIAGNOSIS OF TAQUIPNEIA IN INFANTS

**BNL Silva, ND Neto, N Cyllio, LP Barbosa, N Navi, S Sias**  
Hospital Universitário Antônio Pedro - Niterói/RJ - Brasil

Key-words: Bronchoscopy; Tachypnea; Mineral oil

**Introduction:** Lipoid pneumonia caused by aspiration of mineral oil, unfortunately, is still a reality in our environment. Mineral oil, a substance derived from petroleum, is easily aspirated into the alveoli because it reduces the cough reflex, which can result in an important inflammatory process in the lower airways and, if in high doses, can cause death by suffocation.

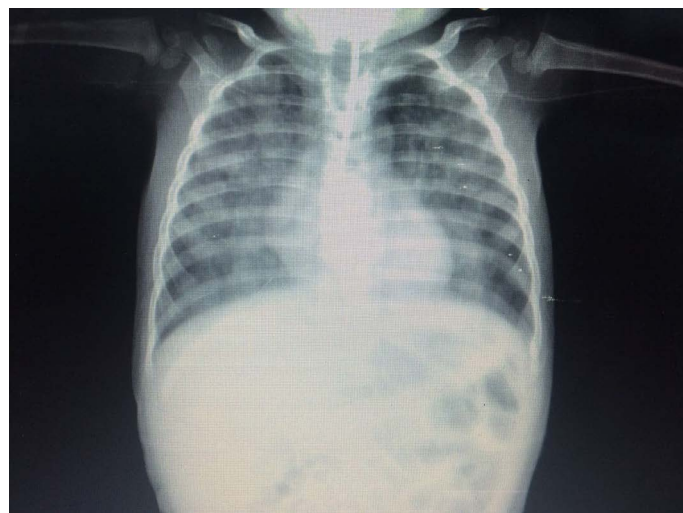**Objective:** to report a case of pneumonia due to aspiration of mineral oil, highlighting the malfunctions of this complication.

**Methods:** retrospective study with analysis of the medical record and participation of the person responsible for signing the ICF.

**Results:** A 9-month-old female infant is attended in a pediatric emergency in Niterói, Rio de Janeiro, Brazil, with a low fever for 5 days, tachypnea and respiratory effort. There was no general decline or change in appetite. There was no history of contact with acute respiratory diseases. The hemogram revealed left leukocytosis, increased CRP, and mild hypoxemia in arterial blood gas analysis. Chest X-ray presented hypotransparency in both lungs and peri-hilar infiltrate on the right. It was initially treated as bacterial pneumonia with 3 antimicrobial regimens, but did not result in radiological improvement, despite maintaining good general condition. High resolution computed tomography of the chest showed extensive consolidations in the posterior portions of the upper and lower lobes, bordered by frosted glass. There was a prior history of intestinal constipation, having used mineral oil daily (1 teaspoon) as laxative therapy. Flexible bronchoscopy with bronchoalveolar lavage (BAL) was performed, demonstrating opalescent material with supernatant fat halo, suggesting the clinical hypothesis of lipoidic pneumonia due to aspiration of mineral oil. The cytology of LBA showed high cellularity at the expense of foamy macrophages and the cytochemistry with Oil red was strongly positive, confirming the diagnosis of lipoidic pneumonia. The culture was negative. A treatment with serial bronchoalveolar lavages for the removal of mineral oil from the alveolar environment was proposed. Eight BALs were performed with clinical and radiological standardization.

**Discussion:** The diagnosis of Pneumonia Lipoidica is most often confused with pneumonia or tuberculosis, due to nonspecific symptoms. Only a high degree of suspicion in cases of treatment-refractory pneumonia, especially if there is clinical and radiological disagreement, as happened in the case reported.

**Conclusion:** Lipoid pneumonia requires a high degree of suspicion in children who present clinical radiological disagreement and history of mineral oil ingestion. The best treatment is the removal of mineral oil through bronchoscopy with bronchoalveolar lavage.







PE 055

### URINOTHORAX, A RARE CAUSE OF PLEURAL EFFUSION

**R Silva, J Correia, A Cunha, B Rodrigues, AS Torres**

Serviço Pneumologia – Centro Hospitalar Tondela Viseu

Key-words: urinothorax, Pleural effusion, obstructive uropathy

Urinothorax is a rare cause of pleural effusion, less than 70 cases are described worldwide. It usually results from obstructive or traumatic uropathy, more rarely it may appear after abdominal surgical procedures. The urinothorax, is the accumulation of urine in the pleural space and results from a rupture of the urinary tract that leads to an accumulation of urine in the retroperitoneal space and consequent migration of the urine into the pleural space. The diagnosis can be made by renal scintigraphy or by measuring creatinine levels in the pleural fluid.

We present a clinical case of a patient with an urinothorax.

**Case report:** A 74-year-old male patient, hospitalized with an acute kidney injury in the context of an obstructive uropathy. The patient had a history of bladder urothelial tumor with several surgical interventions. He presented with anorexia, nausea and vomiting, uremic breath, hypertension. Analytically he had creatinine 20.9 mg / dl, urea 315 mg / dl, Na + 137; K + 7.4. Hemodialysis were started and he was transferred to the Urology department. Due to bilateral pelvicalyceal dilatation, he was submitted to bilateral nephrostomy. The preoperative chest radiography showed a pleural effusion on the right. The assistant doctor contacted the pneumology department. A thoracentesis was performed and since the pleural liquid had a macroscopic appearance compatible with urine, creatinine clearance in the pleural fluid was requested. He was diagnosed with an urinothorax because he had a pleural creatine higher (6.4 mg / dl) than the serum creatinine value (4.2 mg / dl). The patient underwent a new teleradiography showing a significant improvement of the pleural effusion. The patient eventually died 2 months later due to complications related to his bladder tumor.

**Discussion:** The urinothorax should be included in the differential diagnosis of pleural effusion. Respiratory symptoms are not always present and creatinine clearance in pleural fluid and serum establishes the diagnosis. It is more common in the course of obstructive uropathy, but may also result from urinary tract disruption. Urinothorax occurs by urinary lymphatic rise to the chest or, in the case of urinary tract disruption, by extravasation of urine from the retroperitoneal space into the pleura.

In this case the urinothorax may have occurred due to the two mechanisms since the patient besides having obstructive uropathy was also submitted to percutaneous nephrostomy.

Urinothorax is a rare condition, but it should be kept in mind since early diagnosis may improve the outcome of the patient. This pathology can easily go unnoticed. Thus, in patients with obstructive uropathy and pleural effusion the pathology should be equated. These patients should be approached, as in this case, by a multidisciplinary team including a pulmonologist and an urologist.

PE 056

### THORACIC ENDOMETRIOSIS, A RARE CAUSE OF HAEMOTHORAX

**AR Costa, J Silva, R Barata, J Reis, P Calvino, J Fragata**

Hospital Santa Marta

Key-words: Thoracic endometriosis, haemothorax, chemical pleurodesis, VATS

Thoracic endometriosis is a rare condition characterized by the presence of endometrial tissue in airways, pleura and lung parenchyma. As it presents with multiples forms, the diagnosis is challenging and often delayed. Haemothorax represents only 14% of the cases, and this condition must be considered in the differential diagnosis of non-traumatic causes of intrathoracic haemorrhage. We describe the case of a 44 year old woman with previous history of endometriosis diagnosed by laparoscopic biopsies in August 2012, during the study of a hematic pleural effusion and peritoneum nodules thought to be peritoneal carcinomatosis. With recurrent haemothorax, during menstrual cycle, a presumptive diagnosis of thoracic endometriosis was made. She started hormone therapy with clinical stability for 4 years.

At the beginning of 2016, the patient suspended the hormone therapy, and 1 year later she had two new episodes of right haemothorax. The patient restarted hormone therapy. Pleural biopsies and chemical pleurodesis with talc by video-assisted thoracic surgery (VATS) were performed. The anatomopathological examination confirmed the presence of pleural endometriosis.

Hormone therapy is crucial to systemic control of the disease. Surgery as a diagnostic and a therapeutic role in this matter, as it confirms the diagnosis and allows occlusion of the pleural space. VATS provides a minimal invasive local control, with chemical pleurodesis as well as with pleurectomy. In this case, because of high risk of bleeding in an anaemic patient, we choose to perform a chemical pleurodesis which proved effective.



PE 057

### **PLEURAL EFFUSION - AN UNEXPECTED CAUSE**

**AL Fernandes<sup>1</sup>, M Bibi<sup>2</sup>, A Vanconcelos<sup>2</sup>, J Ferreira<sup>1</sup>, I Neves<sup>1</sup>**

<sup>1</sup>Pulmonology Departement, Unidade Local de Saúde de Matosinhos;

<sup>2</sup>Internal Medicine Departement, Unidade Local de Saúde de Matosinhos

Key-words: pleural effusion, pleural manifestation, AA amyloidosis

**Introduction:** Amyloidosis is defined as a group of heterogeneous diseases characterized by extracellular deposition of an abnormal and insoluble fibrillary protein in different organs or tissues. Pleural effusion is an infrequent pulmonary manifestation and usually is associated with primary amyloidosis (AL).

**Clinical Case:** Female, 63 years old, retired, non-smoker, with a history of breast cancer submitted to radical mastectomy, chemotherapy and radiotherapy 14 years ago, depression and chronic anaemia in study. No relevant family history.

The patient was admitted to the Emergency Department due to a 5-month history of gradual weight loss, anorexia and asthenia. Additionally, for the last 2 weeks the patient referred the appearance of exertional dyspnea and lower limb edema. She also reported episodes of diarrhea during the last month. The physical examination showed reasonable general condition, discolored mucous membranes and symmetrical peripheral edema in the lower limbs. Pulmonary auscultation revealed decreased breath sounds on the inferior half of the left hemithorax. Laboratory tests demonstrated normocytic and normochromic anaemia, normal leukocytes count and elevated C-reactive protein. The chest radiograph showed homogeneous opacification on the inferior half of the left hemithorax, compatible with pleural effusion. A diagnostic thoracentesis revealed the presence of a sero-hematic fluid, with exudate characteristics and with mononuclear predominance. Pleural fluid study had a normal ADA value and was negative for malignancy or infection. Pleural biopsy was positive for Congo Red staining, which was compatible with amyloidotic pleural involvement, and amyloid A protein was identified. Further diagnostic search was carried out in order to identify secondary causes. Recurrence of neoplastic disease was excluded. As the patient complained about diarrhea and because of her prior anemic status, endoscopy and colonoscopy were performed. The latter revealed pleomorphic ulcerated lesions interspersed with areas of spared mucosa from the cecum to the transverse colon. The colic biopsy showed a fibrino-leukocytic exudate, without granulomas. No microorganisms or malignant cells were identified. Taking into account the pathological findings and positivity of Anti-Saccharomyces cerevisiae antibodies (ASCA), it was assumed the diagnosis of Inflammatory Bowel Disease. The patient was started on mesalazine and systemic corticosteroids, with no worsening of the pleural effusion.

**Conclusion:** The authors describe this case report because of its infrequency and to illustrate how the search of amyloid substance in the pleura was decisive for the diagnosis.

PE 058

### **PSEUDOTUMOR OR FIBROUS TUMOR OF THE PLEURA, THAT'S THE QUESTION**

**M Baptista, J Barata, R Silva, MJ Valente, E Magalhães, I Vicente, MS Valente**

Serviço de Pneumologia - Centro Hospitalar Cova da Beira

Key-words: fibrous tumor pleura, pseudotumor, encysted effusion

**Introduction:** The solitary fibrous tumor of the pleura is a rare tumor of fusiform cells of mesenchymal origin. It's asymptomatic in half of the cases and the radiographic features are non-specific, therefore the definitive diagnosis depends on the histological and immunohistochemical study after surgical resection. These tumors are mostly benign, but recurrence is frequent and sometimes late.

**Clinical case:** A 63-year-old woman was referred to pulmonology consultation by the attending physician because of an altered chest radiograph. The image revealed a lenticular opacity in the middle third of the left lung field (Fig.1). The patient was asymptomatic and there were no relevant changes on physical examination.

History of hypertension, endometrial polyp and uterine leiomyoma. Medicated with irbesartan/hydrochlorothiazide and clorazepate dipotassium. Ex-smoker of 30 pack-year, stopped 12 years ago. Without relevant exposure, including to asbestos, but with a heavy family history of oncological disease: mother with uterine cancer, sister with breast cancer and her father died with lung cancer.

Laboratory studies were normal, including blood count and inflammatory parameters. The pulmonary function tests were also normal. The thoracic CT report described a dense opacity in the upper wing of the left pulmonary fissure, with approximately 38 mm, regular and well defined limits and low contrast uptake, thus having the characteristics of a pseudotumor due to encysted pleural fluid (Fig.2).

By reviewing old chest radiographs, it was possible to identify an opacity at the same location but with smaller dimensions and there were no evidence of free pleural effusion. Based on this the study of the lesion proceeded, culminating with surgical resection. CT-guided transthoracic aspiration biopsy revealed only normal lung parenchyma. PET-CT showed hypercaptation of F-18-FDG located in a large area of densification near the oblique fissure of the left lung, aspect more suggestive of malignant etiology.

Was performed a surgical wedge resection of a fibrous mass apparently dependent of the visceral pleura of the left superior lobe. Histology revealed fusiform cells with mild pleomorphism, hyper and hypocellular areas, necrosis in 30% of the tumor and only 1 mitotic figure /10 HPF. Immunohistochemical analysis showed cells positive for Vimentin, CD34 and progesterone receptors, but negative for pS100, HHF35, alfa-actin of smooth muscle, CD68, CD31 and ALK. This characteristics allowed the final diagnosis of fibrous tumor of the left lung fissure. The patient remains asymptomatic and should maintain follow-up every six months for 2 years, and then annually.

**Conclusion:** In this clinical case the CT report pointed to a pseudotumoral lesion due to intercostal effusion. The growth of the lesion in the absence of free pleural effusion raised the clinical suspicion of a real tumor.



Complete surgical resection is the recommended treatment for fibrous tumor, but long-term follow-up should be maintained because of the risk of recurrence. The macroscopic, microscopic and immunohistochemical characteristics of the tumor help to predict the risk of malignancy and recurrence, and thus adjust the follow-up scheme.

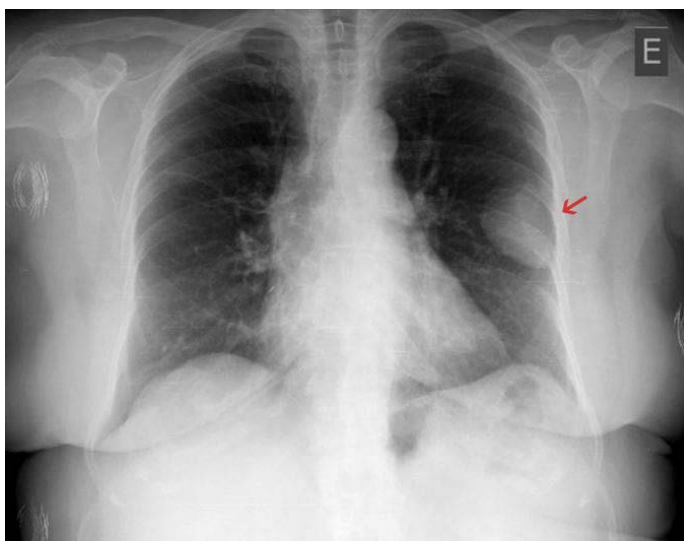

Fig. 1

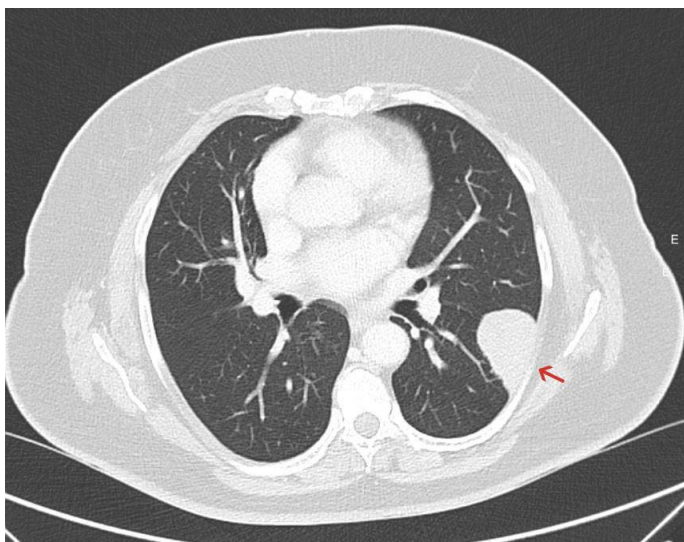


Fig. 2

PE 059

### INTRAPLEURAL INSTILLATION OF FIBRINOLYTICS AND DNASE IN PLEURAL INFECTIONS - IS THIS AN OPTION? - TWO CLINICAL CASES

NC Pereira, I Sucena, D Coutinho, C Ribeiro, M Vanzeller, T Shiang  
Centro Hospitalar Vila Nova de Gaia/Espinho

Key-words: pleural infections, DNase, alteplase

The incidence of pleural infections has increased significantly in the last years, being associated with a considerable morbimortality rate and health costs. The mortality rate in these infections is estimated to be 10 to 20% and about 30% of patients that begin with standard therapy will need surgical approach *à posteriori*. Recent evidence suggests that combined intrapleural instillation of fibrinolytics and DNase improve the pleural drainage as well as a reduction in the duration of hospital stay and the frequency of surgical referral.

The authors present two cases of intrapleural fibrinolytics/DNase in pleural infections. The first case refers to a 65 years-old, smoker (50 pack-year) patient, with previous diagnoses of pulmonary tuberculosis and bronchiectasis. The patient was admitted at hospital under the diagnoses of severe sepsis caused by community acquired pneumonia (CAP). Started amoxicillin/clavulanate and azithromycin empirically. At 4<sup>th</sup> day of hospital stay because of clinical and imagiological poorest status, with new ipsilateral pleural effusion, the antibiotic coverage was enlarged (piperacillin/tazobactam and vancomycin) and pleural effusion was managed by thoracocentesis - empyema features. A chest tube (Jolly nº18) was placed. The patient had sustained fever and analytic aggravation, and pleural effusion become smaller but multiloculated. By the 18<sup>th</sup> day the antibiotic was changed to imipenem, clindamycin and linezolid and the intrapleural instillation protocol was started with the association of fibrinolytic and DNase - alteplase 10mg twice-a-day and dornase alfa 5mg twice-a-day for 3 consecutive days. Since then the patient was presented with better clinical and imagiological status, with chest tube pulled off. Patient was referred to respiratory rehabilitation program.

In the second report a 63 years old patient was presented, with no longer smoke habits (40 pack-year) and with COPD. He was admitted to the hospital with CAP associated with empyema. A chest tube (Jolly nº 18) was placed and ceftriaxone and azithromycin was started. During the hospital stay the patient presented worst clinical and analytic features with pleural effusion sustained. The CT Chest exposed a loculated pleural effusion with enlarged pleural leaflets. At 10<sup>th</sup> day the antibiotic was changed to piperacillin/tazobactam and clindamycin and the intrapleural instillation protocol was started with the association of fibrinolytic and DNase - alteplase 10mg twice-a-day and dornase alfa 5mg twice-a-day for 3 consecutive days. It's important to make notice of the pain felt by the patient during the instillation. Since then a clinical improvement occurred - afebrile status and correction of hypoxemia, but the left costofrenic angle was still obliterated. The chest tube was pulled off after 5 days of the instillation. The patient was discharged and the respiratory rehabilitation was maintained at outpatient care.

With the pleural infections becoming more and more often and with the improvement of surgical technique, there was an increase of the number of patients submitted to surgical approach. These two cases revealed a more conservative approach (fibrinolytic/DNase instillation) with hospital stay time gain and becoming the surgery not being need. The aim was highlight this procedure in patients where the medical treatment failed and have no surgical conditions.

PE 060

**RECURRENCE OF PULMONARY TUBERCULOSIS: A 10-YEAR RETROSPECTIVE STUDY IN A UNIT SPECIALISED IN THE MANAGEMENT AND TREATMENT OF TUBERCULOSIS IN PORTUGAL**

**PI Pedro, A Freire, C Barroso**

Hospital Garcia de Orta, Centro de Diagnóstico Pneumológico de Almada

Key-words: relapse, pulmonary tuberculosis

Portugal is a country with a low-to-intermediate incidence of tuberculosis (TB), with most cases concentrated in the metropolitan areas of Porto, Lisbon and Setúbal districts. Rates of relapse or recurrence of TB reflect the long-term efficacy of TB treatment, the effectiveness of the TB control strategy, the underlying incidence of TB in the community and the immune status of the community. Relapse of active TB following treatment of an initial disease episode can occur due to endogenous re-activation or exogenous re-infection. Rates of relapse of TB in settings with a low-to-intermediate incidence of TB are reported to range 1,2-7,0%.

The aim of this population-based retrospective observational study was to estimate the rate of relapse of pulmonary TB in a unit specialised in the management of TB and characterize the study cohort. The unit treat patients living in Almada and Seixal, at the district of Setúbal.

Patients were included in the analysis if, between January 1<sup>st</sup> of 2006 and December 31<sup>st</sup> of 2016, they presented relapse/recurrence of pulmonary TB, which means that they had to be notified with a bacteriologically confirmed pulmonary TB episode and, previously during their lives, they had at least other episode of confirmed pulmonary TB for which they completed treatment. There were 770 notifications of pulmonary TB between 2006 and 2016, 248 of which were bacteriologically confirmed cases. Six (2,4%) of these were a relapse of the disease.

The mean age of the study population was  $40,8 \pm 3,7$  years, and 83,3% of the patients were male. Three patients were emigrants from African countries. Three patients were unemployed; and 2 were ex-offenders. Five had active/former drug addiction; and 2 were active/former alcoholics. Three patients were HIV-1 positive. The second disease episode occurred between 23-113 months (median 37,5 months) after the initial disease episode.

There was one case of multidrug-resistant tuberculosis (MDR-TB) and other one with isoniazid monoresistance in the recurrence episode, with the strains of the remaining patients being sensitive to first-line drugs.

In conclusion, a low rate of pulmonary TB relapse/recurrence was observed in our study (2,4%). The authors consider that the consistent application of a control programme incorporating directly observed therapy (DOT) for active disease in the unit may be at least partially responsible for the good outcomes.

Solely one patient relapsed during the recommended 2 years of follow-up after finishing therapy, contradicting previous studies that showed a higher rate of relapse during this period.

There was only one case of MDR-TB in the second episode of disease, which is consistent with the fact that relapse of TB is most likely to occur with drug-susceptible organisms, as previously demonstrated.

The genotyping of the mycobacterial strain would clarify the proportion of cases attributable to re-activation or re-infection by the disease.

PE 061

**TUBERCULOSIS - RETREATMENTS FROM 2000 TO 2015 IN CDP SANTARÉM**

**MC Cafede, G Henriques, JM Carvalho**

Centro de Diagnóstico Pneumológico de Santarém

Key-words: Tuberculosis, relapse, retreatment

Tuberculosis is a treatable and manageable disease but there are some factors which are known to lead to relapses and repeated treatments. In order to evaluate our experience and to characterise the population of patients which were subject to repeated treatment in a period of 16 years (2000-2015), we revised the files at CDP Santarém. Comparisons are made with the general population of patients, based on SVIG-TB records. These data are presented in between straight parenthesis.

From a pool of 1004 patients subjected to tuberculosis treatment, 940 were new cases (93.6%) and 64 were repeated treatments (6.3%). This group was divided in 50 cases (78.1%) of repeated treatments after previous completed one, and 14 cases (21.9%) after treatment interruption.

The predominance in males subjects, 49 cases (76.6%), is greater than in the general population of patients (66.8%). We observed an average of patient ages of 53 years [48], a minimum of 28 and a maximum of 95.

The pulmonary presentations are predominant with 68.8% [62.3%], while 39.1% [43.3%] are extrapulmonary (isolated or not). The proportion of cases with confirmation, in the pulmonary presentation, was of 72.7% [70.6%] using direct examination and 70.5% [66.3%] using culture.

Multidrug resistance was mainly detected in repeated treatments: 7 cases (22.6% of those tested) [10 (2.7% of those tested)].

Concerning associated pathologies, AIDS appears in 23 cases (35.9%), with significant difference towards the whole sample population [13%], as well as drug addiction - 20 cases (31.3%) [15%]; diabetes type II is associated with 7 cases (10.9%) [8.7%] and renal impairment in one case (1.6%) [1.4%].

Other related risk factors are alcohol addiction in 13 cases (20.3%) [11.2%] and prison incarceration in 3 cases (4.7%) [3.7%], amongst others.

The time lapsed between previous and actual diseases varies from one to 53 years, with an average of 17 years.

The therapeutic success was of 78.1% [90.1%], with 10 deceased (15.6%) [7.9%] and 3 abandons (4.7%) [1.1%].

**Conclusions:** in our sample drug and alcohol addictions as well as AIDS are main risk factors for tuberculosis retreatments.



PE 062

## **LATENT TUBERCULOSIS TESTING - THE CHANGING PARADIGM**

**MC Morais, LMCA Almeida, SL Santos, J Cunha, C Silva, E Coutinho**  
Laboratório do Centro de Diagnóstico Pneumológico (CDP) do Porto,  
ACeS Porto Ocidental, ARS Norte

Key-words: latent tuberculosis infection, LTBI, Mycobacterium tuberculosis, interferon gamma release assays IGRA

**Introduction:** "Latent tuberculosis infection (LTBI) is defined as a state of persistent immune response to stimulation by *Mycobacterium tuberculosis* (*Mtb*) antigens without evidence of clinically manifested active tuberculosis (TB)" [1].

Since the global burden of LTBI was estimated, in 2014, to be 1.7 billion, just under a quarter of the global population was at risk of developing active TB infection [1, 2].

Management of LTBI in people with a high risk of developing active TB has been proposed particularly in low tuberculosis-incidence countries [3]. Addressing the LTBI reservoir is critical to achieving TB elimination by 2050, a worldwide goal set by the WHO [2, 4].

In the last decade, interferon gamma (IFN- $\gamma$ ) release assays (IGRAs) have been introduced to detect LTBI. IGRAs detect the release of IFN- $\gamma$  upon stimulation with *Mtb*-specific antigens (ESAT-6, CFP-10), in blood drawn from infected individuals [1, 2].

**Objectives:** i) To assess the evolution of LTBI diagnosis by IGRA methodology between 2008 and 2017 in our laboratory; ii) To assess the results of the QuantiFERON-TB Gold Plus (QFT-Plus, QIAGEN GmbH) from July 2016 until June 2017 and their incidence within the vulnerable groups and the different age-groups.

**Methods:** We calculated the total IGRA tests/year and the mean tests/month between June 2008 and July 2017. A total of 7665 samples, drawn from 57.9% (n=4438) female and 42.1% (n=3227) male patients, were analysed with QFT-Plus Kit, between July 2016 and June 2017. The results are reported as negative (neg), positive (pos) and indeterminate (ind).

PEarson's correlation coefficient was used to validate differences in frequencies with the QFT-Plus results. Values <0.05 were considered statistically significant.

**Results:** Overall, between 2008 and 2016 the IGRA testing increased from 320 to 6026 tests. In the first semester of 2017, 4060 samples were tested for IGRA with a mean of 763 tests/month.

Concerning the 7665 samples analysed with QFT-Plus Kit, we observed that 76.6% (n=5872) samples were negative; 21.9% (n=1681) and 1.5% (n=112) produced positive and indeterminate results, respectively.

The results from the five vulnerable groups were as follows: immunocompromised (n=2157, neg=78.4%, pos=18.3%, ind=3.3%); screening (n=4425, neg=75.2%, pos=24.0%, ind=0.8%); drug addiction (n=25, neg=56.0%, pos=44.0%, ind=0.0%); health workers (n=945, neg=81.5%, pos=17.8%, ind=0.7%), other risk groups (n=113, neg=60.2%, pos=38.9%, ind=0.0%) [ $p<0.001$ ].

We observed an age distribution from 6 months to 98 years (y) (mean=41.8y; median=42y). The results within the age-groups were as follows: 0-9y (n=492, neg=88.4%, pos=10.0%, ind=1.6%); 10-18y (n=409, neg=78.5%, pos=20.8%, ind=0.7%); 19-29y (n=1126, neg=80.5%, pos=18.6%, ind=1.0%); 30-69y (n=5096, neg=75.3%, pos=23.5%, ind=1.2%);  $\geq 70y$  (n=542, neg=68.6%, pos=25.8%, ind=5.5%) ( $< 0.001$ ).

**Discussion:** Screening was the most prevalent clinical information among younger groups ( $\leq 29y$ ), while among the older groups ( $> 30y$ ), the most prevalent clinical information was "immunosuppression", although a significant number of screening was also observed. In this study the samples were drawn from a high risk population which introduced bias. However, the identification of the 21.9% of LTBI cases is just below the global LTBI burden estimated in 2014.

### **Bibliography:**

1. WHO, Guidelines on the management of LTBI, 2015.
2. Houben, R.M.G.J., PLoS Med, 2016. **13**(10).
3. WHO, The END TB Strategy, 2014.
4. WHO, TB report 2016 - Executive Summary, 2017.



PE 063

### **PULMONARY TUBERCULOSIS (PT) IN A PULMONOLOGY WARD - 5 YEAR OBSERVATIONS**

**M Barata, T Martín, R Gomes, H Grumete, J Duarte**  
Hospital Garcia de Orta

Key-words: Tuberculosis, Clinical presentation, Resistances.

**Introduction:** The incidence of tuberculosis (TB) has been decreasing consistently in the recent years in Portugal however this incidence is still significant in Oporto, Lisbon and Setúbal districts. The early diagnosis and effective treatment of the new cases are key aspects to control the disease. The aim of this study was to evaluate patients admitted with PT in the pulmonology ward of the Hospital Garcia de Orta (HGO).

**Methods:** Observational, descriptive, retrospective study with patients admitted with PT during 5 years (2012-2016). The patients were selected in this period with the diagnosis according to ICD - 9 of PT, available record files and isolation in culture of Mycobacterium tuberculosis. Variables collected were: demographic factors, clinical presentation, extra pulmonary tuberculosis (EPTB) presence, risk factors to multiresistance (MR) TB, antibacilar susceptibility test (TSA), hospitalization duration and mortality.

**Results:** 50 (n) patients were admitted during the period of study, 41 (82%) men and 9 (18%) women, with an average age of 49 ± 17 years. 36 patients (72%) were active smokers. The most frequent clinical presentations were productive cough (84%), weight loss (78%), asthenia (60%), night sweats (36%) and fever (36%). 35 (75%) patients had radiologic findings of cavitary pulmonary images. 11 patients had also EPTB: 2 patients had pleural and intestinal TB, 5 patients pleural TB, 1 intestinal TB, 1 bone TB and 1 meningeal TB. In evaluation of risk factors to MR TB, 9 patients were immigrants from countries with high prevalence of MR TB, 5 patients had previous history of treated TB, 5 patients were drug addicted and 4 patients were in contact with a person with MR TB. All of the patients were HIV negative. The TSA revealed 5 patients with monoresistance, 7 patients with poli-resistance and 1 patient with multiresistance. The median time of hospitalization was 43 (22 - 65) days. 5 (10%) patients died during the hospitalization.

**Conclusion:** The greatest proportion of admitted patients with PT were men. We should suspect of PT in patients with symptoms like productive cough, weight loss, asthenia, and pulmonary cavitation. 11 patients had also EPTB, principally pleural TB, despite of being HIV negative. The presence of resistances enhances the importance of conducting TSA or other resistance tests.

PE 064

### **BREAST TUBERCULOSIS - A RARE EXTRA-PULMONARY PRESENTATION**

**M Barata, A Castro, MC Gomes**  
Centro de Diagnóstico Pneumológico Dr. Ribeiro Sanches

Key-words: Tuberculosis, Breast, Antibacilar therapy

Breast Tuberculosis (TB) is a rare presentation of extra-pulmonary localization which accounts for less than 0.1% of breast conditions in developed countries. It appears mostly in women of reproductive age, multiparous or lactating. The differential diagnosis includes breast cancer and abscess formation.

The authors are presenting a case of breast and pulmonary TB. An 84 year old retired Portuguese woman that had worked all her life as a farmer recurred to the ER with breast pain and morning productive cough, symptoms she had been experiencing for 2 months. She denied previous and familiar history of TB, denied recent travels to countries with high incidence of TB. In objective examination she had a breast abscess that was drained. Of the complementary study: direct exam positive to BAAR, positive exam to Mycobacterium tuberculosis (MT), isolation of MT in culture, sensible to Rifampicin and Isoniazid. She was forwarded to CDP. In CDP, a direct and cultural sputum exam was performed and tested negative. In addition, she undertook a thorax CT that revealed: "Subcarinal lymphadenopathy with 30x25 mm and slightly inferior lymphadenopathies in high number, pre carinal in the right and left hemithoraxes and right superior para-tracheal. Residual findings in right apical and posterior segment of superior right lobe."

She started combined therapy with HRZE with direct intake observed. One week after the beginning of the therapy she referred generalized pruriginous exanthema, without any response to anti histaminic therapy.

The antibacilar therapy was suspended after two weeks in the light of her condition's improvement. She then began the process of desensitization to antibacilar therapy with tolerance to all of the 4 drugs, without adverse reactions. She is currently in the initial step of antibacilar therapy.

This case shows a rare presentation of extrapulmonary TB. Changes are being observed in the age of incidence of TB. On the other hand, this case highlights the importance of the recognition and handling of the adverse effects of antibacilar therapy.





PE 065

### TUBERCULOUS OTITIS MEDIA: A REMINDER OF AN IMPORTANT CLINICAL LESSON

ME Brandão<sup>1</sup>, D Machado<sup>2</sup>, MA Galego<sup>3</sup>, F Calvário<sup>4</sup>, C Nogueira<sup>2,4</sup>, I Ladeira<sup>2,4</sup>, R Duarte<sup>2,4</sup>, A Carvalho<sup>2,4</sup>

<sup>1</sup>Serviço de Pneumologia do Centro Hospitalar de Trás-os-Montes e Alto Douro, EPE; <sup>2</sup>Serviço de Pneumologia do Centro Hospitalar de Vila Nova de Gaia/Espinho, EPE; <sup>3</sup>Serviço de Pneumologia do Hospital Pedro Hispano, ULS Matosinhos, EPE; <sup>4</sup>Centro de Diagnóstico Pneumológico de Vila Nova de Gaia

Key-words: Pulmonary Tuberculosis; Mycobacterium tuberculosis; Otitis media

**Background:** Tuberculosis (TB) is one of the most ancient infectious diseases afflicting humans and still poses considerable challenges for clinicians given its wide spectrum of clinical manifestations. In the management pulmonary TB, the pulmonologist should be alert to systemic manifestations that may represent rare forms of extra-pulmonary disease. Hereby, the authors present a case of TB affecting middle ear and lung in an otherwise healthy man, to enlighten the clinical characteristics of tuberculous otitis media (TOM) and its diagnostic challenges.

**Case presentation:** 40 year-old male, admitted to the Emergency Department (ED) with productive cough, low-grade intermittent fever, anorexia and unintentional weight loss. He was primarily diagnosed with Community-Acquired Pneumonia and treated with empiric antibiotic therapy. Two months later, he returned to the ED, due to lack of improvement of respiratory complaints. He also reported a 11-month history of recurrent right-sided otorrhea, otalgia, tinnitus and progressive hearing loss, despite multiple courses of oral antibiotics for chronic otitis media. Otoscopic examination revealed purulent discharge in the right external auditory canal, with preserved tympanic membrane. On pulmonary auscultation there were crackles over right upper and middle lobes. The laboratory studies showed anemia and elevated Serum C-reactive protein. HIV serology was negative. The chest x-ray revealed multiple bilateral ill-defined opacities with cavitation areas in the upper lobes. Three sputum smears found acid fast bacilli (AFB) with Polymerase Chain Reaction test (PCR) positive for *Mycobacterium tuberculosis* (MT) specific-DNA. Subsequent sputum culture grew MT. *Ziehl-Neelsen staining* of the ear discharge showed AFB and PCR was also positive for MT, thus confirming the diagnosis of disseminated TB. Standard four-drug anti-tuberculous regimen was started with significant clinical and radiological improvement at the two-month re-evaluation.

**Discussion:** The involvement of middle ear by TB accounts for less than 1% of extra-pulmonary TB cases and most clinicians are unfamiliar with the diagnosis. Two valuable learning points can be derived from this case. Firstly, this case exemplifies how TOM can closely mimic the more common nontuberculous otitis media and be unrecognized for long periods. The presence of respiratory and constitutional symptoms finally pointed to the diagnosis. Obtaining microbiological confirmation can be difficult because acid fast bacilli counts in ear discharge are typically low and often require multiple cultures or surgical biopsy. Thus, to make the correct diagnosis, a thorough history and keeping a high index of suspicion is paramount. This case also highlights the importance of excluding pulmonary involvement in all patients with TOM. Chest X-ray, sputum for AFB culture and smear should be routinely performed and may reveal advanced pulmonary disease even in the absence of respiratory symptoms.

PE 066

### CEREBRAL AIR EMBOLISM - CASE REPORT

D Maia, A Teixeira, R Coelho, L Amado, J Cardoso

Serviço de Pneumologia e Unidade de Cuidados Intensivos Polivalente do Hospital de Santa Marta, Centro Hospitalar de Lisboa Central

Key-words: Air embolism, central venous catheter, hyperbaric oxygen therapy

**Introduction:** Although scarcely described in the literature, cerebral air embolism is a known complication of various medical procedures, including central venous catheterization. Neurologic sequelae can be very significant. A recent review described mortality of 20%.

**Clinical case:** We describe the case of a female patient, 74 years old, previously autonomous in activities of daily living and with a history of smoking. There was no regular medical follow-up or usual medication. She was transferred to the Respiratory Ward (RW) from a General Intensive Care Unit (GICU) after admission due to ischemic stroke (CVA) with left hemiparesis, to investigate previously unknown respiratory insufficiency. She developed nosocomial pneumonia and needed invasive mechanical ventilation (IMV). Therefore, she was transferred back to GICU. After her recovery, the patient was transferred to the RW again, maintaining the previous neurological state and respiratory failure under oxygen therapy. During hospitalization, she developed sudden depression of the state of consciousness and desaturation. On examination, she was unresponsive with a total score of 3 in the Glasgow Coma Scale but hemodynamically stable. The electrocardiogram showed no signs of ischemia. The patient underwent urgent brain CT that revealed gas embolism, with the right jugular central venous catheter (CVC) assumed as the starting point. Transthoracic echocardiography excluded intracardiac shunt. She was treated with IMV with hyperoxia and CVC was removed followed by hyperbaric oxygen therapy. The treatment (table 6USN) was started approximately 7 hours after the onset of symptoms and was uneventful. After ventilatory weaning and extubation, the patient kept a normal cognitive state and left hemiplegia. Regarding the respiratory system, the patient was not able to perform pulmonary function tests and long-term oxygen therapy was prescribed. She was discharged with maintenance of intensive motor rehabilitation program.

**Discussion / Conclusion:** The authors intend to alert to this rare complication that can mimic stroke but frequently there is a severe vigilance disturbance. In this case the relationship between CVC manipulation and cerebral embolism was not unequivocal, as usually described in the literature. It is also intended to emphasize the need for early withdrawal of the CVC and the utmost care in its manipulation. Hyperbaric oxygen therapy is indicated when the clinical situation is severe and conservative measures such as patient positioning, aspiration of air from the CVC and its withdrawal and high-concentration oxygen therapy are insufficient.

PE 067

### WHEN GUILLAIN-BARRÉ SYNDROME MEETS THE RESPIRATORY ICU: A DESCRIPTIVE STUDY OF PATIENTS ADMITTED OVER THE LAST 5 YEARS

**B Amann, E Fragoso, I Claro, C Martins, C Lopes, P Azevedo, C Bárbara**

Centro Hospitalar Lisboa Norte

Key-words: Mechanical ventilation; Nontraumatic acute paralysis; Guillain-Barré

**Background:** Guillain-Barré syndrome (GBS) is the leading cause of nontraumatic acute paralysis in industrialized countries. Major features include ascending tetraparesis, with bulbar dysfunction evolving into respiratory failure requiring invasive mechanical ventilation (IMV). Prognosis is dictated by factors such as early recognition of the disease and prompt treatment.

**Objective:** To describe the clinical features and outcome of patients with GBS admitted to a Respiratory Intensive Care Unit (RICU).

**Methods:** Retrospective study of patients admitted to our RICU with GBS over the last 5 years. We analyzed demographics, APACHE II, time of year on admission, clinical presentation, GBS subtype, treatment, ICU length of stay, days on IMV, complications and outcome.

**Results:** Five patients were included (males:60%). Median age 56 years. Median APACHE II: 11. The cause was post-infectious in 2 cases, post-influenza vaccination in 1 case and unidentified in the remaining patients. Electromyography identified 2 cases as demyelinating disease, 2 as axonal disease. All were submitted to IVIG about 4 days after the first symptoms, as well as aggressive rehabilitation. Patients were on IMV about 6 days after the first symptoms (median duration: 23days). Tracheostomy was performed in one patient. One patient died (No differentiation outcomes were found compared to other cases).

**Conclusion:** This study highlights the importance of early diagnosis and appropriate referral to the ICU, in order to manage respiratory failure and avoid complications. IVIG combined with aggressive rehabilitation are key to reduce IMV duration, ICU length of stay, morbidity and mortality in GBS patients.

PE 068

### PNEUMOMEDIASTINUM IN A PATIENT ON HIGH FLOW OXYGEN THERAPY

**R Silva, J Barata, M Batista, E Melo, A Albuquerque**

Serviço Pneumologia- CHCB; UCIP- CHTV

Key-words: High Flow, pneumodiastinum, subcutaneous emphysema

High-flow oxygen therapy, which consists of delivering humidified oxygen to the patient through a nasal cannula that can reach 60 liters / minute, reduces dead space, has a PEEP effect, provides the patient with a constant fraction of oxygen and humidifies airways. Its use has been increasingly frequently as a ventilatory support for critically ill patients. The indications are: hypoxemic respiratory insufficiency, post-extubation, pre-intubation, exacerbation of COPD, patients without indication for intubation, heart failure and sleep apnea.

High-flow oxygen therapy was introduced in the early 1990s and allowed humidification of gases as well as high flows which was previously not possible, improving patient comfort.

The complications resulting from this therapy are very rare. We describe a case of a patient who had a pneumodiastinum resulting from high flow oxygen therapy.

**Case report:** A 75-year-old woman, admitted to the General Surgery department, with a diagnosis of diverticulitis. She underwent conservative treatment with antibiotics. On the third day of hospitalization, the patient presented sudden desaturation with respiratory insufficiency refractory to the oxygen therapy. The patient was submitted to a thoracic CT scanning, which revealed a pattern of depolarized glass with peribroncovascular predominance, with a slight thickening of the septum, with crazy paving at the bases, and diffuse bronchial dilatation. The patient started noninvasive ventilation but did not respond to treatment and due to poor adaptation to NIV ended up initiating high flow oxygen therapy and corticosteroid therapy. Because of eminence of the need for orotracheal intubation was then admitted to the intensive care department.

There was favorable evolution with improvement of hypoxemia. On the ninth day of hospitalization, the patient had a subcutaneous emphysema, a chest CT was performed and demonstrated a pneumomediastinum. The patient then initiated a high concentration mask. Upon discharge from the Intensive Care department, the patient presented improvement of the abdominal and respiratory illness, with a Saturation of 94% (O<sub>2</sub> Fi of 50%) and almost total resorption of the pneumomediastinum.

**Discussion:** In recent years we have seen an increase in the use of high flow oxygen therapy. There are several indications and according to the literature there are not many complications described. However, recent studies have shown that high-flow oxygen therapy can generate very high pressures in the airways and this pressure is neither sustained nor predictable. This unpredictable elevation in airway pressure can result in a number of complications such as pneumothorax, pneumomediastinum, and pulmonary emphysema. Chang et al. has argued that high-flow oxygen therapy devices achieve much higher nasopharyngeal pressures than CPAP, it can produce a pressure of 120 cm H<sub>2</sub>O. In the lower respiratory tract it has been demonstrated that high flow oxygen therapy can generate pressures up to 8 cm H<sub>2</sub>O. This positive pressure, which on one hand is responsible for the good results of high-flow oxygen therapy, on the other hand may cause complications such as pneumodiastinum mainly in patients with structural lung injury.





PE 069

### BRONCHODILATOR RESPONSE IN NORMAL BASE SPIROMETRY: IS IT REALLY NECESSARY?

M Pereira, J Valença, R Staats, T Pequito, A Lutas, S Furtado  
Hospital da Luz

Key-words: Respiratory Function Testing, Bronchodilator, Spirometry

**Introduction:** Spirometry before and after administration of short-acting bronchodilator (BD) is recommended to assess the reversibility of flow limitation in an obstructive ventilation disorder. However, studies indicate that when baseline spirometry has  $FEV_1/FVC > 0.70$ , there is a low probability of a positive response to BD.

**Objectives:** To determine the prevalence of bronchodilator positive responses in normal baseline spirometry and which other parameters of the lung function tests (LFT) have possible predictive value.

**Methods and Materials:** Retrospective study in which adult patients who underwent LFT with normal baseline spirometry (according to the ATS/ERS criteria of 2005) were sent during the year 2016 by the Immunoallergology department. Patients were collected according to categories: positive responses according to the ATS/ERS criteria, partial responses (increase of  $FEV_1$  or FVC of 200ml or 12% relative to basal exams) and a random sample of subjects with none of these responses. Statistical analysis was performed using the Statistical Package for Social Sciences (SPSS) version 20.

**Results:** Of the 184 adults with normal spirometry who were given BD, 3 presented a positive response, 33 were partial responders and 28 were randomly selected from the rest, in which there was considered to be no significant or partial spirometric response to BD, in a total sample of 64 individuals.

The mean age was  $36 \pm 14$  years, 37.5% were male, with mean baseline  $FEV_1/FVC$  of  $0.83 \pm 0.06$ .

According to the ATS / ERS criteria in PFR with normal baseline spirometry, there was a prevalence of 4.6% in the sample (1.6% of the population) of positive responses.

There was a statistically significant correlation between basal  $FEV_1/FVC$  and the following parameters:  $MEF_{75/25\%}$ ,  $MEF_{75\%}$ ,  $MEF_{50\%}$ ,  $MEF_{25\%}$ , ITGV, RV, RV/TLC,  $R_{tot}$ ,  $sG_{aw}$ ,  $\text{ângulo}\beta$ ,  $SF_{25\%}$  and  $SF_{50\%}$ . All parameters evaluated showed statistically significant differences after administration of BD, with the exception of TLC,  $R_{tot}$  and angle  $\beta$ .

According to the response criteria to BD ATS/ERS, were seen as potential predictors of positive response the following parameters:  $FEV_1/FVC$ , % $FEV_1$ , %FVC, %PEF, % $MEF_{75/25\%}$ , % $MEF_{75\%}$ , % $MEF_{50\%}$ , % $MEF_{25\%}$ , PEF, RV, %RV and RV/TLC.

The response to BD was also tested taking into account the criterion that if there was a  $> 8\%$  increase in baseline percentage of  $FEV_1$ , it would be considered a significant response. In this context, with a prevalence of 14% in the population (37.5% in the sample), possible predictors of response parameters were:  $FEV_1/FVC$ , % $FEV_1$ , all instantaneous flows in absolute value and percentage, and % $MEF_{75/25\%}$ , % $MEF_{75\%}$ , % $MEF_{50\%}$ , %PEF, RV, %RV, RV/TLC,  $sG_{aw}$  and  $SF_{25\%}$ .

**Discussion/Conclusion:** From this population in study, we found a prevalence of 1.6% of significant responses according to the ATS/ERS criterion (no baseline % $FEV_1 > 100\%$ ), which corroborates the inadequacy of BD administration to all patients.

It is also concluded that the criteria currently used for the evaluation of bronchodilator response based solely on spirometry (criteria that do not take into account anthropometric data) may be insufficient for an adequate evaluation of the response to BD.

PE 070

### THE ROLE OF COMMUNITY PHARMACIES IN SCREENING AND SUBSEQUENT MANAGEMENT OF CHRONIC OBSTRUCTIVE PULMONARY DISEASE

P Soares, AL Pinto, AS Maximiano, M Rosa, E Paulino  
Farmácias Holon

Key-words: COPD; community pharmacy; pharmaceutical intervention; screening; spirometry

**Introduction:** Chronic Obstructive Pulmonary Disease (COPD) is one of the main causes of morbidity and mortality worldwide. In Portugal, epidemiological data reports a prevalence of 14.2% of the disease in people over 40 years of age. COPD has been associated with a high burden in terms of chronic morbidity and loss of quality of life, and an increase in its prevalence is expected in the next decades. COPD represented the sixth cause of worldwide death in 1999, with a prediction to become the third cause in 2030.

Therefore, it is of the utmost importance that the community pharmacist, in close collaboration with the other healthcare professionals, implements activities which aim to prevent, identify and manage COPD, in order to achieve better public health outcomes for the individual, and decrease the social and economic costs associated with the disease.

**Aims:** 1. To describe the implementation of strategies to promote the early identification of people at risk of developing COPD, as well as to assist in the management of patients with the respiratory disease in a group of community pharmacies. 2. To assess the impact of an integrated service tailored to the person with COPD.

**Materials and Methods:** Support materials were developed and provided to a group of 400 community pharmacies, including service manuals, flyers and questionnaires. The questionnaire developed by *The Global Initiative for Chronic Obstructive Lung Disease (GOLD)* was adapted and used to identify people at risk of the disease. The follow-up of diagnosed COPD patients is performed in the scope of a pharmaceutical consultation, where the pharmacist evaluates the patients' adherence to the prescribed treatment, the correct use of medicines, the inhalation technique, lifestyle, smoking habits and co-morbidities. Information is gathered by means of a formulary developed for this purpose. Beyond pharmacists and pharmacy technicians, the strategies to address a COPD patient involve a multidisciplinary team constituted by nurses and nutritionists. Data analysis was carried out using the Excel software ®.

**Results:** From July 2015 to June 2017 the risk of COPD was evaluated in a total of 832 individuals, from which 361 answered affirmatively to three or more questions of the GOLD questionnaire. During the same period of time, the degree of control of the disease was assessed in 393 diagnosed patients. Of these, 77.9% (n=306) showed an mMRC Grade higher than 0. Of those individuals who performed the test of respiratory function (n=387), 29.3% (n=115) displayed  $FEV_1/FVC < 0.70$ . Additionally, the inhalator technique was appraised in 200 individuals, having been found that 31.0% (n=62) presented an incorrect technique. Overall, a total of 1415 screenings of the respiratory function were carried out between January 2015 and May 2017 in 73 community pharmacies.

**Conclusion:** Pharmacists play a key role in the disease awareness process, namely to risk factors of COPD, as well as the importance of an early diagnosis. In cooperation with other healthcare professionals, it is possible to provide an integrated and multidisciplinary health solution in communitarian pharmacies, allowing for a holistic solution to the needs of patients.

PE 071

### **INCAPACITY CAUSED BY RESPIRATORY DISEASE IN THE LOURES - ODIVELAS ACES**

**CR Silvestre<sup>1</sup>, C Martinho<sup>1</sup>, DG Lopes<sup>1</sup>, H Esteves<sup>1,2</sup>**

<sup>1</sup>Public Health Unit of the Health Centers Groups Loures - Odiveias;

<sup>2</sup>Institute of Preventive Medicine and Public Health, Faculty of Medicine, University of Lisbon

**Key-words:** respiratory disease; incapacity; lung cancer; chronic obstructive pulmonary disease; asthma

**Introduction:** Respiratory diseases are, due to their high morbidity and mortality, a relevant public health problem.

Respiratory diseases limit individuals in the execution of personal, social and working activities.

In 2015, respiratory disease were the third cause of death in Portugal, being responsible for 11 461 potential years of life lost.

The aim of this study was to determine the number and characteristics of respiratory diseases in individuals to whom it was issued a Multipurpose Medical Certificate of Incapacity in 2016, at the Loures - Odiveias Health Centers Groups (ACES).

**Methods:** We performed a retrospective descriptive study of all the medical records of patients to whom it was issued, according to the National Table of Incapacities, a Multipurpose Medical Certificate of Incapacity in 2016 at ACES Loures - Odiveias.

**Results:** Of the 1833 subjects submitted to a Medical Board, 6.7% (122) had respiratory pathology.

Of the individuals with respiratory disease, 60% were males and 40% females, with a median age of 67 years.

Lung cancer was the most common disease (45.9%). Chronic obstructive pulmonary disease (COPD) was present in 23% of the individuals, asthma in 5.7% and the remaining presented various other respiratory pathologies.

Of note, 10% of the individuals with respiratory disease required long-term oxygen therapy.

Among all patients with lung cancer, 63.3% were male and 35.7% female; of those with COPD, 75% were male and 25% female; regarding patients with asthma, 14.3% were male and 85.7% were female.

**Conclusion:** Seven out of hundred individuals, to whom a Multipurpose Medical Certificate of Incapacity was issued in 2016 at ACES Loures - Odiveias, had respiratory disease, with lung cancer being the most common pathology.

Lung cancer and COPD were more frequent in males, whereas asthma was more frequent in females.

PE 072

### **COMPARATIVE ANALYSIS BETWEEN ASTHMATIC AND CHRONIC OBSTRUCTIVE PULMONARY DISEASE SMOKERS ATTENDING A TOBACCO CESSATION PROGRAM**

**RP Camara<sup>1</sup>, MM Batista<sup>2</sup>, D Rolo<sup>1</sup>, C Alves<sup>1</sup>, E Camacho<sup>1</sup>**

<sup>1</sup>Hospital Nossa Senhora do Rosário - Centro Hospitalar Barreiro-Montijo,

<sup>2</sup>Hospital São Bernardo - Centro Hospitalar de Setúbal

**Key-words:** COPD, asthma, tobacco, Portugal, comorbidities, therapy

**Introduction:** Smokers with asthma or chronic obstructive pulmonary disease (COPD) have heavier symptoms, more comorbidities and more morbidity and mortality. There are few data about this group of smokers in Portugal. The aim of this study was to characterize and compare a population of asthmatic and COPD smokers attending an hospital tobacco cessation program in Portugal.

**Methods:** The authors made a retrospective analyse of 400 clinical files randomly selected from the total of participants in an hospital tobacco cessation program between January 2012 to December 2016. Incomplete files were excluded, and asthmatic and COPD patients were selected. The data analysed were: sex, age, age for starting consume, number of pack per years units, comorbidities, arguments for smoking, reasons for starting the program, Fagerstrom Test (FT) and Richmond Test (RT) score, and therapy modalities (educational and pharmacological)

**Results:** From 372 files eligible, the authors identified 23 asthmatic and 51 COPD patients. The mean age for asthmatics was 48.1 years (minimum 18, maximum 77) and for COPDs was 55.9 years (minimum 30, maximum 77). The mean age for starting consumption was 19.4 years for asthmatic patients (minimum 11, maximum 43) and 21 years for COPS (minimum 10, maximum 45). COPD patients had more years of consumption and higher numbers of pack per years units (34.9 years and 38.7, respectively) then asthmatics (28.7 years and 31.8, respectively). The main comorbidities reported in both groups were dyslipidaemia (47.8% for asthmatics, 45.1% for COPDs) and hypertension (43% for asthmatics, 47% for COPDs). 15.7% of those with COPD were also asthmatics. 21.6% of COPDs and 13% of the asthmatics had history of depression. 2% of smokers with COPD and 2% of the total smokers without diagnosis of COPD had lung cancer. The head arguments for smoking were: stress (78.3% asthmatics and 80.4% COPDs), automatic gesture (52.2% asthmatics and 49% COPDs), socially (60.9% asthmatics and 43.1% COPD) and for pleasure (34.8% asthmatics and 47.1% COPDs). The reasons to start the program were mainly personal (86.9% of asthmatics and 70.6% of COPDs), followed by medical advice (52% of asthmatics and 74.5% of COPDs) and familiar pressure (13% of asthmatics and 33.3% of COPDs). The mean score for FT was 6 for COPD patients and 5.9 for asthmatics (minimum 0, maximum 10), and for the RT was 6.9 for COPD patients and 7.5 for asthmatics (minimum 3, maximum 10). All patients had educational support, 87% of asthmatics and 96% of COPD patients also had pharmacological therapy.

**Conclusions:** Both groups showed premature ages for start smoking, although COPD patients had higher exposure to tobacco. The main comorbidities were hypertension and dyslipidaemia, and depressive syndrome was more prevalent among smokers. Lung cancer had similar reports between COPD patients and no COPD patients besides what was expectable, what could be related with sub diagnosis of this pathology even within risk groups. The dependence rate was similar for both, but asthmatic patients had higher motivation rates. COPD patients had more pharmacological prescriptions than asthmatics.





PE 073

## PROLONGED STEROID THERAPY AND PULMONARY ASPERGILLOSIS

**MF Guia, C Alves, C Longo, JP Boléo-Tomé, F Rodrigues**  
Hospital Professor Doutor Fernando da Fonseca, EPE

Key-words: Aspergillosis, steroid therapy

54 years old black female patient, natural of Cape Verde, living in Portugal for 41 years, retired (former fishmonger). Diagnosed with pulmonary tuberculosis 3 years ago, (followed in Respiratory Diagnostic Centre and treated with isoniazid, rifampicin, pyrazinamide and ethambutol), with remaining sequel radiologic lesions. Other diseases included psoriasis (diagnosed 2 years earlier) and arterial hypertension. Usual medication: valsartan/hydrochlorothiazide and amlodipine. Under therapy with 20 mg daily oral prednisolone during 3 months one year before due to psoriasis worsening. Admitted in the emergency room due to dyspnea, cough, mucopurulent sputum, (occasionally brownish) and asthenia for 3 months, with progressive worsening, denying anorexia, weight loss or night sweating. Amoxicillin-clavulanate was prescribed previously, without improvement. On physical examination, was subfebrile (37,8°C), with crackles on right hemithorax auscultation. Analytically there was a discreet hypoxemia at room air, a slight leukocytosis, reactive C protein levels of 12,7 mg/dL, negative antibodies against human immunodeficiency virus and negative sputum smear microscopy for acid-fast bacilli. The chest radiogram showed sequel changes and new infiltrates on the superior half of the right lung field. Medicated empirically with clarithromycin, lately stepped to piperacillin-tazobactam (for 10 days). The thoracic computed tomography showed "right upper lobe hypotransparent alveolar changes, with multiple cavitated lesions, two of them partially filled with solid material, suggestive of tuberculosis cavitations filled with fungus. There were also more discreet left upper and lower lobes hypotransparent alveolar changes and multiple enlarged mediastinal and hilar lymph nodes, some probably with necrosis."

The flexible bronchoscopy showed right upper lobe hyperemic mucosa. It was identified *Aspergillus niger* on the microbiological examination of the performed bronchial washing and bronchoalveolar lavage.

The patient was medicated with voriconazole, intravenously on the first week and orally after that. A decrease on dyspnea, cough and inflammatory markers was verified. There were no side effects due to medication. After hospital discharge, anti-fungal therapy was maintained.

This case report illustrates that prolonged systemic steroid therapy is a risk factor for subacute invasive pulmonary aspergillosis. The commonest symptoms include dyspnea, productive cough, fever and asthenia, which can evolve for 3 months with progressive worsening. The "crescent sign" is a very suggestive radiological finding. On the current case, the diagnosis was confirmed by the association between clinical and compatible radiological findings and identification of *Aspergillus* on culture.

PE 074

## NECROTISING PNEUMONIA BY NOCARDIA IN AN IMMUNOCOMPETENT PATIENT: CLINICAL CASE

**FV Machado, AR Santos**  
Centro Hospitalar São João

Key-words: Necrotising pneumonia; Nocardia; Nocardiosis

**Introduction:** Nocardiosis is a rare disease caused by bacteria of the *Nocardia* genus, whose variable clinical and radiologic presentation warrant the consideration of a long list of differential diagnosis. Even though it is traditionally considered an opportunistic infection, about one third of cases occur in immunocompetent patients. Its course can be acute, sub-acute or chronic. Pulmonary involvement is the most frequent, and about half of pulmonary nocardiosis cases disseminate to other organs or systems. Due to the high rate of progression or relapse, a prolonged follow-up and treatment course is recommended for nocardiosis.

**Clinical case:** 57-year old woman, smoker (40 pack-years), without any other relevant pathologies, with no usual medication, admitted in the emergency room for chest pain with pleuritic characteristics for several days, associated with fever, asthenia and anorexia. The patient took a chest radiograph which showed an area of increased density on the lower portion of the right lung. The diagnosis of Community-acquired pneumonia was assumed and she was discharged on antibiotherapy with Amoxicillin/Clavulanate and Azithromycin.

4 days later the patient returned to the ER for maintaining the previous symptoms and an onset of cough with hemoptoic sputum. She repeated the chest radiograph, which maintained a similar consolidation on the right lung base, along with an increase in inflammatory analytic parameters. She was then admitted for further vigilance and empirical treatment with Piperacillin/Tazobactam was initiated. At admission the patient was mildly polypneic, with decreased auscultatory sounds on the lower half of the right hemithorax, without any other significant findings on physical examination, with an arterial blood gas sample without evidence of respiratory failure. HIV testing and sputum bacilloscopies were negative.

During her stay in the hospital the patient took a thoracic CT scan which revealed a paravertebral area of consolidation with signs of infected necrosis, with an extension of 46 x 37 x 53 mm, with associated loculated pleural effusion of the mediastinic pleura. Bronchofibrosopic analysis was completely normal. After 14 days of therapy with Piperacillin/Tazobactam the patient showed significant clinical, radiological and analytic improvement and was then discharged, without the isolation of any infectious agent.

About a week after discharge there was an isolation of a strain of *Nocardia* Spp. in a mycobacteriological culture medium. The patient was called and the systemic involvement of nocardiosis was excluded, particularly central nervous system (normal cerebral CT scan) and cutaneous involvement. She then started therapy with Trimetoprim-Sulfamethoxazol, which she maintained for a duration of 6 months, without any signs of relapse, progression or adverse events and a significant radiological improvement.

**Discussion:** Although it is more frequent in immunocompromised patients, nocardiosis should also be considered in the differential diagnosis of lung disease in immunocompetent patient. The exclusion of multiple systems involvement and a prolonged course of vigilance and treatment are of major importance to prevent and treat progression or relapse of nocardiosis.



PE 075

## PNEUMONIAS IN A PNEUMOLOGY WARD

**J Carvalho, A Almendra, C Carvalho, AS Oliveira, L Carvalho, C Bárbara**

Unidade de Internamento Geral, Serviço de Pneumologia, Hospital Pulido Valente, CHLN, E.P.E.

Key-words: Pneumonia, Casuistry, Antibiotic therapy

Pleural effusions are frequent, due to disease localized in pleura, lung, systemic, organic dysfunction and drug use. Pleural involvement is the most frequent form of extrapulmonary tuberculosis and is frequently associated with pulmonary form and should be considered in the etiological diagnosis.

Male, 42 years old, mason, native of Cape Verde residing in Portugal for 16 years and smoker.

Went to Emergency Department due to three months of cough with mucopurulent expectoration, fever, chills, asthenia, anorexia and weight loss of 20Kg. Prior diagnosis of post-trauma hypoacusis. Objective examination: emaciated, sub-febrile (TT: 37.3°C), SpO<sub>2</sub>: 96% with FiO<sub>2</sub>: 21% and pulmonary auscultation with decreased vesicular murmur in the left lung base with subcrepitant fervor and decrease of vocal vibrations in the same location. Analytically anemia (Hb: 11.6g / dL), thrombocytosis (624000), hyponatraemia (127mmol / L) and elevation of CRP (11.1mg/dL). Chest radiography with homogeneous hypotransparency in the lower left 1/3, suggestive of pleural effusion. Direct mycobacteriological examination of sputum with negative result.

Empirical antibiotic therapy with Amoxicillin / Clavulanic Acid and Azithromycin was initiated.

Complementary examinations:

- Blood cultures and blood cultures in BACTEC with negative result.
- HIV negative serology.
- Chest computed tomography (D1): *"Countless micronodules dispersed by the pulmonary parenchyma bilaterally, some subpleural. Densification of the parenchyma tending to consolidate in the basal segments of the left lower lobe. Multiple adenopathies with uptake of heterogeneous contrast, many with hypodense and hypocapping areas, in mediastinal topography and in pulmonary hila, several of them confluent. Band densification of probable atelectatic component in the antero-internal slope of the left superior lobe. Moderate left pleural effusion. In the upper abdomen, we highlight: multiple nodal hypodense images scattered by the splenic parenchyma; small nodular cortical hypodense images in the intersected segments of both kidneys."*
- Thoracentesis (D1): Exit of 1260cc of sero-fibrinous liquid with exudate characteristics and ADA increase (62UI / L).
- Bronchofibrosocopy (D2): Left bronchial tree with reduction of the caliber of the segmental orifices of the upper division of the superior lobe, by extrinsic compression.

After completing the diagnostic tests, absence of clinical improvement and due to the increase of ADA in the pleural fluid, it was decided to initiate antibacillary therapy, presenting a very favorable clinical evolution.

Both biopsies that were performed, pleural and bronchial, demonstrated necrotizing granulomatous inflammation, compatible with tuberculosis in active phase. The cultural examination of the sputum initially collected was positive for multisensitive *Mycobacterium tuberculosis*.

Hospital discharge with diagnosis of disseminated tuberculosis. Referred to the Center for Pneumological Diagnosis.

The authors valued clinical and imagiological findings consistent with disseminated tuberculosis in patient with impaired clinical status with multiple organ involvement, ADA increase in pleural fluid and poor response to antibiotic therapy. The initiation of antibiotic therapy was justified, and cultural results could be expected at a later stage due to the severity of the clinical situation.





PE 076

### ACTINOMYCES AND LUNG: A RARE ASSOCIATION

B Cabrita, E Pena, C Rodrigues, S Correia, M Silva, I Neves, R Abreu, S Jordão, S Correia, J Ferreira

ULSM - Hospital Pedro Hispano

Key-words: Actinomycosis, pulmonary, actinomyces

**Introduction:** Actinomycosis is a chronic bacterial infection caused by *Actinomyces* spp., a Gram-positive filamentous bacillus, commensal from oropharynx, gastrointestinal and female genital tract. *Actinomyces israelii* is the most common bacteria, however, *Actinomyces meyeri* is the most likely to cause lung infection. *Actinomyces* spp. tends to develop yellow sulphuric granules in affected tissues. Cervicofacial region is the most common site of infection.

Lung infection is rare (15% of cases) and usually develops after aspiration of oropharyngeal or gastrointestinal secretions. It is more common in men between 4<sup>th</sup> and 5<sup>th</sup> decades. It is associated with immunosuppression, poor oral hygiene, structural lung disease or risk factors for aspiration, like alcoholism. Typically, presents with pneumonia (might be associated with fistula or cavitation), lung abscess or empyema. In some cases, it may simulate a tumoral mass. Adequate treatment requires prolonged antibiotic therapy to prevent relapse.

We present 3 clinical cases of pulmonary actinomycosis.

**Clinical case 1:** 70-year-old male patient, ex-smoker (>100 PYU), with high alcohol consumption, bronchiectasis and Asthma-COPD Overlap. Admitted in the Emergency Service for dyspnea, cough, hemoptysis and weight loss (4kg in 4 months). He was empirically treated with piperacillin-tazobactam. Because of clinical suspicion of pulmonary tuberculosis and scarce expectoration, the patient was submitted to bronchofibroscopy. In bronchoalveolar lavage, *Actinomyces meyeri* was isolated, and iv ampicillin was initiated (4 weeks). At discharge, with good clinical response, oral amoxicillin was prescribed for 12 months.

**Clinical case 2:** 62-year-old male patient, ex-smoker (20 PYU). Admitted in the Emergency Service with back pain, anorexia, fatigue and dyspnea for 15 days. He had history of dental procedures performed 3 months prior to this condition. Hospitalized for sepsis with focus on empyema, he was treated with imipenem. A surgery for lysis of adhesions and pleuropulmonary decortication was performed, and *Actinomyces odontolyticus* isolated from pleural fluid sample. At discharge, with good clinical response, he was medicated with oral clindamycin (12 months), due to ampicillin allergy.

**Clinical case 3:** 26-year-old female patient, with type 1 diabetes mellitus, severe periodontal disease and recent right inferior lung lobe pneumonia. Admitted in the Emergency Service with pleuritic thoracic pain and cough for 7 days. Hospitalized with right inferior lobe lung abscess, she was medicated with ceftriaxone and clindamycin, and posteriorly piperacillin-tazobactam. After isolation of *Actinomyces* spp. From transthoracic biopsy, iv ampicillin was administered (4 weeks) and later oral amoxicillin for 7 months. Control thorax CT taken 6 months later, evidenced only residual densifications.

**Conclusion:** To make a correct diagnosis of actinomycosis is necessary to conjugate clinical, imaging, microbiologic (positive culture in <50% cases), anatomopathological (sulphuric granules) findings and verify a good treatment response.

Treatment consists in iv penicillin administration usually for 4 weeks and then orally for 6-12 months.

Nowadays, actinomycosis is a rare pathology with good prognosis if treated appropriately.

PE 077

### GOOD'S SYNDROME - A MYSTERIOUS DISEASE. REPORT OF 2 RARE CASES

D Duarte, J Eusébio, P Raimundo, N André, A Domingos

Centro Hospitalar do Oeste - Torres Vedras

Key-words: Good's syndrome, recurrent respiratory tract infections, hypogammaglobulinemia, thymoma

**Introduction:** Good's syndrome is an association between thymoma and immunodeficiency, like hypogammaglobulinemia. It is a rare entity (about 150 cases described in literature) usually arising in the 4<sup>th</sup> and 5<sup>th</sup> decades of life with a high mortality rate (30% at 5 years and 67% at 10 years).

It was first described in 1954 but its physiopathology still remains a mystery. This disease is characterized by hypogammaglobulinemia, low B cell count, low T CD4 cell count and abnormal CD4/CD8 ratio. Thus, patients may present repeated infections especially in the respiratory and gastrointestinal tracts (chronic diarrhea in 50% of patients) caused by encapsulated bacteria and opportunistic agents. The first line treatment is thymectomy and intravenous immunoglobulin G.

**Case Reports:** Therefore we describe 2 rare cases of Good's Syndrome.

**Case 1:** A 46 year-old male patient, non-smoker, with personal history of thymoma (surgery 12 years before), pulmonary tuberculosis (11 years before) and repeated respiratory tract infections since 8 years ago who presents with acute respiratory infection and hypoxemia.

Etiological investigation was undertaken: **1)** Thoracic CT - bilateral central and peripheral bronchiectasis; **2)** Bronchoscopy - generalized inflammatory signs, negative microbiology; **3)** Pulmonary function tests - severe obstructive ventilatory defect with no response to bronchodilators and resting hypoxemia (pO<sub>2</sub> 65mmHg); and **4)** Blood test - lymphopenia, low CD4/CD8 ratio, hypogammaglobulinemia (2%), IgG 213 mg/dL (RV: 723-1685) and IgA 8 mg/dL (RV: 60-382).

The diagnosis of Good's syndrome was made and the patient started immunoglobulin G every 3 weeks. The patient maintained some respiratory tract infections and died 7 years after the diagnosis due to an episode of respiratory failure.

**Case 2:** A 46 year-old male patient, non-smoker, with personal history of thymoma (known 4 months before), Neurofibromatosis Type 1 and repeated respiratory tract infections since 7 years ago who presents with acute respiratory infection and hypoxemia.

Etiological investigation was again undertaken: **1)** Thoracic CT - interlobar septa thickened of the lower lobes of lungs associated with small bronchiectasias, tree-in-bud pattern and anterior mediastinal mass, probably thymic; **2)** Bacteriology of sputum - negative; **3)** Pulmonary function tests - mild obstructive ventilatory defect with no response to bronchodilators and resting hypoxemia (60 mmHg); and **4)** Blood test - lymphopenia, hypogammaglobulinemia (3.8%), IgG 328 mg/dL, IgA 6 mg/dL e IgM 14 mg/dL (RV: 40-312).

Once again the diagnosis of Good's syndrome was made. Thymectomy was performed and the patient started immunoglobulin G. Currently, the patient maintains follow-up and treatment with immunoglobulin G every 4 weeks although with some respiratory tract infections.

**Conclusion:** The Good's syndrome prognosis appears worse comparable with other immunodeficiencies. An early diagnosis (based on clinical information and immunologic profile) should be performed in order to start the treatment and avoid complications, especially severe infections. Despite this, repeated infections are frequent. More studies are needed to understand this entity.



PE 078

## **PNEUMONIA POR PNEUMOCYSTIS JIROVECCI EM DOENTE NÃO-VIH**

**DB Coelho, AR Monteiro, AI Ferreira, MJ Lima, J Almeida, E Ferreira**  
Centro Hospitalar de São João

Key-words: Pneumocystis, Pneumonia, Immunosuppression, prophylaxis

**Introduction:** Pneumocystis Jirovecci Pneumonia (PJP) is a potentially fatal infection that may develop in immunocompromised patients. It is classically associated to HIV infection with CD4 count inferior to 200/mm<sup>3</sup>. However, it can also occur in the context of pharmacological immunosuppression. In the latest years, there is a growing number of cases in patients with transplantation or chemotherapy-treated. Corticosteroid therapy is a known risk factor for PJP and a higher mortality is reported in non-HIV patients.

**Case report:** Fifty-five-year-old female, non-smoker, healthy, with a recent hospitalization due to immune hemolytic anemia, warm antibodies, related to Diclofenac. Treated with 3 pulses iv of 1g methylprednisolone followed by oral prednisolone (PDN) (2mg/kg/day) and rituximab (600 mg/week for 4 weeks). She was discharged after 1 month, asymptomatic, under PDN withdrawal therapy (1.6mg/kg/day). Two weeks after, she was diagnosed with oral candidiasis, treated with nistatin, and after 3 weeks, herpetic queratitis, treated with aciclovir.

One month after discharge from hospital, she was admitted to the Emergency room (ER) with fever, dyspnea to minimal or moderate activity, asthenia, being diagnosed with tracheobronchitis and treated with amoxicillin-clavulanic acid. Despite the therapy, she maintained symptoms and was again admitted to the ER with hypoxemic respiratory insufficiency (RI) (PaO<sub>2</sub>/FiO<sub>2</sub>:190) and radiograph showed an infiltrate in the right lung. Lab tests with leukocytosis (12,78 x 10<sup>9</sup>/L), elevated C-reactive protein (71mg/L), lactate dehydrogenase 617 U/L, 285 cd4cells/mm<sup>3</sup>, HIV negative. The patient was diagnosed with pneumonia (hospital-related versus opportunistic infection) and treated with piperacillin-tazobactam, sulfamethoxazol-trimetopim (TMP/SMX) and PDN in PJP dose. Thorax CT revealed extensive ground-glass opacities throughout all lung lobes, predominantly central, and a consolidation area with air bronchogram in the middle lobe's medial segment. Broncho-alveolar lavage revealed positive PJP DNA, therefore piperacillin-tazobactam was discontinued. There was a favorable clinical evolution and the patient was discharged at day 7 without RI, with indication to complete 21 days of TMP/SMX treatment.

At the 10<sup>th</sup> day of TMP/SMX, the patient developed skin rash interpreted as TMP/SMX toxidermia. The antibiotic therapy was altered to primaquine + clindamycin, after which the patient started secondary prophylaxis with atovaquone. The patient was referred to Internal Medicine and Hematology consultations and to start desensitization of TMP/SMX therapy.

**Discussion:** This report reveals the importance of a rapid recognition of PJP in non-HIV patients to prevent unfavorable outcomes. Moreover, it highlights the need for primary prophylaxis in patients receiving high-dose corticosteroid treatment for long periods of time, particularly when associated with other immunosuppressive therapies or conditions. Having started primary

prophylaxis could have prevented the development of PJP in this patient. However, the lack of solid guidelines as well as the lack of knowledge of the values of cd4 count in this type of patients impairs the clinicians' decisions. On the other hand, adverse reactions to sulfonamides are to be taken into account, appearing in as much as a third of patients.

We this report, we aim to alert to the necessity of clinical investigation to support strategies of PJP prophylaxis in this growing number of patients.





PE 079

### **BORDETELLA BRONCHISEPTICA IN AN IMMUNOCOMPROMISED PATIENT: CASE REPORT**

**V Pereira, C Pereira, P Dionísio, P Monteiro, C Bárbara**  
Pneumology Department, Centro Hospitalar Lisboa Norte

Key-words: bordetella bronchiseptica, immunosuppression, rheumatoid arthritis, biologic agents, respiratory infection

**Introduction:** *Bordetella bronchiseptica* is an aerobic Gram-negative *coccobacilli* known to be present in the upper respiratory tract of many wild and domestic animals, where it can cause respiratory infections. In humans, despite being a rare agent, it may cause respiratory infections, particularly in immunocompromised patients. Because of its rarity few cases are reported in the literature, most of them regarding colonization or infection in immunosuppressed patients with human immunodeficiency virus (HIV). We report a case of a drug-induced immunosuppressed patient.

**Case presentation:** A 68-year-old woman was referred to a pneumology consultation to exclude contraindications in order to start biological drugs for her rheumatoid arthritis. She had rheumatoid arthritis for 12 years and was immunosuppressed with methotrexate. She inhabited in the countryside and had contact with animals. The patient reported non-productive cough, mostly nocturnal and wheezing with no other relevant complaints. She performed a thoracic computed tomography scan, with no signs of active infection. Her respiratory function tests revealed bronchiolar obstruction. Her bronchoscopy showed bronchial edema and mucous spuntum on the inferior lobe of the right lung. Cultural study of bronchoalveolar lavage and sputum revealed a *Bordetella bronchiseptica* with no documented antibiotic resistance. The patient did not develop any other complaints, elevation of inflammatory markers or radiological changes consistent with infection. Since she was proposed to biological therapy and considering the virulence of the isolated agent in immunosuppressed patients, we decided to prescribe oral amoxicillin-clavulanate for 7 days and azithromycin for 6 days. After completing the therapy she referred symptoms improvement, which may be related to a successful eradication of *Bordetella bronchiseptica*.

**Conclusion:** Although there are few case reports, *Bordetella bronchiseptica* can be a cause of virulent respiratory tract infections in humans, particularly in immunocompromised patients. It should be considered in the list of pathogens present in the human respiratory tract, particularly if there is history of animal exposure. For its known virulence, despite the absence of treatment guidelines, we decided to prescribe a course of antibiotics in order to prevent a respiratory infection in a patient under strong immunosuppressing therapy.

PE 080

### **NECROTIZING PNEUMONIA VERSUS CAVITATING CARCINOMA**

**I Moreira, S Alfarroba, I Gonçalves, A Magalhães, J Cardoso**  
Serviço de Pneumologia do Centro Hospitalar Lisboa Central (CHLC), Hospital de Santa Marta / Faculdade de Ciências Médicas da Universidade Nova de Lisboa

Key-words: Necrotizing pneumonia; Necrotizing pulmonary neoplasia; Pulmonary thromboembolism; *Pseudomonas aeruginosa*

**Introduction:** Necrotizing pneumonia consists on the destruction of lung parenchyma superimposed on infected lung tissue. It can affect up to 7% of patients with bacterial pneumonia. This progression can occur either due to the virulence of the infectious agent or due to predisposing factors of the host. The main differential diagnoses are pulmonary abscess and necrotizing pulmonary neoplasia.

**Clinical case:** This study describes the case of a 58-year-old male patient with COPD GOLD 4 D (FEV1 26%, mMRC 3), with maintained smoking habits (120UMA) and previous alcohol and inhaled drugs abuse history, with indication for diurnal OLD and nocturnal NIV due to global respiratory insufficiency.

The patient was admitted to an intensive care unit due to septic shock with a respiratory starting point (community-acquired pneumonia of the middle lobe and right lower lobe), with global respiratory insufficiency and respiratory acidosis, so empirical antibiotic therapy was begun with piperacilin/tazobactam.

In the Department of Pulmonology, he developed vomit cough and fever. A thoracic CT scan revealed a consolidation of the right lower lobe, with cavitated areas and heterogeneous contrast uptake in central topography, as well as extensive thromboembolism of the right pulmonary artery. Infection superimposed on a primary tumoral lesion was suspected. The patient underwent bronchofibroscopy that did not reveal visible endobronchial lesions and cytology/histology was negative for malignancy, but allowed the isolation of *Pseudomonas aeruginosa* and *Candida Albicans* in the bronchial lavage. A trans-thoracic aspiration biopsy was considered but postponed due to a highly suggestive image of necrotizing pneumonia, and medical therapy (meropenem, ciprofloxacin and colistin) was escalated, as well as fluconazole and enoxaparin at a therapeutic dose.

There was a protracted resolution of the infectious disease with maintenance of imaging of the cavitated lesion, despite the escalation of antibiotic therapy. In view of the patient's various comorbidities and weak performance status, it was again determined that conservative medical therapy should be maintained and any invasive intervention postponed.

After completion of several cycles of antibiotics and prolonged hospitalization with multiple intercurrents, a large exuberant and delimited locus with thickened wall was observed in the CT reassessment with reduction of the necrotic content of its interior, with hydroaeric level and dominant aerial component, interpreted as necrotizing pneumonia in the process of resolution and the apparent absence of neoplastic lesion in its interior. Radiological follow-up has demonstrated a slow improvement with smaller dimension and thinning of the walls of this lesion.

**Conclusions:** Necrotizing pneumonia is a rare but severe complication of bacterial pneumonia, associated with high morbidity and mortality. First-line treatment includes prolonged antibiotic therapy. Pulmonary resection is indicated as an alternative option in patients who do not respond and develop other parenchymal complications. The prognosis depends on disease progression and comorbidities. It is intended with this clinical case to demonstrate the difficulty of approaching these cases with conservative medical treatment when surgical intervention is not feasible.



PE 081

**IMPACT OF FUNGAL INFECTIONS IN LUNG TRANSPLANT**

T Sá<sup>1,2</sup>, V Caldeira<sup>1,2</sup>, N Caires<sup>1,2</sup>, S Silva<sup>1,2</sup>, R Coelho<sup>1,2</sup>, A Borba<sup>1,2</sup>, AS Santos<sup>1,2</sup>, N Murinello<sup>1,2</sup>, R Gerardo<sup>1,2</sup>, S Alfarroba<sup>1,2</sup>, R Costa<sup>2,3</sup>, J Silva<sup>2,3</sup>, J Reis<sup>2,3</sup>, P Calvino<sup>2,3</sup>, L Semedo<sup>1,2</sup>, J Cardoso<sup>1,2</sup>, J Fragata<sup>2,3</sup>

<sup>1</sup>Serviço de Pneumologia, Hospital de Santa Marta, Centro Hospital de Lisboa Central, Lisboa; <sup>2</sup>NOVA Medical School Faculdade de Ciências Médicas, Universidade Nova de Lisboa, Lisboa; <sup>3</sup>Serviço de Cirurgia Cardioráscica, Hospital de Santa Marta, Centro Hospitalar Lisboa Central, Lisboa

Key-words: Lung transplant, Fungal infections

**Introduction:** Infectious complications are a major cause of morbidity and mortality in patients undergoing lung transplantation (LT). Fungal infections occur in about 15 to 35% of these patients, being *Candida* spp. and *Aspergillus* spp. the agents involved in more than 80% of cases.

**Aims and Objectives:** To evaluate the impact and clinical characteristics of fungal infections in patients undergoing lung transplantation.

**Material and Methods:** Retrospective analysis of the clinical processes of patients undergoing lung transplantation in Portugal between January/2008 and July/2016. Demographic and clinical data were analyzed from patients with documented fungal infection by bronchoalveolar lavage (BAL), bronchial lavage (LB) and bronchial biopsies (BB), during the first year after transplantation.

**Results:** During the referred period, 115 patients underwent lung transplant, of which 29 cases of fungal infection (25.2%) were identified. There were no significant differences between the infected and the remaining patients regarding diagnosis, demographic and intraoperative data. The mean age (SD) of infected patients was 45.2 (13.4) years, and 15 (51.7%) were female. The most frequent diagnoses were COPD (9 patients) and bronchiectasis (7 patients), of which 2 cases of cystic fibrosis. The main comorbidities identified were osteoporosis in 8 (27.6%) patients and hypertension in 6 (20.7%). In 24 cases the infection occurred in the first three months after LT, with a clear predominance of *Candida* spp infections (17, 70.1%). In the majority of cases (28, 96.6%) patients were under broad-spectrum antibiotic therapy when fungal infection was diagnosed, and in 10 (34.5%) cytomegalovirus infection was diagnosed during the first year. The radiological aspects were non-specific, ground-glass opacity (8, 27.5%), nodular infiltrates (5, 17.2%) and parenchymal consolidation (3, 10.3%) were the most frequent changes, but in 7 (24.1%) the exam was normal. The main isolated agents were *Candida* spp (20, 68.9%) and *Aspergillus* spp (8, 27.5%). In the case of *Candida* spp infections, the endoscopic findings were non-specific, with inflammatory changes in the mucosa present in 14 (70.0%) patients. In the case of infections with *Aspergillus* spp the alterations were mainly compatible with infection of the anastomosis (5, 71.4%). Two patients died from complications secondary to the diagnosis of fungal infection. In seven (24.1%) of these patients a diagnosis of chronic lung allograft rejection was performed during the period evaluated. Survival at 12 months for patients diagnosed with fungal infection was 72.4%, while it was 82.5% in the remaining population of transplanted patients.

**Conclusion:** The clinical and radiological non-specific aspects of fungal infections in patients undergoing lung transplantation make this diagnosis particularly challenging. Although there are identified risk factors, the analysis of this sample allowed us to highlight its limitations. The early recognition and approach of these infections is crucial, given the impact they have on morbidity and mortality associated with lung transplantation.

PE 082

**PULMONARY ABSCESS BY METHICILLIN-RESISTANT STAPHYLOCOCCUS AUREUS AS COMPLICATION OF PULMONARY THROMBOEMBOLISM - CASE REPORT**

R Carvalho, D Sousa, A Teixeira, F Silva, A Rodrigues

Centro Hospitalar e Universitário de Coimbra - Pólo Hospital Geral

Key-words: Pulmonary embolism, Deep vein thrombosis, May-Thurner syndrome, Pulmonary abscess, Methicillin-resistant *Staphylococcus aureus*

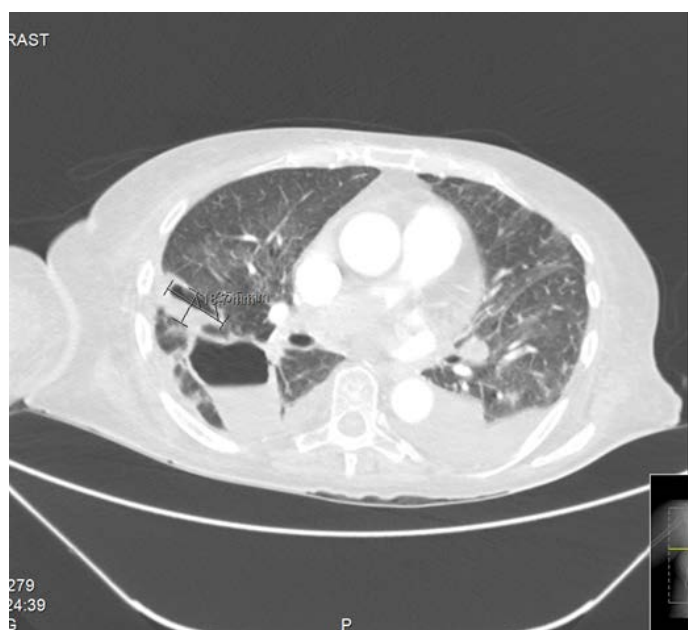
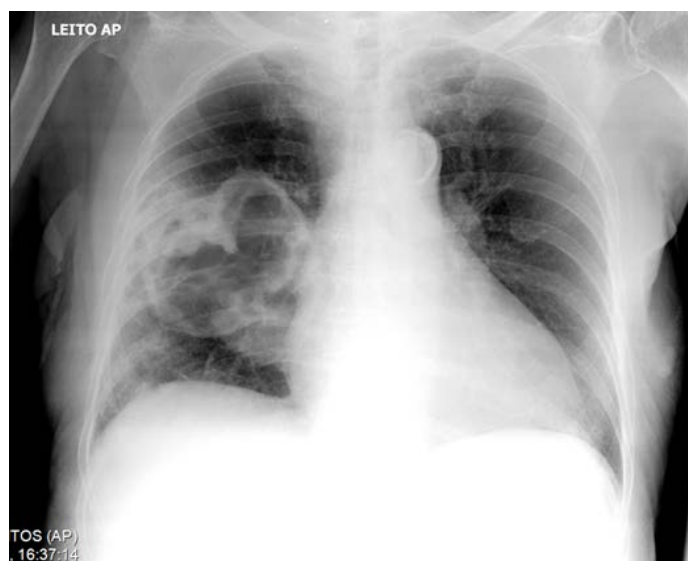
May-Thurner syndrome (MTS) is described in 20% of the population, but it's rarely considered when evaluating recurrent venous thromboembolism. It's characterized as a compression of the left common iliac vein (CIV) in its path between the right common iliac artery (CIA) and the lumbar spine. A pulmonary abscess is a subacute infection with 15-20% adult mortality, in particular when caused by *Staphylococcus aureus* (*S. aureus*). In the last decade, the frequency of *S. aureus* respiratory infections has increased, as well as the methicillin-resistant strains.

Relating to these conditions, the authors describe the following case report: an 85 years old female with a history of hospital admission with pulmonary embolism (PE) in October 2016 secondary to bilateral leg deep vein thrombosis (DVT). At admission to the emergency department, the patient had sudden dyspnea and hypoxemic respiratory insufficiency, requiring increasing supplementary oxygen. The Wells' Score was 4 (high probability of DVT) and the Geneva Score was 15 (high probability of PE). The laboratory data showed increased D-dimers (615 ng/mL) and the ecographic study showed left great saphenous vein, common femoral vein and external iliac vein DVT. The CT pulmonary angiography showed bilateral PE spreading to the inferior lobar arteries on both sides and to the right main pulmonary artery, findings previously not described. The patient also had a history of moderate tricuspid insufficiency resulting in cardiac insufficiency, moderate pulmonary hypertension, stage 3 chronic kidney disease and arterial hypertension. Chronically medicated with vafarin with an INR 2.44 at admission. Due to the patient's referred characteristics, laboratory studies were made for thrombophilia, autoimmunity and tumor markers, as well as a thoracic/abdominal/pelvic CT. Hyperhomocysteinemia was diagnosed and MTS was described on the CT.

The patient was admitted to the hospital ward and had a lengthy stay resulting from her previous conditions and the new event severity. On the 34<sup>th</sup> day of stay she had a deteriorating clinical state and was diagnosed with a right nosocomial pneumoniae, and empiric levofloxacin was started (5 days duration), with negative clinical progression. A right pulmonary cavity was identified on the new thoracic-CT with partial gaseous and liquid content, a probable infection by the methicillin-resistant *Staphylococcus aureus* newly isolated on the sputum culture. Because of clinical instability and elevated international normalized ratio, a bronchoscopy or a surgical procedure like a right pneumonectomy were contraindicated. The patient was diagnosed with a pulmonary abscess and started targeted therapy with linezolid and piperacillin/tazobactam. Pancytopenia and cholestatic hepatitis forced the stop of linezolid after 17 days and piperacillin/tazobactam after 24 days, respectively. Targeted cotrimoxazole was initiated, lasting for 25 days. The patient evolved positively with these antibiotics. The imagological reevaluation confirmed the reduction of the pulmonary cavitation.



Regarding MTS, systemic anticoagulation may be insufficient to prevent recurrent DVT, and the ideal therapy is still undetermined. Invasive procedures were contraindicated, so our patient didn't undergo angioplasty and stenting of the left CIV. She was discharged with apixaban 5mg q12h and there was no DVT recurrence after 3 months.



## PE 083

### WHEN PAIN IS THE KEY TO A DIAGNOSIS

**AD Cunha, M Conceição, JB Correia, T Abrantes, JP Silva, B Rodrigues, AS Torres**

Centro Hospitalar Tondela-Viseu, E.P.E.

Key-words: Pulmonary nocardiosis. Nocardia. Pulmonary adenocarcinoma. Silicosis.

**Introduction:** Pulmonary nocardiosis is an infection caused by Gram-positive aerobic bacilli of the genus *Nocardia*. It usually occurs in individuals with immunodeficiency and/or patients with structural lung disease. The clinical and radiological presentations are non-specific and highly variable, including nodules or masses (isolated or multiple), with or without cavitation, alveolar consolidation, pleural effusion or empyema.

**Case Report:** A 60-year-old male, former worker in a granite quarry, smoker (67 packs year) with history of chronic alcoholism. He was admitted in 2014 after presenting himself with a month-long cough and radiological changes. Thoracic computed tomography (CT) showed diffuse micronodules with predominance in the upper lobes, forming a fibrotic conglomerate at the right apex and calcified nodes at the mediastinum level. This finding was compatible with silicosis. The bronchoscopy results showed no endobronchial changes. The bronchoalveolar lavage (BAL) cytology was negative for neoplastic cells, and pulmonary tuberculosis was excluded. He missed the follow-up appointment.

Three years later, he was referred again to our hospital. At that time, he had been experiencing shoulder pain for a year, with progressive worsening, and unquantified weight loss. He also reported a small amount of mucous secretions, without cough or fever. Thoracic CT showed a heterogeneous mass with irregular contours (8.5x5.3x5 cm) located in the left upper pulmonary lobe and in close proximity to the pleura and upper costal arches. In the right upper lobe there was a cavitary lesion with irregular walls associated with architectural distortion. The remaining changes were similar to the previous study. Based on the clinical and radiological findings, he was admitted for complementary study and pain control.

Analytically, he presented with normochromic normocytic anaemia, elevation of inflammatory parameters and elevation of neuron-specific enolase (NSE) and carcinoembryonic antigen (CEA). During that time, he presented with fever, therefore empirical antibiotic therapy with ceftriaxone was instituted for 7 days.

A transthoracic biopsy was performed on the left upper lobe mass, and its result was compatible with pulmonary adenocarcinoma. The bronchoscopy result did not show significant changes in the tracheobronchial tree. Cytology was negative for neoplastic cells. The microbiological examination of the mini-BAL identified the presence of *Nocardia spp.* Both the mycobacterium tuberculosis polymerase chain reaction (PCR) assay and the acid-fast bacilli (AFB) smear microscopy were negative. It was started antibiotic therapy with cotrimoxazole and meropenem. Bone radiation therapy was also initiated to treat his symptoms.

**Discussion:** Nocardiosis is a rare bacterial infection, and it can occur in a widespread and potentially fatal form. In this case report, the patient experienced immunosuppression (history of chronic alcoholism and a recent diagnosis of lung adenocarcinoma). In addition, the existence of structural alterations on pulmonary parenchyma (silicosis) may have also contributed to the lodging and proliferation of pathogenic microorganisms. This case shows the importance of including nocardiosis in the differential diagnosis of pneumonia in patients with risk factors, especially when pneumonia is complicated by cavitation, abscess or necrosis.



PE 084

### RAMP: A MODE OF COMFORT OR CONFLICT?

C Maciel<sup>1</sup>, JS Silva<sup>2</sup>, RF Fonseca<sup>3</sup>, C Caneiras<sup>4</sup>, CM Esteves<sup>4</sup>

<sup>1</sup>Fisioterapeuta | PRAXAIR Portugal, Gases SA; <sup>2</sup>Enfermeira | PRAXAIR Portugal, Gases SA; <sup>3</sup>Cardiopneumologista | PRAXAIR Portugal, Gases SA; <sup>4</sup>Farmacêutica | PRAXAIR Portugal, Gases SA

Key words: Home Respiratory Care, Adherence to Therapy, Ramp.

**Introduction:** The monitoring follow-up of patients receiving continuous positive airway pressure therapy aims the adherence and maintenance of therapeutic efficacy, which should assume an relevant role in the field of Home Respiratory Care.

**Clinical Case 1:** Female, 57 years old, BMI = 34 kg / m<sup>2</sup>; Diagnosis of Obesity hypoventilation syndrome in 2014, with RDI of 74 events/h;

Starts Bilevel S (pressures 8/14) 30 min ramp (at 4 cmH<sub>2</sub>O) and nasal mask, in May 2014;

Adherence to therapy, with leakage and residual AHI controlled (residual AHI = 4.2 events / h), recognizing therapeutic benefits;

At the monitoring visit in May 2015, residual AHI = 20.3 events / h; Anamnesis in a home environment evidences recurrent urinary infection, with antibiotic therapy;

After the data collection of the equipment, several interruptions of the therapy with several ramp activations were identified whenever the sleep restarted (algorithm with watertight ramp), which caused alterations of the AHI. This situation was caused by the marked nocturnal resulting from the urinary infection.

The situation was reported to the physician and was suggested modification of the ramp to 5 min, which was accepted;

At the reassessment visit, after 15 days, normalization of AHI values (<5 events/h) was observed.

**Clinical Case 2:** Male, 80 years, BMI = 37 kg / m<sup>2</sup>;

Diagnosis of Overlap syndrome (OSAS, with AHI = 80 and COPD) and Obesity hypoventilation syndrome in 2016;

Treatment with Bi-level ST (EPAP 10 IPAP 24 and FR of 18 cpm Ti 1,2), with nasal interface since May 3, 2016;

In the telephonic follow-up, carried out in March 2017, the patient shows complaints, and is not undergoing therapy;

An additional home visit was made, with an attempt to adapt the facial interface, which was rejected;

The situation was reported to the physician, with a suggestion of 45-minute ramp programming (at 4 cmH<sub>2</sub>O), which was implemented; At the reassessment visit after 15 days, we observed a daily use of 6 hours and 32 minutes with recognition of therapeutic benefits.

**Conclusion:** An adequate articulation between patient, home care and physician assistant is extremely important in order to promote the adherence and to maintain therapeutic efficacy. To this, it may contribute to the activation or adequacy of the ramp function, which is used to start the treatment with a lower and more comfortable pressure, which gradually increases until the scheduled treatment pressure is reached.

PE 085

### TREATMENT OF CENTRAL SLEEP APNEA WITH SERVO-VENTILATION IN ARNOLD-CHIARI SYNDROME TYPE I - CLINICAL CASE

F Costa<sup>1</sup>, J Mendes<sup>1</sup>, J Moita<sup>2</sup>, L Batata<sup>2</sup>, M Braz

<sup>1</sup>Linde Saúde; <sup>2</sup>Centro de Medicina do Sono do Centro Hospitalar e Universitário de Coimbra

Key-words: Arnold-Chiari syndrome; Central Apnea; Servo Ventilation

Arnold-Chiari Syndrome is a congenital malformation of the central nervous system in which the brainstem and lower part of the cerebellum travel to the vertebral canal.

Arnold-Chiari syndrome type I is usually asymptomatic during childhood. When the symptoms appear, they are characterized mainly by headache and unstable ambulation. Treatment consists of spinal cord decompression surgery.

We report the case of a 51-year-old female with Arnold-Chiari Syndrome type I, who was treated in 2010. In 2016 she was directed to the Centro de Medicina do Sono do Centro Hospitalar e Universitário de Coimbra, with complaints of excessive daytime sleepiness, morning headaches and snoring.

Considering the clinical history, Polysomnography level I (PSG) was diagnosed with central sleep apnea syndrome, and the main evidences of the study were: respiratory distress index (RDI) 65.7 events / hour, Central events. The minimum oxygen saturation was 79% and nocturnal respiratory rate (RR) ranged from 5 to 8 cycles per minute.

The information of the first PSG resulted in the accomplishment of a second PSG with the aim of initiating ventilatory therapy. Ventilation was monitored with BIPAP ST in May 2016, with correction of respiratory events in that night. The parameters programmed in the equipment were an inspiratory airway positive pressure (IPAP) of 17 cmH<sub>2</sub>O, expiratory (EPAP) of 12 cmH<sub>2</sub>O, RR of 10 and inspiratory time (IT) of 1s.

In the follow-up visit to the first month of therapy by the clinical team of the Homecare Respiratory Company, an AHI averaged 59.2 events / hour, with respiratory events that were mostly non-obstructive. The patient presented difficulties in falling asleep, also referring to awakenings due to sensation of high pressure, despite having a therapeutic adherence of 5 hours and 13 minutes.

After completing diagnostic tests: TAC, echocardiogram, exercise test and new PSG, the therapy was re-evaluated and changed to servo-ventilation, with the following parameters: EPAPmin. 7cmH<sub>2</sub>O, EPAPmax. 9 cmH<sub>2</sub>O, RR 12 rpm, IT 1s, minimum support pressure (PS) of 0 cmH<sub>2</sub>O and maximum of 4cmH<sub>2</sub>O with IPAPmax. of 13 cmH<sub>2</sub>O.

With the adaptation of the servoventilation, the AHI was reduced to 12 events / hour, and some obstructive events were observed, with a decrease in the desaturations demonstrated by nocturnal oximetry. Increased adherence to therapy for 6 hours and 12 minutes. The patient reported decreased arousals due to high pressure sensation.

**Conclusion:** The clinical case suggests that the servo ventilation is effective in the treatment of respiratory events of central origin including the presented case.

We illustrate with this work the relevance of a multidisciplinary team and the relevant role that home respiratory care companies can have in monitoring patients and in the early identification of problems that require clinical and functional reevaluation.



PE 086

### SLEEP BREATHING DISORDERS DIAGNOSIS: FROM HOSPITAL TO HOME. EXPERIENCE OF VILA FRANCA DE XIRA HOSPITAL

D Grencho, C Pissarra, P Rosa

Hospital de Vila Franca de Xira, Unidade de Pneumologia

Key-words: Sleep portable monitoring, Sleep Study, Obstructive Sleep Apnea, Sleep Breathing Disorders

**Introduction:** The experience with the Sleep Portable Monitoring (SPM), have supported the increasing use in the Sleep Breathing Disorders (SBD) diagnosis, despite some reservations regarding these exams implicit in American Academy of Sleep Medicine (AASM) recommendations.

The sleep study level I (in lab polysomnography) remains the gold standard in Sleep breathing disorders diagnosis, but it is an extremely resource-consuming exam.

**Goal:** Evaluate the adequacy of the ESA in the sleep breathing disorders diagnosis, through the characterization of the sleep studies performed in Sleep Laboratory (LS) of Pneumology Unit, Hospital Vila Franca de Xira (HVFX).

**Methods:** Longitudinal cohort study, retrospective of all SPM performed between 30 March (the beginning of sleep lab activity) and 31 December of 2016, at HVFX Pneumology Unit. For data collection, all clinical processes and results of ESA were reviewed. ESA were performed with equipments Nox T3 (Level III) and Nox A1 (Level II) from NOX medical ®. The following variables were considered: anthropometric data, Epworth sleepiness scale (EPW), comorbidities, type of sleep study, quality and outcome of the study. The results are presented using descriptive statistics, using the program SPSS V 20.0. .

**Results:** A total of 389 exams were performed in 377 patients, 60% male, mean age 61.6 +/- 14 years, mean body mass index 34 +/- 7.4 kg / m2, mean cervical perimeter 40.7 +/- 4.9 cm, mean EPW 9 +/- 5, and 98% of the patients had at least one comorbidity. Were performed 284 level III and 93 level II studies, of which, it was necessary repeat 13, only 8 (2.1%) because of insufficient quality (4 level III and 3 level II). 59 exams were normal. The most frequent sleep disorder was OSA with an average Apnea-Hypopnea Index (AHI) of 22.3 +/- 22.7/hour (Severity classification according to AASM recommendations: 115 Mild (mean AHI 9 +/- 2, 8), 86 Moderate (mean AHI 21.4 +/- 4.2), 101 Severe (mean AHI 52.7 +/- 21.8). In 16 studies were found other sleep disorders. During the analysis period, 24 were performed 24 level I sleep tests (in a different hospital), corresponding to 6% of total sleep tests (level I, II and III).

**Conclusion:** The results of the ESA analyzed was enough for the diagnosis of SBD in the majority of cases with suspicion of this disorder. There was a need to repeat the examination for poor signal quality, in only a small number of exams. These results support the use of ESA for SBD diagnosis, admitting that this is the most suitable sleep test type in a General Hospital.

PE 087

### QUALITY OF LIFE IN PATIENTS WITH OBESITY-HYPOVENTILATION SYNDROME (OHS) WHO PERFORM NON-INVASIVE VENTILATION (NIV)

IS Pereira, A Alves, C Ribeiro, C Nogueira, D Ferreira, S Conde

Centro Hospitalar de Vila Nova de Gaia/Espinho

Key-words: Hypoventilation-obesity syndrome, non invasive ventilation, SRI, quality of life

**Introduction:** Hypoventilation-Obesity Syndrome (OHS) is defined as chronic alveolar hypoventilation characterized by diurnal hypercapnia (PaCO<sub>2</sub> > 45 mmHg) in an obese patient (BMI> 30 kg / m2) that cannot be attributed to other causes. OHS is associated with high morbidity and it is important to evaluate the quality of life of these patients after initiating NIV therapy to evaluate the efficacy of the treatment. The SRI (Severe Respiratory Insufficiency) quality of life questionnaires are validated to quantify the quality of life of patients with chronic respiratory failure.

**Objectives:** Evaluate the characteristics and quality of life of patients with OHS performing NIV who are in the NIV outpatient clinic.

**Methods:** SRI questionnaires were applied to patients with OHS that were stable who performed NIV for at least 3 months. The SRI quality of life questionnaire was designed to evaluate quality of life in different dimensions with percentage scores: respiratory complaints (8 questions) - SRI-RC, physical functioning (6 questions) - SRI-PF, attendant symptoms and sleep (7 questions) - SRI-AS, social relationships (6 questions) - SRI-SR, anxiety (5 questions) - SRI-AX, psychological well-being (9 questions) - SRI-WB, social functioning (8 questions) - SRI-SF. There are a total of 49 questions, in which the answers vary depending on whether the statement is appropriate for the patient's symptoms the previous week (completely untrue, mostly untrue, sometimes true, mostly true, always true). In the end, the average of the scores of each studied dimension (SRI-SS) is performed. A high score reflects a good quality of life.

**Results:** Twenty-three patients with OHS were included in the study with a mean age of 64.7 years. Only 17.4% were male and the mean BMI was 47.2 kg / cm2. They were performing NIV on an average of 72 months with an average daily use of 7.9 hours. Regarding the functional respiratory alterations, on average, FEV1 was 65% of the predictive value and the VFC was 76% of the predictive value.

The results obtained are given in table1:

Table 1 - Analysis of SRI results

Dimensions	Scores
SRI-RC	63.5
SRI-PF	41.6
SRI-AS	45.3
SRI-SR	73.0
SRI-AX	53.3
SRI-WB	54.2
SRI-SF	58.6
SRI-SS	55.6

SRI-RC -respiratory complains; SRI- PF - physical functioning; SRI-AS - attendant symptoms and sleep; SRI-SR - social relationships; SRI-AX - anxiety; SRI-WB - psychological well-being; SRI-SF - social functioning; SRI SS - average of scores



**Conclusion:** OHS is a chronic disease that has a great impact in the quality of life of patients. The lowest scores were observed in physical functioning and attendant symptoms and sleep. It is thus important to identify the main complaints and constraints of these patients for a multidisciplinary approach. The application of these questionnaires to patients with chronic respiratory failure that undergo NIV is essential to better understand the different pathologies and to promote a better medical care.

PE 088

### THE ROLE OF GENDER IN THE INTENSITY OF CLINICAL FOLLOW UP IN PATIENTS WITH APAP THERAPY

**M Guedes, S Guedes, J Pereira, MI Garcia**  
Linde Saúde, Lda.

Key-words: Obstructive Sleep Apnea Syndrome (OSA), adherence, gender, male, female

**Introduction:** Adherence to APAP therapy continues to be a challenge and is recognized as the major determinant of therapeutic efficacy. Evidence suggests substantial differences between genders in symptoms, diagnosis, and consequences of obstructive sleep apnea syndrome (OSA). While in men the symptoms are very typical, characterized by snoring, periods of apnea reported by the spouse and diurnal hypersomnia, in women the symptoms are more atypical such as fatigue, morning headaches, insomnia and depression. However, gender has not been proven as a predictor of adherence to APAP.

**Aim:** To evaluate if gender can lead to an increased need in clinical telephone contacts or home clinical follow up visits during the first month of APAP treatment.

**Methods:** In this retrospective study 568 patients were evaluated with sleep-disordered breathing that started APAP therapy between January and June 2017. The sample was divided into 2 groups by gender. The mean age was  $61 \pm 12$  years and 70.8% was male. Patients older than 18 years who started therapy with the same model of nasal interface, without humidification, were included. Patients that changed therapy or suspended treatment and restarted during the study period were excluded. The number of telephone clinical contacts urged by patient's need and home clinical visits during the first month of treatment were collected, in addition to the protocol follow up made by the homecare company.

**Results:** The mean age was  $61 \pm 12$  years (60 in men and 63 in women), 59% were 60 or more years and 70.8% were male. The female patients required a higher intensity of clinical telephone contacts ( $Q = 0.26$  vs  $0.16$ ,  $p \leq .05$ ) during the first month of therapy. However, women did not need more clinical home visits than men ( $Q = 0.06$  vs  $0.05$ ,  $p > .05$ ). Adherence to APAP was higher in patients of the male gender, 72% with more than 4 hours/night in at least 70% of nights (versus 66% in women), but did not have statistical significance.

**Conclusion:** In this study, female patients required a higher intensity of clinical contacts during the first month of APAP therapy in addition to the protocol interventions, although this does not translate into adherence differences between the two genders. Other variables may influence the observed differences, such as the fact that patients use different equipment and therapeutic pressures, the age of the patients or the social context. However, studies that identify these variables are important for more proactive actions in the clinical follow-up of these patients, more personalized and adapted to their needs.



PE 089

### **CAN PATIENT AGE INFLUENCE APAP THERAPY CLINICAL FOLLOW INTENSITY?**

**S Guedes, M Guedes, J Pereira, MI Garcia**

Linde Saúde, Lda.

Key-words: Obstructive Sleep Apnea Syndrome (OSA), prevalence, adherence, age

**Introduction:** Undiagnosed or untreated obstructive sleep apnea syndrome (OSA) is a current public health issue. APAP therapy compliance is a challenge that remains as the major determinant for therapeutic efficacy. Evidence acknowledges that older age can lead to an increase in OSA's prevalence. Additionally, in patients with apnea-hypopnea index (AHI)  $\geq 15$  events/h, disease prevalence in the general adult population can vary between 6% and 17%, reaching 49% in older ages. However, age has not consistently been demonstrated as a predictor of APAP compliance.

**Aim:** To evaluate if age can lead to an increase in the intensity of telephone or home visit clinical follow up in patients under APAP therapy during the first month of treatment.

**Methods:** This was a retrospective study that evaluated 568 patients with sleep respiratory disorders who initiated APAP therapy between January and June 2017. Inclusion criteria were patients older than 18 years who initiated therapy using the same nasal interface model, without humidification. Patients that changed therapy or that suspended and reinitiated treatment during the evaluated period were excluded. The sample was divided in 2 age groups (<60 years and  $\geq 60$  years). The number of telephone clinical contacts urged by patient's need and home clinical visits during the first month of treatment were collected, in addition to the protocol follow up made by the homecare company.

**Results:** Average patient age was  $61 \pm 12$  years, 59% of which were  $\geq 60$  years and 70.8% were male. Patients with  $\geq 60$  years showed an increased intensity in telephone clinical follow up ( $Q = 0,22$  vs  $0,14$ ,  $p \leq 0,05$ ) during the first treatment month. Regarding clinical home visits, no differences were observed between patients with  $\geq 60$  years when compared to the other group ( $Q = 0,04$  vs  $0,05$ ,  $p > 0,05$ ). Older patients ( $\geq 60$  years) evidenced statistically significant ( $p \leq 0,05$ ) higher therapy compliance (74% used APAP  $\geq 4$  h/night in 70% of the nights) when compared to younger ones (66% compliant).

**Conclusion:** This study suggests that, in this sample, older patients required a higher intensity in clinical follow up telephone calls, during the first therapy month, additional to the usual care protocol interventions. We also observed that patients with  $\geq 60$  years showed increased compliance to APAP therapy. Identified limitations are the use of different equipment models and therapy pressures. Nevertheless, the identification of these influencing variables can further contribute to drawing proactive and preventive measures, such as the establishment of customized care protocols adapted to patient needs.

PE 090

### **WHEN CHANGING THE VENTILATION MODE OPTIMIZES THERAPY**

**J Silva<sup>1</sup>, C Maciel<sup>2</sup>, F Morim<sup>3</sup>, C Esteves,<sup>4</sup> C Caneiras<sup>4</sup>**

<sup>1</sup>Rehabilitation Nurse | PRAXAIR Portugal, Gases SA; <sup>2</sup>Physiotherapist | PRAXAIR Portugal, Gases SA; <sup>3</sup>Neurophysiology Technician | PRAXAIR Portugal, Gases SA; <sup>4</sup>Pharmaceutical | PRAXAIR Portugal, Gases SA

Key-words: Home Respiratory Care, efficacy, adherence, ventilatory mode

**Introduction:** Those indicated for Bilevel Positive Airway Pressure (BiPAP) therapy are patients with respiratory insufficiency resulting either from Sleep Apnea-hypopnea Syndrome (SAHS), Obesity Hypoventilation Syndrome (OHS) or overlap Syndrome (SAHS association with other respiratory pathology), (DGS 2015). Understand that the quality of service provided by respiratory homecare companies should correspond to the level of medical knowledge and to promote articulation with medical services (primary and differentiated) in order to identify, at an early stage, compromising factors of the admission and its results.

**Methods and Results:** From January to June 2017, 37 individuals were followed with spontaneous (S) ventilatory mode therapy, with the aim of promoting adherence and therapeutic efficacy. At the domiciliary follow-up, 6 individuals (16.2%) with compromising factors of the effectiveness of the therapy were found, such as high residual AHI (average  $20,7 \pm 20,8$ ), oxygen desaturation index from nocturnal oximetry (average  $88,9 \pm 0,9$ ) and/or low adhesion to the Bipap treatment (average  $5,4 \pm 2,6$ ) that were identified and reported to the prescribing physician. Individuals had a mean age of  $68,7 \pm 7,5$ , and only 1 was male. All of these individuals began the therapy mode S, for the treatment of the underlying causes of respiratory insufficiency, with inhaling pressures between 19 cmH<sub>2</sub>O and 20 cmH<sub>2</sub>O and exhaling pressures between 4 cmH<sub>2</sub>O and 5 cmH<sub>2</sub>O.

After signaling, the ventilatory mode was changed from S to spontaneously-timed (ST), and no changes were made in the pressure. The applied support frequencies were between 12rpm and 17rpm. A new evaluation was made 1 month later and was identified a decrease in residual AHI (mean  $1,6 \pm 1,6$ ), an improvement of the nocturnal oxygen desaturation index (average  $93,7 \pm 1,8$ ) and an increase in adherence to Therapy (mean  $7,6 \pm 2,5$ ).

**Conclusion:** The home monitoring and careful analysis of the detailed data report, along with the anamnesis carried out in the regular monitoring held by the team of clinical professionals of the homecare respiratory companies, allows to identify and report to the prescriber any alteration that may compromise the efficiency and/or adhesion to the treatment.



PE 091

## A RARE CAUSE OF BRONCHIECTASIS: BASED ON A CASE REPORT

PI Pedro, L Ferraria, D Canário

Hospital Garcia de Orta

Key-words: primary ciliary dyskinesia, bronchiectasis, etiology

Primary ciliary dyskinesia (PCD) is a rare disease with an autosomal recessive inheritance pattern. The etiopathogenesis is characterized by structural and / or functional ciliary alterations that determine dysfunction of cilia mobility. The ineffectiveness of mucociliary clearance causes recurrent respiratory infections with a habitual progression to lung injury with bronchiectasis. The non-specific clinical and radiological manifestations determine the need for definitive diagnosis through electron microscopy or high speed videomicroscopy.

We present the case of a non-smoker 41-year-old male patient who was referred to Pneumology consultation at Hospital Garcia de Orta with the following medical history: bronchial asthma from childhood with clinical improvement during adolescence, but worsening since 2006; bronchiectasis diagnosed in 2006 with unexplained etiology, requiring lower left lobectomy in 2011; rhinosinusitis and chronic otitis media since childhood.

The patient reported progressive worsening of the usual productive cough with moderate volume of mucopurulent sputum, associated with exertion dyspnea (mMRC 3) and wheezing. He mentioned about 1 to 2 exacerbations of rhinosinusitis and / or otitis, and at least 2 exacerbations of bronchiectasis yearly. He was doing chest physiotherapy and inhaled bronchodilator and corticosteroid therapy.

Regarding social history, the patient had no children and haven't been studied to exclude the presence of infertility.

He performed pulmonary function testing that showed bronchial obstruction without responsiveness to bronchodilators. The computed tomography of the lung confirmed the presence of multiple bilateral varicose and cystic bronchiectasis, coexisting signs of mucoid impaction.

The patient had previously performed the following diagnostic evaluation: negative sweat test; alpha-1 antitrypsin levels, IgG, IgA and IgM immunoglobulins, and total serum IgE with normal values; negative skin sensitivity tests for respiratory allergens; and sinus CT scan showed bilateral chronic otitis media and total tympanomastoid opacity.

To justify this pulmonary and otorhinolaryngological alterations, ciliary abnormalities were suspected. Biopsy of the nasal mucosa was performed for analysis by electron microscopy which revealed non-ciliate paved epithelium, suggesting the need of a new sample. Bronchial biopsy was performed through videobronchofibroscope, and the microscopic analysis of the axoneme of cilia showed absence or anomalies of the internal dynein arms, compatible with loss of ciliary motility and the diagnosis of PCD. The patient was referred for follow-up at Hospital Pulido Valente. The authors wish to emphasize that, although uncommon, PCD can be responsible for 1-4% of bronchiectasis in the adult. Knowing that the pulmonary repercussion of the disease is of particular prognostic relevance, the main goal is to highlight the prevalent clinical features of PCD in order to promote clinical awareness and early recognition of the disease. In this clinical case, the involvement of other body systems, such as the upper respiratory tract, can help diagnostic suspicion.

PE 092

## SEVERE ASTHMA? IT'S "PEANUTS"...

T Sá<sup>1,2</sup>, V Caldeira<sup>1,2</sup>, D Silva<sup>1,2</sup>, R Coelho<sup>1,2</sup>, A Borba<sup>1,2</sup>, L Semedo<sup>1,2</sup>, J Cardoso<sup>1,2</sup>

<sup>1</sup>Serviço de Pneumologia, Hospital de Santa Marta, Centro Hospital de Lisboa Central, <sup>2</sup>NOVA Medical School Faculdade de Ciências Médicas, Universidade Nova de Lisboa, Lisboa

Key-words: Asthma, foreign body, bronchoscopy

**Introduction:** Asthma is a chronic inflammatory disease of the airways with high prevalence. Wheezing, dyspnea, chest tightness and cough with variable intensity are the cardinal symptoms of this disease. However, the accomplishment of a detailed clinical history and appreciation of the complementary diagnostic tests is crucial for the differential diagnosis of this pathology.

**Case report:** We report the case of a 44-year-old male, caucasian, non-smoker, without known allergies or exposure to respiratory pollutants, overweight (BMI 29) sent to the pulmonology clinic to evaluation of chronic cough symptoms.

The patients had no respiratory complaints until about 2 years ago, when he started complaining of wheezing, dyspnea, dry cough and rhinorrhea. Since then he was medicated with different bronchodilators and inhaled corticosteroids, reporting multiple episodes of exacerbation of respiratory complaints, requiring hospital emergency observations and systemic corticosteroid prescription.

When asked, the patient related the onset of respiratory symptoms with a choking episode and consequent apnea during the ingestion of peanuts. Associated with this episode, he presented abundant mucus expectoration and recurrent hemoptysis for approximately two days.

He also reported worsening of respiratory symptoms on days of higher humidity and lower temperature and trepopnea in right lateral decubitus.

The objective exam includes pulmonary auscultation with expiratory wheezes dispersed throughout the right hemithorax.

In the previous complementary diagnostic exams carried out, we valued respiratory functional test with mild obstructive lung defect, negative bronchodilation test and chest computed tomography with described reduction of the permeability of the right basal pyramid, namely the posterior and internal segments by the presence of reticular and micronodular pattern.

Taking into account the clinical history suggestive of foreign body aspiration, the images of computed tomography were re-assessed, identifying the presence of semi-circumferential foreign body with calcium density located in the intermediate bronchus. Flexible bronchoscopy was performed in which a foreign body (dry fruit shell) was visualized in the intermediate bronchus (dry fruit shell), with total occlusion of the bronchus. The object was removed with repermeabilization of the lumen and in this area there was granulation tissue with protrusion for the bronchial lumen.

The patient maintained follow-up and presented total resolution of the respiratory symptoms, allowing the suspension of the inhaled therapy. An endoscopic evaluation was performed after 3 months, which revealed a favorable evolution of the inflammatory alterations previously described.

**Conclusion:** Given its high prevalence, asthma should be considered a probable diagnosis in the presence of respiratory symptoms of bronchospasm with variable intensity. Although uncommon in adulthood, foreign body aspiration should be considered in the differential diagnosis of these patients, since their attempt diagnosis allows avoiding future complications.