

## Pulmonary calcified masses and gastric tumor: Incomplete Carney's triad



Dear Editor,

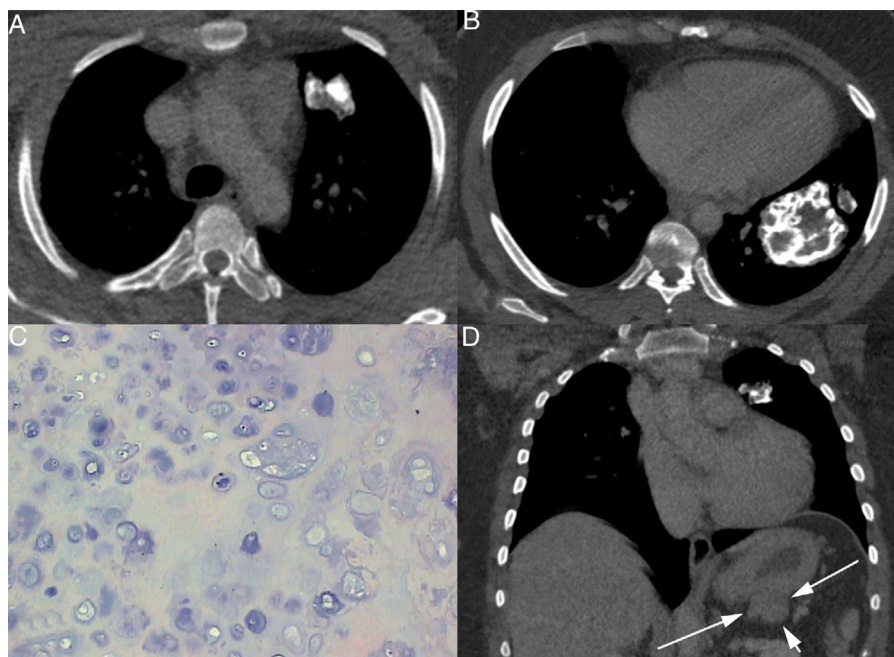
A 31-year-old woman presented with a 6-month history of dyspnea and posterior chest pain. Chest radiography demonstrated the presence of two round calcified pulmonary lesions. Results of physical examination and laboratory tests were normal. Chest computed tomography (CT) showed a well-circumscribed mass measuring  $6 \times 4$  cm and a nodule with a diameter of 3 cm, both heavily calcified (Fig. 1A and B). Thoracostomy was performed with pulmonary segmentectomy and resection of both lesions. Microscopically, the tumors corresponded to a benign cartilaginous neoplasm, compatible with chondroma (Fig. 1C). Abdominal CT showed an exophytic gastric lesion (Fig. 1D). Laparoscopy with gastric biopsy demonstrated that this lesion was a gastrointestinal stromal tumor (GIST). Total gastrectomy was performed. The patient was discharged in good condition. No evidence of recurrence was detected at a 3-year follow-up examination.

Carney triad is a rare syndrome that involves GIST, pulmonary chondroma, and extra-adrenal paraganglioma. The diagnosis of Carney's triad requires the presence of at least two of these three components. Most patients have two tumors on presentation, with the most frequent combination being GIST and pulmonary chondroma. This form of the disease is named "incomplete Carney triad."<sup>1-4</sup> Carney triad is generally accepted to be a genetic disorder, but not

a familial disease, as it is not passed on from generation to generation. The triad predominately affects females under the age of 30.<sup>1,2,4</sup>

Pulmonary chondromas of the Carney triad are well-differentiated benign cartilaginous tumors. However, presentation in a young woman suggests the possibility of the future development of additional tumors, indicating screening for the other features of the triad.<sup>2,5</sup> GISTs of the Carney triad are often multifocal, but occur only in the stomach. The initial symptoms are non-specific, including mainly abdominal pain, gastrointestinal bleeding, anemia, and weight loss. Gastroscopy with biopsy is the investigation of choice. Early surgery is desirable, as this tumor is insensitive to chemotherapy and radiotherapy.<sup>3</sup> Paragangliomas are rare neuroendocrine tumors arising from neural crest-derived chromaffin cells. Although paragangliomas may present anywhere along the sympathetic paraganglia chains from the neck to the pelvis, most reside intra-abdominally, in the superior para-aortic area. Most paragangliomas of the Carney triad are functional and become locally invasive. Patients with symptoms (e.g., hypertension, flushing, palpitations) and those with evidence of sympathetic dysfunction (e.g., urine catecholamine/metanephrine positivity) should be screened radiologically to determine paraganglioma location. Again, surgery is the best treatment.<sup>2,3</sup>

Because GIST and paraganglioma have malignant biological behaviors, affected patients must be monitored regularly to guard against recurrence and distant metastasis. Although disease progression is indolent, it is relentless, occurring despite chemotherapy and surgical treatment. Mortality in patients with the Carney triad can occur due



**Figure 1** Chest computed tomography shows a nodule with a 3-cm diameter (A) and a well-circumscribed mass measuring  $6 \times 4$  cm (B), both with coarse calcifications. Microscopically, the tumors correspond to a benign cartilaginous neoplasm composed of well-differentiated chondrocytes, compatible with chondroma (C). Abdominal computed tomography (D) demonstrates an exophytic lobulated mass in the gastric wall (arrows).

to gastrointestinal hemorrhage, metastatic disease, and hypertensive phenomena. Surgical resection is the only curative therapy for tumors related to the Carney triad.<sup>2</sup>

In conclusion, the Carney triad must be considered in patients with pulmonary chondromas. These patients should be followed closely and long term because it is presumed that they remain at risk of the development of other tumors.

### Conflicts of interest

The authors have no conflicts of interest to declare.

### References

1. Mydin HH, Kerr KM, Dempsey O. Calcified pulmonary chondromas in Carney's triad. *Thorax*. 2014;69:969–70.
2. Sawhney SA, Chapman AD, Carney JA, Gomersall LN, Dempsey OJ. Incomplete Carney triad – a review of two cases. *QJM*. 2009;102:649–53.
3. Bladen JC, Moosajee M, Bassett JH. A tense case – Carney's triad. *J R Soc Med*. 2004;97:540–1.
4. Qjao GB, Zeng WS, Peng LJ, Zhong WZ, Fang Y, Huang WJ, et al. Multiple pulmonary chondromas in a young female patient: a component of Carney triad. *Thorac Oncol*. 2009;4:751–2.
5. Rodriguez FJ, Aubry MC, Tazelaar HD, Slezak J, Carney JA. Pulmonary chondroma: a tumor associated with Carney triad and different from pulmonary hamartoma. *Am J Surg Pathol*. 2007;31:1844–53.

B. Hochegger<sup>a</sup>, S. Camargo<sup>a</sup>, E. Marchiori<sup>b,\*</sup>

<sup>a</sup> *Pavilhão Pereira Filho, Santa Casa de Misericórdia de Porto Alegre, Porto Alegre, Brazil*

<sup>b</sup> *Federal University of Rio de Janeiro, Rio de Janeiro, Brazil*

\*Corresponding author.

E-mail address: [edmarchiori@gmail.com](mailto:edmarchiori@gmail.com) (E. Marchiori).

<https://doi.org/10.1016/j.rppnen.2017.09.004>  
2173-5115/

© 2017 Sociedade Portuguesa de Pneumologia. Published by Elsevier España, S.L.U. This is an open access article under the CC BY-NC-ND license (<http://creativecommons.org/licenses/by-nc-nd/4.0/>).