

## LETTERS TO THE EDITOR

## Unusual late lung metastasis from leiomyosarcoma of the uterus



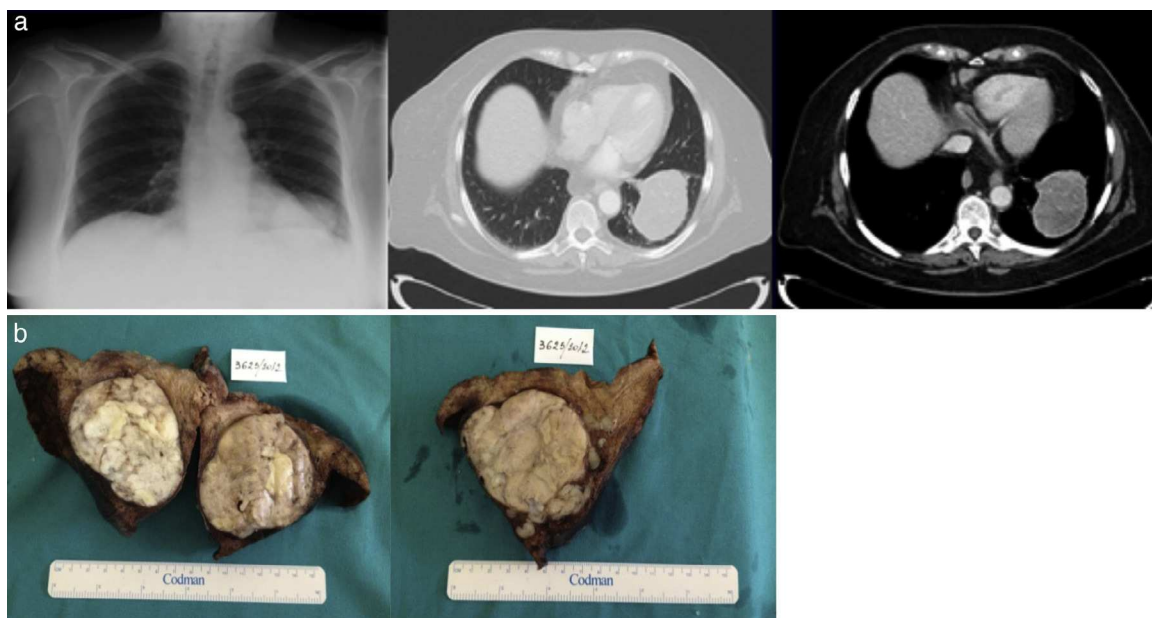
### Metástases pulmonares involgarmente tardias de leiomiossarcoma do útero

Uterine leiomyosarcoma (ULMS) is a rare condition, characterized by an aggressive behavior, with high rates of local recurrence and metastasis, leading to an early death.<sup>1–3</sup> The time interval to the detection of metastasis is typically short, although there are some reports of long periods, a fact that may complicate diagnosis.<sup>4</sup> We report an unusual case of a hysterectomized patient, who, as the result of a LMS, 26 years later presented lung metastasis.

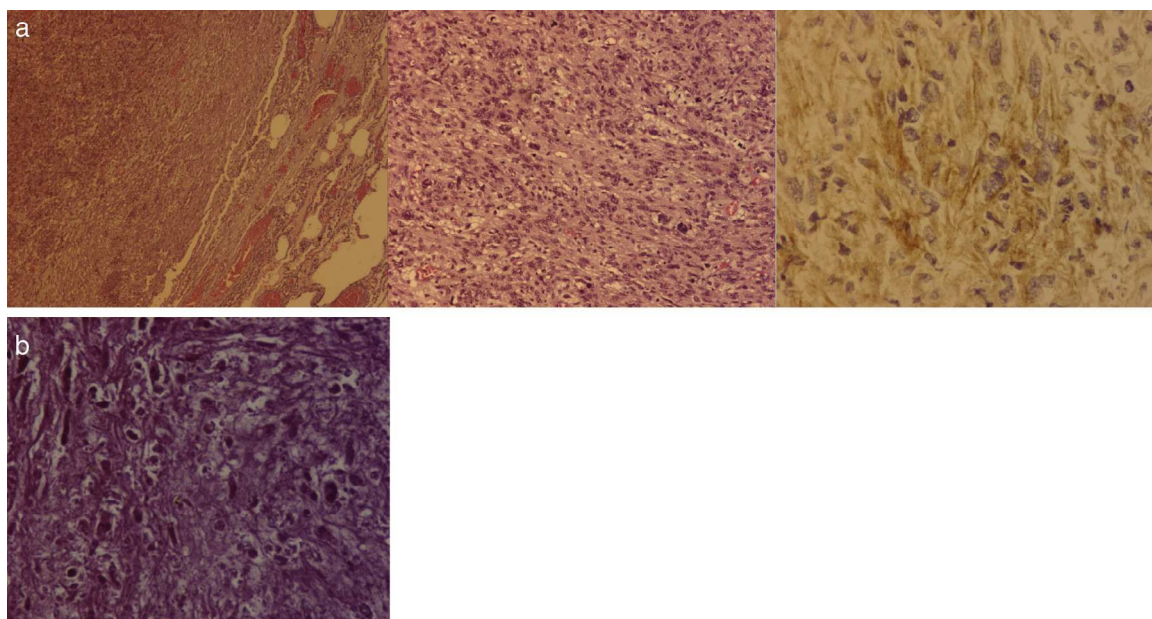
A 77-year-old woman, who had undergone hysterectomy for uterine myoma 26 years ago, was admitted to our institution for an abnormal shadow of greater density in the lower left lobe (LLL) on chest X-ray. Contrast-enhanced thoracic computed tomography showed an opacity with 6.7 cm in greatest dimension in the LLL, with relatively well-defined limits (Fig. 1a). No other distant metastasis or local

recurrence was found. The mass was subsequently removed by lower left lobectomy (Fig. 1b). Histopathological examination revealed smooth muscle cells with nuclear atypia and mitotic activity compatible with high-grade pleomorphic LMS (Fig. 2a). When the patient's history of hysterectomy for myoma was taken into account, the hypothesis of a lung metastasis of ULMS was considered during the diagnosis. Fortunately, it was possible to review the slides of the uterine tumor resected (Fig. 2b). It all led to the conclusion that the morphologies were similar and the uterine neoplasm was considered a high-grade LMS. Thus, based on the past medical history and histologic similarity, she was diagnosed with ULMS metastasis. The patient was hospitalized for respiratory infection and disease progression, with a worsening of the performance status, so she did not start chemotherapy, as planned. She died 3 months later.

The usual appearance of a lung metastasis is characterized by a large number of nodules, but the unilateral location of a mass does not rule out metastatic disease, as in this case. Lung metastasis often emerges soon after or even before the primary tumor is diagnosed. Nevertheless, metastasis may develop after a long tumor-free interval. The disease-free interval for the present case was 26 years,



**Figure 1** (a) Chest X-ray, contrast-enhanced thoracic computed tomography. (b) Macroscopic appearance.



**Figure 2** (a) Densely cellular tumor; cellular pleomorphism; by immunocytochemistry, the neoplastic cells express smooth muscle differentiation markers ( $\alpha$ -actin). (b) Uterine tumor with pleomorphic nuclei with variable and bizarre size and shape. Some spindle smooth cells (upper left) and necrosis signs (center).

which was, to the best of our knowledge, the longest reported so far. Dios et al. have described a case of 21 years disease-free interval.<sup>5</sup> Therefore, the chronicity of the disease must not lead us to ignore past clinical history, such as hysterectomy. The reason why these tumors have such a long free-disease interval remains uncertain and should be investigated. As suggested by this report, a long-term follow-up is necessary in the case of ULMS. A high level of suspicion of lung metastasis is essential when a pulmonary lesion is detected, despite the fact that such situations are so rare.

### Ethical disclosures

**Protection of human and animal subjects.** The authors declare that no experiments were performed on humans or animals for this study.

**Confidentiality of data.** The authors declare that they have followed the protocols of their work center on the publication of patient data.

**Right to privacy and informed consent.** The authors have obtained the written informed consent of the patients or subjects mentioned in the article. The corresponding author is in possession of this document.

### Authorship

Alexandra Carreiro collected and analyzed data and drew up the draft manuscript. Other authors collaborated in the writing of this paper.

### Conflicts of interest

The authors have no conflicts of interest to declare.

### References

1. Salazar O, Bonfiglio T, Pattern S, Keller B, Teldstein M, Dunne M, et al. Uterine sarcomas, natural history, treatment and prognosis. *Cancer*. 1978;42:1152–60.
2. Ip PPC, Cheung ANY. Pathology of uterine leiomyosarcomas and smooth muscle tumors of uncertain malignant potential. *Best Pract Res Clin Obstet Gynaecol*. 2011;691–704.
3. Pautier P, Genestic C, Rey A, Morice P, Roche B, Lhommé C, et al. Analysis of clinicopathologic prognostic factors for 157 uterine sarcomas and evaluation of a grading score validated for soft tissue sarcomas. *Cancer*. 2000;88:1425–31.
4. Donath J, Chawla K, Mehra S, Azueta V. Unilateral giant lung metastasis of uterine leiomyosarcoma: diagnostic pitfalls in an unusual case. *J Natl Med Assoc*. 1986;78.
5. Dios A, Felip C, Cros J, Pérez J. Leiomiomasarcoma pulmonar 21 años después de una hysterectomia por leiomiomasarcoma uterino: metástases tardías? *Med Clin*. 1999;113.

A. Carreiro<sup>a,\*</sup>, L. Frias<sup>b</sup>, A. Miguel<sup>b</sup>, M. Rocha<sup>c</sup>, V. Carneiro<sup>d</sup>, C. Pavão<sup>b</sup>

<sup>a</sup> *Pulmonology Resident, Pulmonology Department, Hospital do Divino Espírito Santo, E.P.E., Ponta Delgada, Portugal*

<sup>b</sup> *Pulmonology Graduated Assistant, Pulmonology Department, Hospital do Divino Espírito Santo, E.P.E., Ponta Delgada, Portugal*

<sup>c</sup> *Internal Medicine Assistant, Internal Medicine Department and Oncologic Medicine Unit, Hospital do Divino Espírito Santo, E.P.E., Ponta Delgada, Portugal*

<sup>d</sup> *Pathological Anatomy Graduated Assistant, Pathological Anatomy Department, Hospital do Divino Espírito Santo, E.P.E., Ponta Delgada, Portugal*

Corresponding author.

E-mail address: [alexandracarreiro@hotmail.com](mailto:alexandracarreiro@hotmail.com) (A. Carreiro).

<http://dx.doi.org/10.1016/j.rppneu.2014.02.008>