

Artigo de Revisão

Revision Article

Nuno A A Castelo Branco¹
José Reis Ferreira²
Mariana Alves-Pereira³

O aparelho respiratório na doença vibroacústica: 25 anos de investigação

Respiratory pathology in vibroacoustic disease: 25 years of research

Recebido para publicação/*received for publication*: 06.02.28
Aceite para publicação/*accepted for publication*: 06.11.10

Resumo

Enquadramento: A patologia respiratória induzida pela exposição a ruído de baixa frequência (RBF, ≤ 500 Hz, incluindo os infra-sons) não constitui novidade dado que, desde 1960, no âmbito dos programas espaciais dos EUA e da União Soviética, diversos autores divulgaram a sua existência. No contexto da doença vibroacústica (VAD – *vibroacoustic disease*), uma patologia sistémica causada pela exposição excessiva a RBF, as lesões respiratórias apresentam características próprias. Inicialmente, esta patologia respiratória não foi tida como uma consequência da exposição ao ruído; no entanto, hoje, o RBF é considerado um agente muito importante de doença respiratória. O objectivo deste trabalho é sistematizar e actualizar todos os dados sobre a patologia respiratória observada na VAD. **Métodos:** Ao longo dos últimos 25 anos, recolheu-se informação, de modo continuado, de indivíduos e modelos animais expostos a RBF. Todos estes dados são aqui compilados. **Resultados:** Em indivíduos expostos a ruído no trabalho, as queixas brônquicas

Abstract

Background: Respiratory pathology induced by low frequency noise (LFN, < 500 Hz, including infrasound) is not a novel subject given that in the 1960's, within the context of U.S. and U.S.S.R. Space Programs, other authors have already reported its existence. Within the scope of vibroacoustic disease (VAD), a whole-body pathology caused by excessive exposure to LFN, respiratory pathology takes on specific features. Initially, respiratory pathology was not considered a consequence of LFN exposure; but today, LFN can be regarded as a major agent of disease that targets the respiratory system. The goal of this report is to put forth what is known to date on the clinical signs of respiratory pathology seen in VAD patients. **Methods:** Data from the past 25 years of research will be taken together and presented. **Results:** In persons exposed to LFN on the job, respiratory complaints appear after the first 4 years of professional activity. At this stage, they disappear during vacation periods or when

¹ Médico Anatomopatologista, presidente do Conselho Científico, Centro da Performance Humana, Alverca

² Médico Pneumologista, Unidade de Estudo Funcional Respiratório, Hospital da Força Aérea, Lisboa

³ Engenheira Biomédica, ERISA – Universidade Lusófona, vibroacoustic.disease@gmail.com

aparecem nos primeiros 4 anos de actividade e, nesta fase, reduzem ou desaparecem quando de férias ou removidos do seu local de trabalho por outros motivos. Com a exposição prolongada, poderão surgir situações mais graves, como derrames pleurais, insuficiência respiratória, fibrose pulmonar e carcinomas do aparelho respiratório. Não existe correlação com hábitos tabágicos. Em modelos animais expostos a RBF, apresentavam-se alterações morfológicas da pleura e perda da capacidade fagocítica das células mesoteliais (explicando os derrames pleurais observados). Foram observadas lesões de fibrose e neovascularização ao longo de todo o aparelho respiratório dos animais expostos. Também se identificaram lesões pré-malignas, metaplasia e displasia. **Conclusões:** O RBF é um agente de doença e tem como alvo preferencial o aparelho respiratório. A patologia respiratória associada à VAD necessita, ainda, de muito estudo para que uma maior compreensão possa ser alcançada e intervenções farmacológicas possam ser pensadas.

Rev Port Pneumol 2007; XIII (1): 129-135

Palavras-chave: Ruído de baixa frequência, infra-sons, fibrose, derrame pleural, broncoscopia, cancro do pulmão, sensibilidade ao CO₂.

the person is removed from his /her workstation for other reasons. With long-term exposure, more serious situations can arise, such as, atypical pleural effusion, respiratory insufficiency, fibrosis and tumours. There is no correlation with smoking habits. In LFN-exposed animal models, morphological changes of the pleura, and loss of the phagocytic ability of pleural mesothelial cells (explaining the atypical pleural effusions). Fibrotic lesions and neo-vascularization were observed along the entire respiratory tract. Fibrosis lesions and neovascularisation were observed throughout the respiratory tract of the animals seen. Pre-malignant lesions, metaplasia e displasia, were also identified. **Discussion:** LFN is an agent of disease and the respiratory tract is one of its preferential targets. The respiratory pathology associated with VAD needs further in-depth studies in order to achieve a greater understanding, and develop methods of pharmacological intervention.

Rev Port Pneumol 2007; XIII (1): 129-135

Key-words: Low frequency noise, infrasound, fibrosis, pleural effusion, bronchoscopy, lung cancer, respiratory drive.

Introduction

Noise-induced respiratory pathology is not a new subject. In the 1960's, within the scope of North American and Soviet space programs, the effects of noise on the respiratory system were studied in humans and in dogs.

The human study, conducted by Mohr *et al.*, showed that short-term exposure (1-2 minutes) to very large amplitude (95-140 dB) low frequency noise (30-100 Hz) produced chest

wall vibration, interference with normal breathing, throat fullness, cough and gagging sensation¹. In dogs, Ponomarkov *et al.* showed that 1.5-2 hrs of wide-band noise exposure (105-155 dB) produced haemorrhages in the lungs (3 mm diameter), caused by ruptured capillaries and larger vessels. They also found stretching of the connective-tissue structures of the alveolar walls, and compression of lung tissue. The most interesting observation was that as the dB

level of the noise increased, the number of haemorrhage spots increased, but they never exceeded 3mm in diameter. These lesions were always more numerous in the upper lobe of the right lung².

Cohen described respiratory system complaints in boiler-plant workers, after the implementation of hearing protection program in 1976, as coughing, congestion in head and chest, shortness of breath, and hoarseness³. In 1987, Svigovyi et al. investigated the effects of infrasound (2-16 Hz at 90-140 dB) on the pulmonary ultrastructure of white mice, for 1-40 days. After 3 hrs of exposure, "point, mosaic-type" haemorrhages were identified over the entire lung surface. Haemorrhaging increased with exposure time: after 10-15 days of exposure, parts of the lung tissue were filled with blood and the walls between alveoli were swollen and thick. Dramatic morphological changes of alveolar, cellular and blood vessel structures were observed after 24-40 days of exposure⁴.

In Portugal, the biological effects of LFN exposure have been the object of investigation since 1980 and, as a consequence, vibroacoustic disease (VAD) has been defined as a systemic pathology, characterized by the abnormal proliferation of collagen and elastin, as caused by excessive exposure to low frequency noise (LFN) (<500 Hz, including infrasound)⁵⁻⁷. The goal of this report is to describe the respiratory features observed in VAD patients and in LFN-exposed animal models.

Methods

VAD studies began within the aeronautical industry^{5,7} where respiratory pathology observed among aeronautical technicians was initially disregarded because of the large va-

riety of other respiratory aggressors present in this occupational environment, such as chemical compounds and dusts. However, when significant tracheal, pulmonary and pleural changes were observed in LFN-exposed animal models, the respiratory complaints of LFN-exposed workers were interpreted in a new light. This report is a compilation of all data obtained to date, thus individual methodologies are described in each original study, and will not be repeated herein.

Results

After 1-4 years of occupational exposure to LFN, aircraft technicians developed bronchitis, repeated infections of the oropharynx, and non-productive cough, in both smokers and non-smokers alike⁷. These complaints usually disappeared after vacation or removal from the LFN-rich work environment. Asthma-like situations were also common, however they did not respond to the usual therapeutics. In older workers, several cases of atypical pleural effusion appeared, but of unknown aetiology, with unusually prolonged recovery times and unresponsive to the standard therapeutics⁷. Autopsy findings in a deceased VAD patient also disclosed unexpected lung fibrosis which, at the time, was attributed to the existence of airborne chemicals and dusts, present in this man's occupational environment⁸.

The unusual and atypical cases of pleural effusion prompted the first animal model studies, where Wistar rats were exposed to LFN on an occupationally-simulated schedule – 8 hours/day, 5 days/week, and weekends in silence. Pleural milky spots, or Kampmeir's foci, are cellular structures responsible for mounting immune responses. In LFN-ex-

posed rats, these structures were damaged, and their phagocytic ability was severely impaired⁹. Simultaneously, pleural morphology was also altered, which translated into kinetic changes in absorption and drainage of lung particulates, with consequent impairment of well-known drug therapeutics pathways¹⁰. These results explained the atypical cases of pleural effusion.

During the slicing of pleural tissue samples, a deeper than desired cut was made, and electron microscopy imaging captured portions of the lung. These disclosed the existence of lung fibrosis in LFN-exposed rats¹¹. Tracheal images also disclosed large and highly unusual amounts of fibrosis¹². Rats were not exposed to chemical nor dusts and, of course, they were non-smokers. Taken together with the autopsy finding of lung fibrosis in a deceased VAD patient⁸, these results led to the study of pulmonary fibrosis in VAD patients through high-resolution CT scan of the lung. Indeed, pulmonary fibrosis was identified in these individuals¹³. Interlobular septal thickening, ground-glass appearances, as well as air-trapping were also a common radiological finding in these patients. Pulmonary functional tests, however, were normal. A statistically significant relationship was identified between individuals who had respiratory complaints and the presence of abnormal radiological imaging¹³. The morphological changes observed in the tissue structures of the respiratory epithelium of LFN-exposed rat have led to a plethora of studies¹⁴⁻¹⁹ (most recent). Destruction of tracheal ciliary populations, fusion of brush cell microvilli, and cell swelling are commonly seen after LFN-exposure. Fibrosis and neo-vascularization are seen along the entire respiratory tract. The atypical cases of

pleural effusion were explained by the morphological changes of the pleura, and loss of the phagocytic ability of pleural mesothelial cells. One of the most important and surprising features was the identification of pre-cancerous lesions, in the form of metaplasia and dysplasia.

Respiratory tract cancer has not been an uncommon development in VAD patients. To date, 11 cases of respiratory tract tumours have been studied in these patients: 9 in the lung and 2 in the glottis¹⁹. There are two features in VAD respiratory tract cancer cases that cannot be ignored: a) all lung tumours are located in the right lobe, and b) all tumours are of one single type – squamous cell carcinomas. Of these 11 cases, 3 were non-smokers, of which 2 had lung tumours and 1 had a glottis tumour. All but 2 of these 11 patients are deceased. The 2 survivors are still heavy smokers but are no longer exposed to occupational LFN.

Given the pathology observed in the respiratory tract of both VAD patients and LFN-exposed animal models, taken together with the neurological abnormalities also observed among these patients, it became pertinent to investigate the status of the neurological control of breathing, i.e., the ability to hyperventilate in the presence of excessive CO₂. Recent studies demonstrate that this ability is severely impaired in VAD patients, despite normal pulmonary function tests²⁰. This feature is more related to the possible existence of lesions in the brainstem respiratory centres, as already confirmed by the abnormal values of brainstem auditory evoked potentials in these patients²¹.

The most recent study related to respiratory tract pathology in VAD patients is a highly invasive procedure that is only offered to

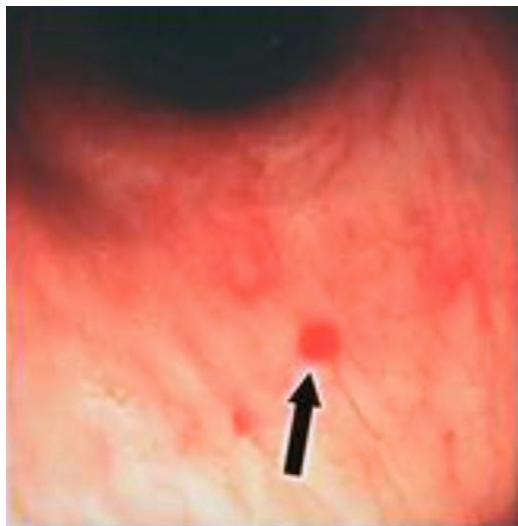


Fig. 1 – Lesioned areas as seen through bronchoscopy

volunteer patients, for legal and forensic purposes: bronchoscopy. This examination has led to the discovery of small, vascular-like lesions in both tracheal and bronchial trees, and uniformly distributed bilaterally near the spurs²² (See Fig. 1). Biopsies of these areas were taken and revealed morphological changes similar to those already seen in LFN-exposed rats.

Discussion

Respiratory tract pathology caused by excessive LFN-exposure is a fact that has been demonstrated since the 1960's. It is often believed that respiratory pathology is exclusively caused by inhalation of foreign substances, such as smoke, chemical compounds and dusts. This is an untenable position given what is known to date on noise-exposure and the appearance of respiratory tract pathology. At best, air pollutants have been pointed out as possible confounding factors in noise-induced health effects²³. There is an explicit clinical picture associa-

ted with LFN-induced respiratory complaints/pathology. Moreover, if questions arise regarding the aetiology of the respiratory tract pathology, LFN can be assessed as the culprit using other diagnostic tests that are VAD-specific.

Perhaps, noise should be regarded as a confounding factor in mainstream respiratory tract studies. Lung cancer studies are the most obvious. In all VAD patients who suffered respiratory tract tumours, only one single type of tumour was identified: the squamous cell carcinoma. Concurrently, pre-cancerous tissues were observed in respiratory tract squamous-cells of LFN-exposed rats. Taken together, these are highly significant findings. Nevertheless, most large-scale lung cancer studies do not identify separate tumour-types and, of course, do not consider LFN-exposure as a causative factor. These data bring significant implications in litigation, where lung cancers are claimed to be caused by agents other than LFN exposure.

The fact that all VAD patients' lung cancer appear in the right lobe, added to the fact that Ponomarkov's noise-exposed dogs presented more lesions in the upper right lobe² suggests that a biomechanical factors may play an important role in the development LFN-induced respiratory pathology. Considering the lungs as two suspended sacs of air that are under vibratory stress due to LFN-induced vibration, then the right lung would be expected to suffer a different quality of LFN-induced vibratory stress because of the relative position of the cardiac mass adjacent to the left lobe. Concurrently, new models of cells, based on tensegrity structures (24-26, for example) can also explain many features seen in VAD-related respiratory pathology²⁷.

Conclusions

The production of LFN in everyday society is not controlled by legislation. Thus, the amounts of LFN exposure suffered by the average individual have greatly increased over the past 4 decades. Hence, the worldwide increase in respiratory pathology may not be only related to decreased air quality. Lung cancer is commonly associated with smoking habits, however, the data presented herein forcefully challenge this notion. Scientists should re-evaluate their study designs so that LFN-exposure histories are taken into account, and LFN is not maintained as a contaminant factor. Finally, respiratory complaints, particularly in children, should be viewed with a high degree of suspicion as to their origin. LFN is an agent of disease with the respiratory tract being a preferential target.

Acknowledgements

The authors would like to thank all patients who have voluntarily contributed their time to our studies

Bibliography

1. Mohr GC, Cole JN, Guild E, Von Gierke HE. Effects of low-frequency and infrasonic noise on man. *Aerospace Med* 1965; 36: 817-24.
2. Ponomarkov VI, Tysik Ayu, Kudryavtseva VI, Barer AS, *et al.* Biological action of intense wide-band noise on animals. *Problems of Space Biology NASA TT F-529* 1969; 7:307-9.
3. Cohen A. The influence of a company hearing conservation program on extra-auditory problems in workers. *J Safety Res* 1976; 8:146-62.
4. Svirgovyi VI, Glinchikov VV. The effect of infrasound on lung structure. *Gig Truda Prof Zabol* 1987; 1: 34-7.
5. Castelo Branco NAA, Alves-pereira M. Vibroacoustic disease. *Noise & Health* 2004; 6(23):3-20.
6. Castelo Branco NAA, Rodriguez Lopez E. The vibroacoustic disease – An emerging pathology. *Aviat Space Environ Med* 1999; 70(3, Suppl):A1-6.
7. Castelo Branco NAA. The clinical stages of vibroacoustic disease. *Aviat Space Environ Med* 1999; 70(3, Suppl):A32-9.
8. Castelo Branco NAA. A unique case of vibroacoustic disease. A tribute to an extraordinary patient. *Aviat Space Environ Med* 1999; 70(3, Suppl):A27-31.
9. Oliveira MJR, Sousa Pereira A, Águas AP, Monteiro E, Grande NR, Castelo Branco NAA. Effects of low frequency noise upon the reaction of pleural milky spots to mycobacterial infection. *Aviat Space Environ Med* 1999; 70(Suppl):A137-40.
10. Sousa Pereira A, Grande NR, Castelo Branco MSN, Castelo Branco NAA. Morphofunctional study of rat pleural mesothelial cells exposed to low frequency noise. *Aviat Space Environ Med* 1999; 70(3, Suppl):A78-85.
11. Grande N, Águas AP, Sousa Pereira A, Monteiro E, Castelo Branco NAA. Morphological changes in the rat lung parenchyma exposed to low frequency noise. *Aviat Space Environ Med* 1999; 70(3, Suppl):A70-7.
12. Sousa Pereira A, Águas A, Grande NR, Castelo Branco NAA. The effect of low frequency noise on rat tracheal epithelium. *AviatSpace Environ Med* 1999; 70(3, Suppl):A86-90.
13. Reis Ferreira JM, Couto AR, Jalles-Tavares N, Castelo Branco MSN, Castelo Branco NAA. Airflow limitations in patients with vibroacoustic disease. *Aviat Space Environ Med* 1999; 70(3, Suppl):A63-9.
14. Castelo Branco NAA, Alves-Pereira M, Martins dos Santos J, Monteiro E. SEM and TEM study of rat respiratory epithelia exposed to low frequency noise. *In: Science and Technology Education in Microscopy: An Overview*, A. Mendez-Vilas (Ed.), Formatex: Badajoz, Spain, 2002; II:505-33.
15. Castelo Branco NAA, Monteiro E, Costa e Silva A, Reis Ferreira J, Alves-Pereira M. Respiratory epithelia in Wistar rats born in low frequency noise plus varying amounts of additional exposure. *Rev Port Pneumol* 2003; IX(6):481-492.
16. Castelo Branco NAA, Gomes-Ferreira P, Monteiro E, Costa e Silva A, Reis Ferreira J, Alves-Pereira M. Respiratory epithelia in Wistar rats after 48 hours of continuous exposure to low frequency noise. *Rev Port Pneumol* 2003; IX(6):473-479.
17. Castelo Branco NAA, Monteiro E, Costa e Silva A, Reis Ferreira J, Alves-Pereira M. The lung parenchyma in low frequency noise exposed rats. *Rev Port Pneumol* 2004; X(1): 77-85.

18. Alves-Pereira M, Reis Ferreira J, Joanaz de Melo J, Motylewski J, Kotlicka E, Castelo Branco NAA. Noise and the respiratory system. *Rev Port Pneumol* 2003; IX(5):367-79.
19. Mendes CP, Reis Ferreira J, Alves-Pereira M, Castelo Branco NAA. Vibroacoustic disease and respiratory pathology I – Tumours. *Proc Internoise 2004*; Prague, Czech Republic, Aug 22-25: No. 636 (5 pages).
20. Reis Ferreira J, Mendes CP, Antunes M, Martinho Pimenta AJF, Monteiro E, Alves-Pereira M, Castelo Branco NAA. Diagnosis of vibroacoustic disease – preliminary report. *Proc 8th Intern Cong Noise as a Public Health Problem*, July, Rotterdam, Holland: 112-4, 2003.
21. Marvão JH, Castelo Branco MSN, Entrudo A, Castelo Branco NAA. Changes of the brainstem auditory evoked potentials induced by occupational vibration. *J Soc Ciências Med* 1985; 149: 478-486. (Recipient of the 1984 Ricardo Jorge National Public Health Award.)
22. Monteiro MB, Reis Ferreira J, Mendes CP, Alves-Pereira M, Castelo Branco NAA. Vibroacoustic disease and respiratory pathology III – Tracheal and bronchial lesions. *Proc Internoise 2004*, Prague, Czech Republic, August 22-25: No. 638 (5 pages).
23. Schwela D, Kephelopoulos S, Prasher D. Air pollutants and other stressors as confounding or aggravating factors in noise –induced health problems. *Proc Internoise 2004*, Prague, Czech Republic, August 22-25: No. 519 (10 pages).
24. Ingber, DE. Mechanobiology and diseases of mechanotransduction, *Ann Med* 2003; 35:1-14. <http://web1.tch.harvard.edu/research/ingber/homepage.htm>
25. Ingber DE. Mechanochemical basis of cell and tissue regulation. *NAE Bridge* 2004; 34(3):4-10. <http://www.nae.edu/NAE/bridgecom.nsf/weblinks/MKEZ65RHQL?OpenDocument>
26. Alenghat FJ, Nauli SM, Kolb R, Zhou J, Ingber DE. Global cytoskeletal control of mechanotransduction in kidney epithelial cells. *Exp Cell Res* 2004; 301:23-30.
27. Alves-Pereira M, Castelo Branco NAA. Vibroacoustic disease: biological effects of ultrasound and low frequency noise explained by mechanotransduction cellular signalling. *Prog Biophy Molec Biol* 2006 (accepted for publication).