

Caso Clínico

Clinical Case

Arthur Soares Souza Jr.¹
Edson Marchiori²
Patrícia Maluf Cury³
Emerson L. Gasparetto⁴
Dante L. Escuissato⁵

Schistosomíase pulmonar aguda: Correlação entre a tomografia computadorizada de alta resolução e os achados anatomopatológicos

Acute pulmonary schistosomiasis: Correlation between the high-resolution CT and pathological findings

Recebido para publicação/received for publication: 06.12.04

Aceite para publicação/accepted for publication: 07.03.26

Resumo

Paciente masculino, de 35 anos, trabalhador rural, apresentando-se com história de dispneia progressiva, tosse seca, mialgia e febre, com evolução de 15 dias. Relatava ter nadado num rio, recentemente. As radiografias de tórax mostravam infiltração retículo-nodular bilateral. A tomografia computadorizada de alta resolução evidenciava áreas esparsas de atenuação em vidro fosco, espessamento irregular de septos in-

Abstract

A 35 years old rural worker presented with a 15 days history of progressive dyspnea, associated with dry cough, myalgia and fever. Few days before the symptoms, he had swim in a river. The chest radiographs demonstrated bilateral reticule-nodular infiltrates. The high-resolution CT showed patchy areas of ground-glass attenuation, irregular interlobular septal thickening, intralobular interstitial

¹Professor Adjunto de Radiologia da Faculdade de Medicina de São José do Rio Preto (FAMERP), São Paulo, Brasil.

²Professor Titular e Chefe do Departamento de Radiologia da Universidade Federal Fluminense (UFF). Coordenador Adjunto do Curso de Pós Graduação em Radiologia da UFRJ, Rio de Janeiro, Brasil.

³Professora Adjunta de Patologia da Faculdade de Medicina de São José do Rio Preto (FAMERP), São Paulo, Brasil.

⁴Professor Adjunto de Radiologia da Universidade Federal do Rio de Janeiro (UFRJ), Rio de Janeiro, Brasil.

⁵Professor Adjunto de Radiologia da Universidade Federal do Paraná, Curitiba, Brasil.

Departamentos de Radiologia (ASSJ) e de Patologia (PMC) da Faculdade de Medicina de São José do Rio Preto (FAMERP), São José do Rio Preto, Brasil, Departamento de Radiologia da Universidade Federal do Rio de Janeiro (UFRJ), Rio de Janeiro, Brasil (ELG, EM), e Departamento de Radiologia da Universidade Federal do Paraná, Curitiba, Brasil (DLE).

Endereços:

Departamentos de Radiologia (Director: Prof. Arthur Soares Sousa Jr.) e de Patologia (Directora: Profa. Patrícia Maluf Cury) do Hospital de Base da Faculdade de Medicina de São José do Rio Preto (FAMERP). Rua Cila, 3033. Redentora. São José do Rio Preto. São Paulo, Brasil.

Departamento de Radiologia do Hospital Universitário Clementino Fraga Filho (HUCFF), da Universidade Federal do Rio de Janeiro (UFRJ). Director: Prof. Hilton Koch. Av. Brigadeiro Trompowsky, s/n. Ilha do Fundão. Rio de Janeiro, Brasil.

Departamento de Radiologia da Universidade Federal do Paraná, Curitiba, Brasil. Director: Prof. Dante L. Escuissato. Rua General Carneiro, 181. CEP 80.000-000. Curitiba, Paraná, Brasil.

Correspondência:

Emerson L. Gasparetto, MD, PhD
R. Fernando Amaro 98 ap 61
80050-030 Curitiba PR Brazil
Email: egasparetto@gmail.com

terlobulares e do interstício intralobular e pequenos nódulos, confluentes em algumas regiões. Os exames laboratoriais eram normais. Biópsia pulmonar a céu aberto demonstrou inflamação parenquimatosa granulomatosa, com presença de ovos de esquistossoma.

thickening, and small nodules, which are confluent in some regions. All the laboratorial investigation were negative. The open lung biopsy shows parenchymal granulomatous inflammation, and numerous schistosome ova.

Rev Port Pneumol 2007; XIII (5): 741-744

Rev Port Pneumol 2007; XIII (5): 741-744

Palavras-chave: Esquistossomose aguda, tomografia computadorizada de alta resolução, infecção parasitária, pulmões.

Key-words: Acute schistosomiasis, high-resolution computed tomography, parasitic infection, lungs.

Introduction

Schistosomiasis is an important parasitic infection in many regions of the world, mainly in tropical areas, where both native populations and travellers are at risk for infection^{1,2}. There are three main species of the parasite, which causes human infections. *S. mansoni* is common in Africa, Arabia and South America, *S. haematobium* in Africa and Arabia, and *S. japonicum* in Japan and China^{3,4}. Humans acquire the infection following the contact with fresh water that harbours the intermediate snail host and the cercaria^{1,2}.

The diagnosis of schistosomiasis is based on the clinical findings, exposure to contaminate water in endemic areas, documentation of eggs in the stool, or a positive schistosoma serologic test⁵. Although the chest radiographic findings of this infection have been described, the high-resolution CT features were rarely demonstrated^{1,2,5,6,7}. In addition, the correlation between the pathological and high-resolution CT findings was not previously described in patients with acute pulmonary schistosomiasis.

The authors aim to report a case of acute pulmonary schistosomiasis, emphasizing the

high-resolution CT findings and its correlation with the pathological features.

Case report

A 35 years old rural worker presented with a 15 days history of progressive dyspnea, associated with dry cough, myalgia and fever in the last five days. He also mentioned that three days before the symptoms, he had swim in a river close to his house.

The chest radiographs demonstrated bilateral reticule-nodular infiltrates. The high-resolution CT showed patchy areas of ground-glass attenuation, irregular interlobular septal thickening, intralobular interstitial thickening, and small nodules, which are confluent in some regions (Fig. 1).

All the laboratorial investigation and the bronchoalveolar lavage were negative. The patient underwent an open lung biopsy. Histological examination demonstrated areas of parenchymal granulomatous inflammation, with clusters of epithelioid histiocytes, giant cells and some eosinophils. In addition, surrounding these areas, there was a chronic in-

SCHISTOSOMÍASE PULMONAR AGUDA: CORRELAÇÃO ENTRE A TOMOGRAFIA COMPUTADORIZADA DE ALTA RESOLUÇÃO E OS ACHADOS ANATOMOPATOLÓGICOS

Arthur Soares Souza Jr., Edson Marchiori, Patrícia Maluf Cury, Emerson L Gasparetto, Dante L Escussato

A

B

Fig. 1 (A and B) – High-resolution CT demonstrates patchy areas of ground-glass attenuation, irregular interlobular septal thickening, intralobular interstitial thickening, and small nodules, which are confluent in some regions

flammatory cell infiltrate and numerous schistosome ova (Fig. 2).

The specific treatment with tiabendazole and oxamniquine was initiated and the patient showed involution of the clinical and imaging findings in the following days. The high-resolution CT performed four months after the treatment was normal.

Discussion

Schistosomiasis is a major helminthic infection of tropical areas with estimated 200

million people infected, resulting in considerable morbidity and occasional mortality.

The human infection initiates with motile cercaria from infected water snails penetrating the skin. In the following days, maturing worms migrate to the lungs and later to the intra-hepatic veins, where they stay until full maturation. The syndrome of acute schistosomiasis is related to the early migration².

The earliest pulmonary manifestations of schistosomiasis occur at the stage of blood or lymphatic-borne schistosome migration through the lung, producing a Loeffler-like

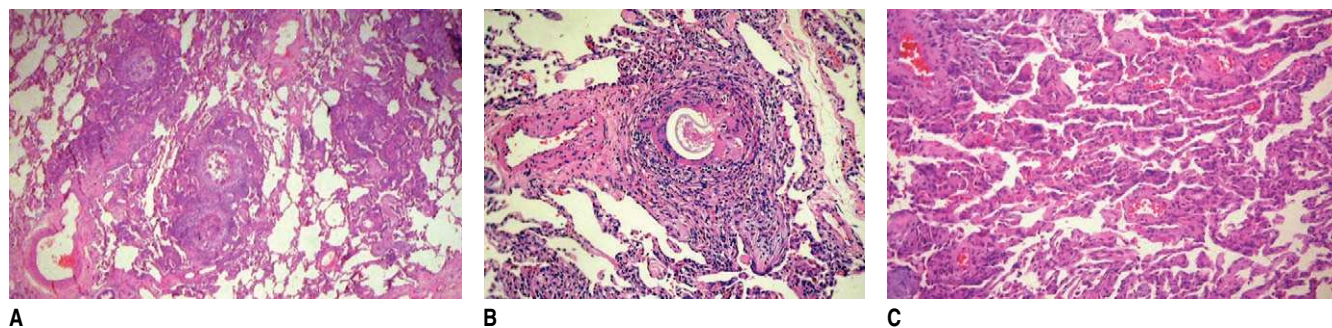


Fig. 2 – Histological sections demonstrate in **A**, multiple areas of granulomatous inflammation. In **B**, there is a schistosome ova. In **C**, there is inflammatory infiltration of the alveolar septa (haematoxylin&eosin)

syndrome, with high levels of eosinophilia^{1,8}. The radiological appearance in this phase is characterized by bilateral sub-pleural pulmonary consolidation, or scattered foci of consolidation changing in both size and position at short time intervals⁸.

The acute phase of schistosomiasis is usually asymptomatic, but clinical signs of varying intensity may occur. The most common manifestations are fever, chills, weakness, weight loss, headache, nausea, vomiting, diarrhea, hepatomegaly, splenomegaly and marked eosinophilia⁷. In this phase, the imaging studies usually demonstrate micronodular infiltrates disseminated in both lung, resembling miliary tuberculosis or viral infections^{2,6,8}. The miliary distribution of eggs, which occurs in the acute phase of the disease, explains the clinical presentation of acute schistosomiasis⁷. Multiple large nodules may also be seen, sometimes with halo sign^{1,8}. Chest radiographs and CT scan findings of acute pulmonary schistosomiasis are usually non-specific².

The late stage, or chronic schistosomiasis, appears months to years after initial infection, resulting from granuloma formation around the schistosome eggs, which are retained in the lung tissues. Chest radiographs may show interstitial infiltrates, typically nodular, and signs of fibrosis can also be seen. The pathological changes seen in the lungs are primarily resulting of granuloma formation around the schistosoma eggs. After many years, fibrosis may ensue, leading to pulmonary hypertension and cor pulmonale^{1,2,5}.

Early treatment of pulmonary schistosomiasis is important to prevent the development of severe and irreversible parenchymal damage¹. More extensive use of CT

for patients with schistosomiasis in endemic areas will probably show that pulmonary involvement in the initial phase of the disease is not rare^{6,7}.

In conclusion, schistosomiasis should be considered in the differential diagnosis of lung lesions presenting with ground-glass attenuation opacities and small nodules on the high-resolution CT, particularly in those patients with suggestive epidemiological history. In addition, the study of the histological sections of our case demonstrated that the nodules are related to the granulomas and the consolidations are secondary to confluence of the nodules. Finally, the ground-glass attenuation areas are related to the inflammatory infiltration of the pulmonary alveolar septa.

Bibliography

1. Waldman ADB, Day JH, Shaw P, Bryceson ADM. Subacute pulmonary granulomatous schistosomiasis: high resolution CT appearances – another cause of the halo sign. *Br J Radiol* 2001;74:1052-1055.
2. Salanitri J, Stanley P, Hennessy O. Acute pulmonary schistosomiasis. *Australas Radiol* 2002;46:435-437.
3. Schaberg T, Rahn W, Racz P, Lode H. Pulmonary schistosomiasis resembling acute pulmonary tuberculosis. *Eur Respir J* 1991;4:1023-1026.
4. Schwartz E. Pulmonary schistosomiasis. *Clin Chest Med* 2002;23:433-443.
5. Schwartz E, Rozenman J, Perelman M. Pulmonary manifestations of early schistosome infection among nonimmune travelers. *Am J Med* 2000;109:718-722.
6. Nguyen LQ, Estrella J, Jett EA, Grunvald EL, Nicholson L, Levin DL. Acute Schistosomiasis in Nonimmune Travelers: Chest CT Findings in 10 Patients. *AJR* 2006;186:1300-1303.
7. Lambertucci JR, Rayes AAM, Barata CH, Teixeira R, Gerspacher-Lara R. Acute schistosomiasis: report of five singular cases. *Mem Inst Oswaldo Cruz* 1997;92:631-635.
8. Vawda F, Naidoo KT, Maharajh J. "Cystic" pulmonary schistosomiasis. *Clin Radiol* 2005;60:268-270.