

we have to focus heavily on patient education, with respect to illness and treatment, and participation in clinical decisions, allowing for patients' perspectives, their medicine and inhalation device preferences, and also their disease and therapeutic related beliefs. We also need to know the physical and emotional needs of the patients, and to treat the comorbid conditions, in order to achieve a better control of COPD. For this purpose, we emphasize the key role of the patient's family or caregivers, and the importance of a multidisciplinary team in patient-centered medicine. More than the diagnosis and treatment, patient centered COPD care involves working with the patient to provide the best care possible and improvement in their quality of life.

## Conflicts of interest

The author has no conflicts of interest to declare.

## References

1. Culver B. Defining airflow limitation and chronic obstructive pulmonary disease: the role of outcome studies. *Eur Respir J*. 2015;46:8–10.
2. Global Initiative for Chronic Obstructive Lung Disease (GOLD); 2015. Available from: [www.goldcopd.org/upload/users/files/GOLD\\_Report\\_2015\\_Feb18.pdf](http://www.goldcopd.org/upload/users/files/GOLD_Report_2015_Feb18.pdf).
3. Celli BR, MacNee W, Agusti A, Anzueto A, Berg B, Buist AS, et al. Standards for the diagnosis and treatment of patients with COPD: a summary of the ATS/ERS position paper. *Eur Respir J*. 2004;23:932–46.
4. Dijk W, Tan W, Li P, Guo B, Li S, Benedetti A, et al. Clinical relevance of fixed ratio vs lower limit of normal of FEV1/FVC in COPD: patient-reported outcomes from the CanCOLD cohort. *Ann Fam Med*. 2015;13.
5. Miller M, Levy M. Chronic obstructive pulmonary disease: missed diagnosis versus misdiagnosis. *BMJ*. 2015;351:h3021.
6. Criner GJ, Bourbeau J, Diekemper RL, Ouellette DR, Goodridge D, Hernandez P, et al. Prevention of acute exacerbation of COPD. American College of Chest Physicians and Canadian Thoracic Society Guideline. *Chest*. 2015;147:894–942.
7. Jeanne Lenzer. Why we can't trust clinical guidelines. *BMJ*. 2013;346:f3830.
8. Wiśniewski D, Porzezińska M, Gruchała-Niedoszytko M, Niedoszytko M, Słomiński JM, Jassem E. Factors influencing adherence to treatment in COPD patients and its relationship with disease exacerbations. *Pneumonol Alergol Pol*. 2014;82:96–104. Available from: [www.pneumonologia.viamedica.pl](http://www.pneumonologia.viamedica.pl)
9. Braido F, Baiardini I, Sumbersi M, Blasi F, Canonica GW. Obstructive lung diseases and inhaler treatment. *Respir Res*. 2013;14.
10. Rand CS. Patient adherence with COPD therapy. *Eur Respir Rev*. 2005;14:97–101.
11. Bryant J, McDonald V, Boyes A, Sanson-Fisher R, Paul C, Melville J. Improving medication adherence in chronic obstructive pulmonary disease. *Respir Res*. 2013;14.
12. Restrepo RD, Alvarez MT, Wittnebel LD, Sorenson H, Wettstein R, Vines DL, et al. Medication adherence issues in patients treated for COPD. *Int J COPD*. 2008;3:371–84.
13. Vincken W, Dekhuijzen R, Barnes P. The ADMIT series – issues in inhalation therapy. *Prim Care J*. 2010;19:10–20.

A. Araújo

*Respiratory Department, CHAA, Guimarães, Portugal*  
*E-mail address: duartearaujodr@sapo.pt*

<http://dx.doi.org/10.1016/j.rppnen.2015.08.008>

## Spontaneous pneumomediastinum in pregnancy: A case report



Dear Editor-in-Chief,

Postpartum spontaneous pneumomediastinum (Hamman's Syndrome) is a well-known but rare complication of pregnancy which is potentially lethal. However, current international pneumothorax guidelines do not give any advice on the management of this life-threatening event.<sup>1–4</sup>

We report the case of a 30-year-old woman who came to our attention at the 40th week of her pregnancy. She was a non-smoker and had no history of pulmonary diseases.

During the later part of labor, she suddenly developed facial edema, subcutaneous thoracic emphysema and dyspnea.

Arterial blood gas analysis revealed severe hypoxemia and hypocapnia.

Blood pressure and cardiac rate were normal and sensorium was intact (Kelly score = 1).

Chest CT scan showed a large pneumomediastinum with bilateral pneumothorax (Fig. 1).

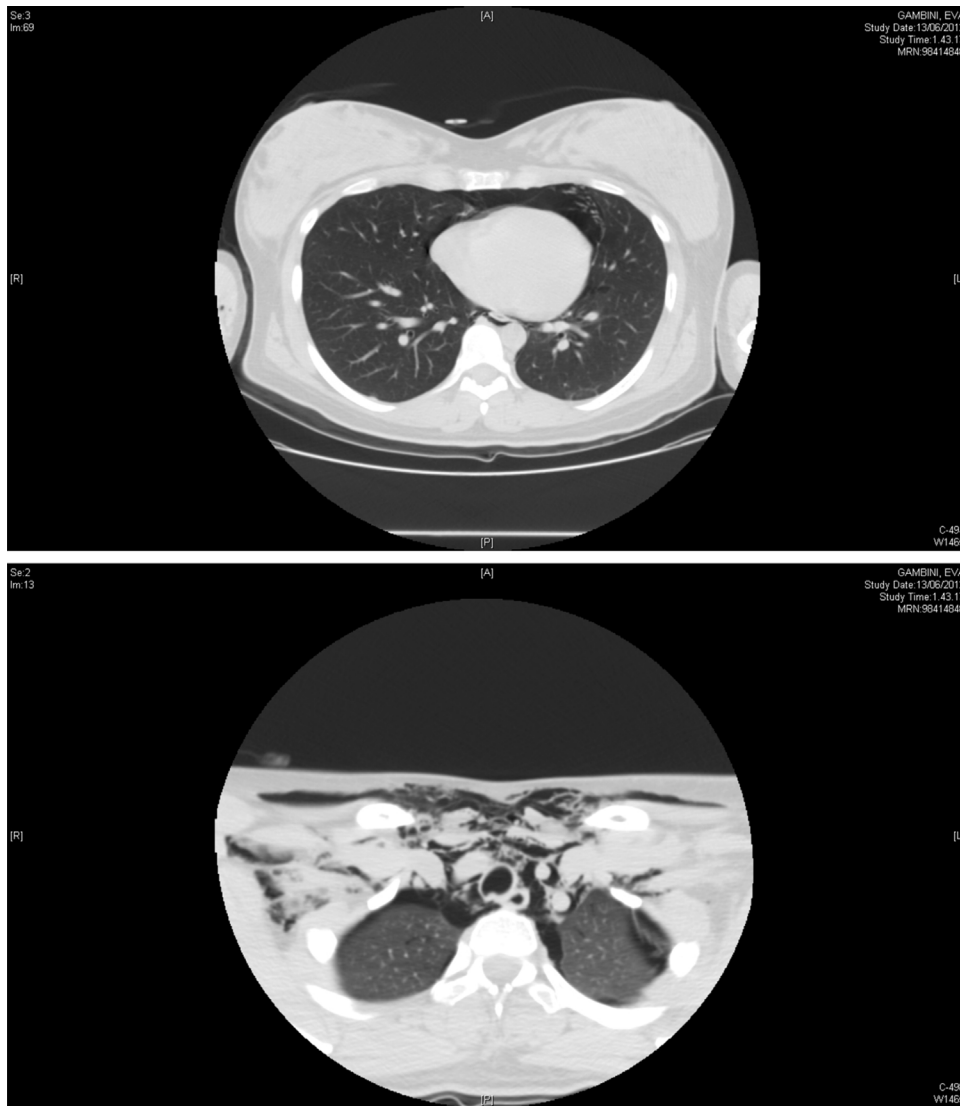The patient was submitted to cardio-respiratory monitoring and treated with oxygen and conservative therapy.

Within five days of hospitalization, the patient's condition improved with complete resolution of the subcutaneous emphysema and a partial reabsorption of both pneumomediastinum and pneumothorax.

After a follow-up of two weeks, chest X-ray turned out to be normal.

Patho-physiologically, the development of pneumomediastinum during spontaneous delivery is linked to the sudden laceration of the alveola due to the increase of intrathoracic and intra-abdominal pressure caused by repeated Valsalva maneuvers (Fig. 2).

The main physiological alterations of the respiratory system that occurred during the last part of pregnancy are mainly the consequence of the progestin stimulation of the respiratory drive and consist of a reduction in the functional



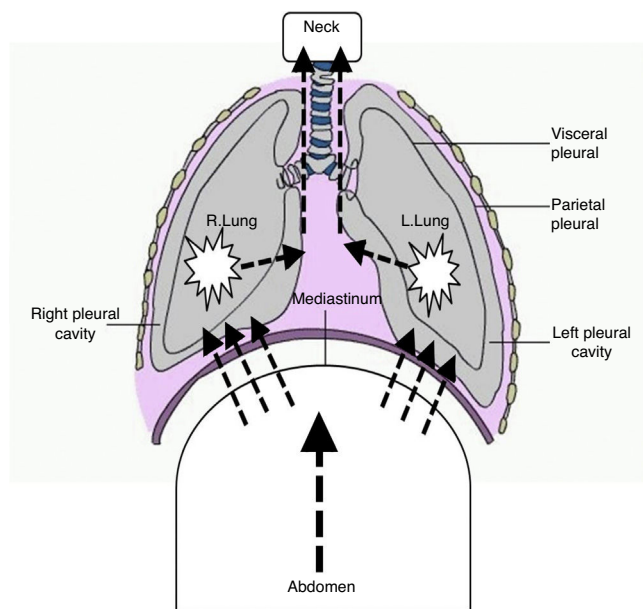
**Figure 1** Chest CT showing a large pneumomediastinum associated with a minimum layer of bilateral pneumothorax, more visible on the left (maximum thickness 17 mm) associated with huge subcutaneous emphysema in the supraclavicular region, in the neck and in the laterocervical bands bilaterally.

residual capacity and an increase of about 70% in alveolar ventilation due to a breathing pattern with augmented respiratory rate and tidal volume.

During the second stage of labor, hyperventilation and increase of intra-abdominal pressure caused by repeated Valsalva maneuvers are risk factors for the development of pneumothorax and pneumomediastinum, especially in patients with pre-existent subpleural blebs.<sup>5,6</sup>

In this case report, the pneumomediastinum was likely to be due to this baro-traumatic mechanism.

The current guidelines for the management of pneumothorax and pneumomediastinum do not indicate a specific treatment for Hamman's syndrome. The recommendation of the experts is to encourage better coordination between thoracic surgeons, gynecologists and lung specialists so that this condition can be managed better.<sup>1,7,8</sup> Lung specialists should be able to recognize this rare complication of pregnancy in order to coordinate a useful collaboration with other specialists during patient observation and treatment.



**Figure 2** Pathophysiologic mechanisms of post partum pneumomediastinum.

### Conflicts of interest

The authors have no conflicts of interest to declare.

### References

1. Henry M, Arnold T, Harvey J. BTS guidelines for the management of spontaneous pneumothorax. *Thorax*. 2003;58 Suppl.:39–52.
2. Karson EM, Saltzman D, Davis MR. Pneumomediastinum in pregnancy: two case reports and a review of the literature, pathophysiology and management. *Obstet Gynecol*. 1984;64 September (3 Suppl.):395–435.
3. Zapardiel I, Delafuente-Valero J, Diaz-Miguel V, Godoy-Tundidor V, Bajo-Arenas JM. Pneumomediastinum during the fourth stage of labor. *Gynecol Obstet Investig*. 2009;67:70–2.
4. Heffener JE, Sahn SA. Pleural disease in pregnancy. *Pulmonary disease in pregnancy*. *Clin Chest Med*. 1992;13:667–78.
5. Annaiah TK, Reynolds SF. Spontaneous pneumothorax – a rare complication of pregnancy. *J Obstet Gynaecol*. 2011;31:80–2.
6. Jamadar DA, Kazerooni EA, Hirschl RB. Pneumomediastinum: elucidation of the anatomic pathway by liquid ventilation. *J Comput Assist Tomogr*. 1996;20:309.
7. Caldwell EJ, Powell RD Jr, Mullooly JP. Interstitial emphysema: a study of physiologic factors involved in experimental induction of the lesion. *Am Rev Respir Dis*. 1970;102:516.
8. Lal A, Anderson G, Cowen M, Lindow S, Arnold AG. Pneumothorax and pregnancy. *Chest*. 2007;132:1044–8.

R. Scala\*, C. Madioni, C. Manta, C. Maggiorelli, U. Maccari, G. Ciarleglio

*Pulmonology and Respiratory Intensive Care Unit, San Donato Hospital, Arezzo, Italy*

\*Corresponding author.

*E-mail address:* [raffaele\\_scala@hotmail.com](mailto:raffaele_scala@hotmail.com) (R. Scala).

<http://dx.doi.org/10.1016/j.rppnen.2015.09.004>