



CASE REPORT

Malignant transformation of a tracheal chondroma: The second reported case and review of the literature



D. Maia^{a,1}, X. Elharrar^a, S. Laroumagne^a, F. Maldonado^b, P. Astoul^{a,c}, H. Dutau^{a,*}

^a *Service de Oncologie Thoracique – Maladies de La Plèvre - Pneumologie Interventionnelle, Hôpital Nord, Marseille, France*

^b *Department of Medicine, Vanderbilt University, Nashville, USA*

^c *Aix-Marseille University, Marseille, France*

Received 27 November 2015; accepted 15 April 2016

Available online 14 May 2016

KEYWORDS

Trachea;
Chondroma;
Chondrosarcoma

Abstract Tracheal tumors are rare, representing only 0.2% of the respiratory tract malignancies. Chondrosarcoma arising in the trachea was first described in 1959 by Jackson et al. and since then only 20 cases have been described. We report the second documented case of malignant transformation from an endotracheal chondroma, in a 75-year-old woman, and review the literature.

© 2016 Sociedade Portuguesa de Pneumologia. Published by Elsevier España, S.L.U. This is an open access article under the CC BY-NC-ND license (<http://creativecommons.org/licenses/by-nc-nd/4.0/>).

Introduction

Primary tracheal tumors are rare, 80% are malignant and account for 0.2% of all respiratory malignancies. The most common histologic types are squamous cell carcinoma and adenoid cystic carcinoma, followed by carcinoid tumor, adenocarcinoma, and small cell carcinoma. The remaining tumors are diverse and include chondroma, chondrosarcoma, fibrosarcoma, among others.^{1,2} Jackson et al. described the first case of tracheal chondrosarcoma in 1959 and since then only 20 cases have been reported

(Table 1).^{3–23} We add a new case leading to a review of the literature.

Case report

A 75-year-old woman with a past medical history significant for hypertension, diabetes mellitus and carotid artery disease reported having a chronic non-productive cough and dysphagia for about one year. Six years prior to this presentation, she had undergone endoscopic resection of a tracheal chondroma diagnosed during investigations for multiple episodes of respiratory distress mimicking asthma. No further treatment was done at that time. At presentation, a chest-computed tomography (CT) revealed a mass (25 mm × 30 mm × 25 mm) located in the left postero-lateral wall of the mid-trachea without lymphadenopathy

* Corresponding author.

E-mail address: hdutau@ap-hm.fr (H. Dutau).

¹ Permanent address: Serviço de Pneumologia, Hospital de Santa Marta, CHLC, Lisboa, Portugal.

Table 1 Characteristics of patients with tracheal chondrosarcoma.

N°	Age, Sex	Symptoms, duration (months)	Tracheal segment involved	Size (cm)	Treatment	Recurrence	Follow-up (years)	Authors, year
1	32, M	C, 72	Inf	NR	ER	No	6	Jackson <i>et al</i> 1959 ³
2	73, M	D, O, W, 8	Inf	2.5	ER	local	2	Daniels <i>et al</i> 1967 ⁴
3	48, F	C, W, 15	Sup	4	STR	no	5	Fallahnejad <i>et al</i> 1973 ⁵
4	71, M	H, C, D 4	Med	3	STR	no	5	Weber <i>et al</i> 1978 ⁶
5	58, M	D, 24	Inf	2	STR	no	2.5	Slasky <i>et al</i> 1985 ^{7 a}
6	74, M	P, acute	Sup	2	STR	no	1	Arévalo <i>et al</i> 1986 ⁸
7	72, M	H, D, 7	Med	5	ELD and STR	no	0.5	Matsuo <i>et al</i> 1988 ⁹
8	54, M	W, D, 1	Inf	2	STR	local, distant	14	Salminen <i>et al</i> 1990 ^{10 b}
9	64, M	D, 36	Inf	2.3	STR	no	1	Kaneda <i>et al</i> 1993 ¹¹
10	72, M	D, 36	Inf	6.5	STR	no	NR	Leach <i>et al</i> 1994 ¹²
11	54, M	W, D, 1	Inf	2	ELD and STR	no	3.5	Kiriyama <i>et al</i> 1997 ¹³
12	84, M	C, D, St, 24	Med	NR	STR	no	3	Hervás <i>et al</i> 1997 ¹⁴
13	87, M	D, 12	Med	3	ELD and RT	local	1	Farrell <i>et al</i> 1998 ¹⁵
14	49, M	St, D, acute	Sup	NR	ELD and STR	no	4	Aznar <i>et al</i> 2001 ^{16 a}
15	78, M	D, 3	Inf	NR	ELD and STR	no	0.5	Maish <i>et al</i> 2003 ¹⁷
16	34, M	H, D, 8	Sup	2.5	STR	no	6.3	Umezu <i>et al</i> 2008 ¹⁸
17	72, M	O, D, W, 12	Sup	NR	ELD and RT	no	7	Mendonça 2009 ¹⁹
18	34, M	C, W, D, 18	Sup	2	ER and TSR	no	NR	Wagnetz <i>et al</i> 2009 ^{20 a}
19	35, M	W, D	Sup	NR	ER and TSR	no	NR	Almeida <i>et al</i> 2010 ^{21 a}
20	63, M	W, D, 6	Med	NR	ER and TSR	no	NR	Mirza <i>et al</i> 2010 ²²
21	74, M	W, D	Sup	NR	TSR	no	NR	Mohajeri <i>et al</i> 2013 ²³

C, cough; W, wheezing; St, stridor; D, dyspnea; O, orthopnea; H, hemoptysis; P, pneumonia; Inf, inferior; Med, medium; Sup, superior; STR, surgical tracheal resection; ER, endoscopic resection; ELD, endoscopic laser debulking; RT, external beam radiotherapy; NR, not reported.

^a Grade II chondrosarcoma.

^b Malignant transformation and cause of death.

(Fig. 1). Her physical examination and pulmonary functions tests were normal. Gastroesophagoscopy revealed extrinsic compression at 18 cm from the dental arch, with normal mucosa. Rigid bronchoscopy confirmed the lesion described in CT, which protruded into the tracheal lumen, occupying less than half of its diameter and covered with regular mucosa. After rigid scissors incision, mechanical debridement and laser application restored normal lumen patency

(Fig. 2). Histopathological analysis showed cartilaginous tumoral proliferation with increased cellularity and occasional binucleate chondrocytes as well as necrotic remains, in favor of low-grade chondrosarcoma (Fig. 3). The diagnosis was confirmed by the regional referral center for sarcoma. The case was discussed in our multidisciplinary tumor board and the patient deemed unfit for surgery. At present, 9 months after the second endoscopic intervention, the

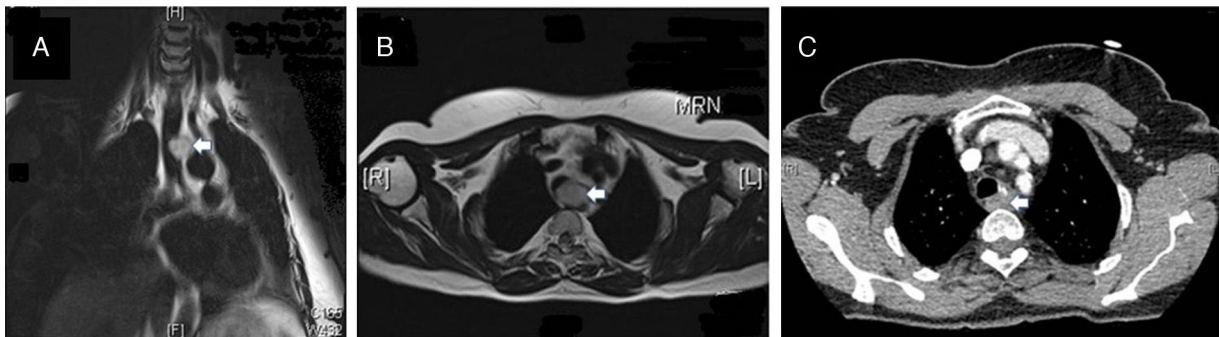


Figure 1 Magnetic resonance imaging showing the tracheal tumor (arrow) in sagittal (A) and coronal (B) planes compressing the esophagus but without invasion. (C) Follow-up chest CT 8 months after interventional endoscopy, demonstrating residual tumor (arrow).

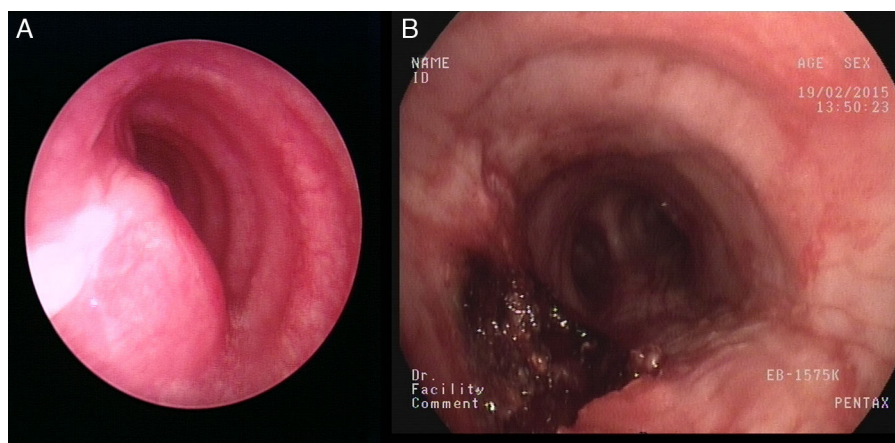


Figure 2 Endoscopic aspect before (A) and after (B) mechanical debulking and laser application.

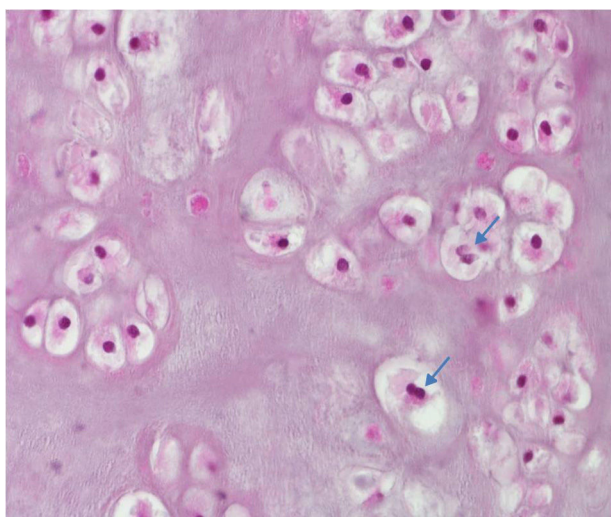


Figure 3 Microscopical aspect with cartilaginous tumor proliferation presenting variable size lobules and occasional binucleate cells (arrows), consistent with low-grade chondrosarcoma (hematoxylin and eosin stain; $\times 200$).

patient is asymptomatic with stable residual tumor (Fig. 1, panel C).

Discussion

Chondrosarcoma refers to a group of tumors that consist predominantly of cartilage and can be classified into 3 histologic grades (I, II and III), based on cellularity, atypia, and pleomorphism. The higher the grade, the more likely the tumor is to spread and metastasize.²⁴ Low-grade chondrosarcoma resembles benign cartilaginous tumors, and it is difficult to differentiate the two lesions on the basis of histologic features alone. Extraskelatal chondrosarcoma is uncommon and its location in the airway is more frequent in the larynx.²⁵ Of all tracheal chondrosarcomas (TCS) reported, the tumor was grade II in 4 cases and grade III in one. TCS tend to be slow-growing and in general do not metastasize, in contrast to chondrosarcomas found elsewhere in the body.

Its etiology is still unknown and there is no tracheal segment predilection. Patients' ages have ranged from 32 to 87 years and only one female patient was previously reported.³⁻²³ Most frequent presenting symptoms are chronic cough and dyspnea, often with associated wheezing potentially masquerading as adult onset asthma or COPD.^{17,20,23} Unlike previous reported cases, dysphagia was observed in our case, related to an extraluminal growth when the tumor recurred, in contrast to the preponderance of intraluminal obstruction in the initial presentation of most reported cases.

Investigations usually start with a chest X-ray which may show narrowing of the tracheal shadow or mediastinal mass. However, in most cases the chest X-ray is normal. CT imaging allows an accurate location of the lesion and provides information about tumor extension. Calcification is present in 75% of cartilaginous tumors.²⁰ Magnetic resonance imaging may provide a better assessment of the tumor relationship with surrounding structures but its value remains controversial.²⁶

Bronchoscopy is the best method for the diagnosis and offers the opportunity of initial management and allows for surgical planning if indicated. The optimal treatment seems to consist of tracheal sleeve-resection with end-to-end anastomosis. Incomplete resections are at risk of local recurrence with an increased risk of metastatic disease.¹⁰

The first 2 reported cases were treated with endoscopic resection alone, whereas surgery followed initial endoscopic laser debulking (ELD) in 7 cases. The majority of cases ($n=10$) were treated with solely surgical resection. Chemotherapy seems to be inefficient in low-grade chondrosarcoma, but there is no much literature on the subject.²⁷ Historically, chondrosarcoma has been considered as radioresistant but several studies have challenged this notion and radiation may be indicated as an adjuvant therapy after incomplete resection, in tumors considered unresectable, in surgically unfit patients or where there is metastatic disease.²⁵ Two TCS cases have been treated with ELD followed by conventional radiotherapy (RT), both after incomplete endoscopic resection. In the first case, an 87-year-old patient refused surgery and follow-up was limited to one year but there was no obvious progression of the remaining lesion. In the other case, the patient was not

deemed a suitable candidate for surgery, and there was no evidence of disease after 7 years of follow-up.

The prognosis of TCS appears excellent if adequate resection is achieved. Local recurrence has been described in 3 cases and may be managed endoscopically or surgically.^{4,10,15} Salminen et al. reported the only case in which the patient died after malignant transformation of a chondroma, 14 years after the initial diagnosis with metastatic disease. We report, to the best of our knowledge, the second case of tracheal chondroma presenting with malignant transformation during its course.

In conclusion, tracheal chondrosarcoma is a relatively slow-growing lesion that should be treated surgically with tracheal resection. Bronchoscopy is the gold-standard for diagnosis and rigid bronchoscopy with ELD can be the first therapeutic option but can also be definitive when surgery is not an option. Despite the small numbers of cases on which to base opinion, it appears to have an indolent behavior, even when it recurs.

Conflict of interest

The authors have no conflicts of interest to declare.

Ethical responsibilities

Protection of human and animal subjects. The authors declare that no experiments were performed on humans or animals for this study.

Confidentiality of data. The authors declare that no patient data appear in this article

Right to privacy and informed consent. The authors declare that no patient data appear in this article.

References

- Gaissert HA, Mark EJ. Tracheobronchial gland tumors. *Cancer Control*. 2006;13:286–94.
- Urdaneta AI, Yu JB, Wilson LD. Population based cancer registry analysis of primary tracheal carcinoma. *Am J Clin Oncol*. 2011;34:32–7.
- Jackson C, Jackson CL. *Disease of the nose, throat and ear*. Philadelphia: W.B. Saunders Company; 1959.
- Daniels AC, Conner GH, Straus FH. Primary chondrosarcoma of the tracheobronchial tree. Report of a unique case and brief review. *Arch Pathol*. 1967;84:615–24.
- Fallahnejad M, Harrell D, Tucker J, Forest J, Blakemore WS. Chondrosarcoma of the trachea. Report of a case and five-year follow-up. *J Thorac Cardiovasc Surg*. 1973;65:210–3.
- Weber AL, Shortsleeve M, Goodman M, Montgomery W, Grillo HC. Cartilaginous tumors of the larynx and trachea. *Radiol Clin N Am*. 1978;16:261–7.
- Slasky BS, Hardesty RL, Wilson S. Tracheal chondrosarcoma with an overview of other tumors of the trachea. *J Comput Tomogr*. 1985;9:225–31.
- Arévalo M, Ordi J, Renedo G, Rami R, Oliva H. Chondrosarcoma of the trachea. Report of a case. *Respiration*. 1986;49:147–51.
- Matsuo T, Kinoshita S, Iwasaki K, Shibata M, Ushio T, Kawata S, et al. Chondrosarcoma of the trachea. A case report and literature review. *Acta Cytol*. 1988;32:908–12.
- Salminen US, Halttunen P, Taskinen E, Mattila S. Recurrence and malignant transformation of endotracheal chondroma. *Ann Thorac Surg*. 1990;49:830–2.
- Kaneda Y, Nawata S, Sugi K, Hirayama T, Esato K. Chondrosarcoma of the trachea – report of a case. *Nihon Kyobu Geka Gakkai Zasshi*. 1993;41:1535–40.
- Leach KR, Martinez FJ, Morelock JW, Korobkin MT, Orringer MB. Dyspnea and tracheal mass in an elderly man. *Chest*. 1994;105:1555–6.
- Kiriyama M, Masaoka A, Yamakawa Y, Niwa H, Fukai I, Yamada T. Chondrosarcoma originating from the trachea. *Ann Thorac Surg*. 1997;63:1772–3.
- Tarrazona Hervás V, Galán Gil G, Monteagudo Castro C. Chondrosarcoma of the trachea. Apropos a case. *Arch Bronconeumol*. 1997;33:481–2.
- Farrell ML, Gluckman JL, Biddinger P. Tracheal chondrosarcoma: a case report. *Head Neck*. 1998;20:568–72.
- Aznar E, Nogués J, Moya J, Ramírez RD, García B, Maños M, et al. Crico-tracheal chondrosarcoma. *Acta Otorrinolaringol Esp*. 2001;52:603–6.
- Maish M, Vaporciyan AA. Chondrosarcoma arising in the trachea: a case report and review of the literature. *J Thorac Cardiovasc Surg*. 2003;126:2077–80.
- Umezu H, Tamura M, Kobayashi S, Sawabata N, Honma K, Miyoshi S. Tracheal chondrosarcoma. *Gen Thorac Cardiovasc Surg*. 2008;56:199–202, <http://dx.doi.org/10.1007/s11748-007-0218-3>.
- Mendonça V, Jorge M, Monteiro-Grillo I, Palhano MJ, Feijó S. Tracheal chondrosarcoma. *Clin Transl Oncol*. 2010;12:576–80, <http://dx.doi.org/10.1007/s12094-010-0557-x>.
- Wagnetz U, Patsios D, Darling G, Las Heras F, Hwang D. Tracheal chondrosarcoma – a rare complication in Maffucci syndrome. *Br J Radiol*. 2009;82:e178–81, <http://dx.doi.org/10.1259/bjr/17386896>.
- de Almeida JR, Pagedar NA, Keshavjee S, Gilbert R. Chondrosarcoma of the trachea in a patient with Maffucci syndrome. *J Otolaryngol Head Neck Surg*. 2010;39:E12–5.
- Mirza F, Paul S, Stiles BM, Piotti KC, Kawaguchi KR, Altorki NK. Adult onset asthma. *Ann Thorac Surg*. 2010;90:e31, <http://dx.doi.org/10.1016/j.athoracsur.2010.05.040>.
- Mohajeri G, Hekmatnia A, Ahrar H, Hekmatnia F, Nia RB, Afsharmoghdam N, et al. A rare case of laryngo-tracheal chondrosarcoma in a patient with past history of radioiodine therapy for thyroid cancer. *Adv Biomed Res*. 2013;2:74, <http://dx.doi.org/10.4103/2277-9175.115802>, eCollection 2013.
- Evans HL, Ayala AG, Romsdahl MM. Prognostic factors in chondrosarcoma of bone: a clinicopathologic analysis with emphasis on histologic grading. *Cancer*. 1977;40:818–31.
- Gripp S, Pape H, Schmitt G. Chondrosarcoma of the larynx: the role of radiotherapy revisited – a case report and review of the literature. *Cancer*. 1998;82:108–15.
- Douis H, Jeys L, Grimer R, Vayyapuri S, Davies AM. Is there a role for diffusion-weighted MRI (DWI) in the diagnosis of central cartilage tumors? *Skelet Radiol*. 2015;44:963–9.
- Drilon AD, Popat S, Bhuchar G, D'Adamo DR, Keohan ML, Fisher C, et al. Extraskelletal myxoid chondrosarcoma: a retrospective review from 2 referral centers emphasizing long-term outcomes with surgery and chemotherapy. *Cancer*. 2008;113:3364–71, <http://dx.doi.org/10.1002/cncr.23978>.