



ORIGINAL ARTICLE

# Endobronchial ultrasound-guided transbronchial needle aspiration for nodal staging in non-small cell lung carcinoma



D. Coutinho<sup>a,\*</sup>, A. Oliveira<sup>a</sup>, S. Campinha<sup>a</sup>, S. Neves<sup>a</sup>, M. Guerra<sup>b</sup>, J. Miranda<sup>b</sup>,  
A. Furtado<sup>c</sup>, D. Tente<sup>c</sup>, A. Sanches<sup>c</sup>, J. Almeida<sup>a</sup>, J. Moura e Sá<sup>a</sup>

<sup>a</sup> Respiratory Endoscopy Unit, Pulmonology Department, Centro Hospitalar de Vila Nova de Gaia e Espinho, Vila Nova de Gaia, Portugal

<sup>b</sup> Cardiothoracic Surgery Department, Centro Hospitalar de Vila Nova de Gaia e Espinho, Vila Nova de Gaia, Portugal

<sup>c</sup> Pathology Department, Centro Hospitalar de Vila Nova de Gaia/Espinho, Portugal

Received 4 July 2016; accepted 24 December 2016

Available online 9 February 2017

## KEYWORDS

EBUS-TBNA;  
Non-small cell lung  
carcinoma;  
Nodal staging

## Abstract

**Introduction:** Lung cancer staging has recently evolved to include endobronchial ultrasound-guided transbronchial needle aspiration (EBUS-TBNA) for nodal assessment.

**Aim:** Evaluate the performance and safety of EBUS-TBNA as a key component of a staging algorithm for non-small cell lung carcinoma (NSCLC) and as a single investigation technique for diagnosis and staging of NSCLC.

**Methods:** Patients undergoing EBUS-TBNA for NSCLC staging at our institution between April 1, 2010 and December 31, 2014 were consecutively included with prospective data collection. EBUS-TBNA was performed under general anesthesia through a rigid scope.

**Results:** A total of 122 patients, 84.4% males, mean age 64.2 years. Histological type: 78 (63.9%) adenocarcinoma, 33 (27.0%) squamous cell carcinoma, 11 (8.9%) undifferentiated/other NSCLC. A total of 435 lymph node stations were punctured. Median number of nodes per patient was 4. EBUS-TBNA nodal staging: 63 (51.6%) N0; 8 (6.5%) N1; 34 (27.9%) N2, and 17 (13.9%) N3. EBUS-TBNA was the primary diagnostic procedure in 27 (22.1%) patients. EBUS-TBNA NSCLC staging had a sensitivity, specificity, positive predictive value, negative predictive value, and diagnostic accuracy rate of 83.3, 100, 100, 86.1, and 91.8%, respectively. No complications were attributable to the procedure.

**Conclusion:** A comprehensive lung cancer staging strategy that includes EBUS-TBNA seems to be safe and effective. Our EBUS-TBNA performance and safety in this particular setting was in line

\* Corresponding author.

E-mail address: [dpcoutinho@gmail.com](mailto:dpcoutinho@gmail.com) (D. Coutinho).

with previously published reports. Additionally, our study showed that, in selected patients, lung cancer diagnosis and staging are achievable with a single endoscopic technique.

© 2017 Sociedade Portuguesa de Pneumologia. Published by Elsevier España, S.L.U. This is an open access article under the CC BY-NC-ND license (<http://creativecommons.org/licenses/by-nc-nd/4.0/>).

## Introduction

In spite of all advances in surgical treatment and multi-modality treatment, lung cancer is still the most common cause of cancer death across the world.<sup>1</sup> In Portugal, lung cancer is the fourth most common malignancy, with a crude incidence of 30.6 per 100,000 inhabitants, and the second highest cause of malignancy disease death.<sup>2</sup> Accurate staging is important in patients with non-small cell lung cancer (NSCLC) who are fit for surgery and have no evidence of extrathoracic disease, because mediastinal lymph nodes disease status is an indicator for treatment with curative intent.<sup>3</sup>

Several invasive and non-invasive techniques are available to support lung cancer staging. Imaging methods, such as computed tomography (CT) and positron emission tomography (PET), indicate size and metabolic activity of mediastinal nodes, respectively, but the lack of specificity is an important pitfall.<sup>4</sup> Therefore, tissue confirmation of suspected malignant lymphadenopathy is required, especially before surgical resection. Surgical staging by mediastinoscopy presents a high sensitivity and specificity and was for many years the gold standard modality for this purpose.<sup>5,6</sup> However, it is a surgical procedure that requires general anesthesia and clinical admission.

Endobronchial ultrasound-guided transbronchial needle aspiration (EBUS-TBNA) is a newer technique that allows minimally invasive sampling of intrathoracic lymph nodes adjacent to the bronchial tree and it is gradually replacing mediastinoscopy as NSCLC staging gold standard.<sup>5</sup> In recent guidelines,<sup>3</sup> lung cancer staging has evolved to include EBUS-TBNA for nodal assessment.

The aim of our work was to evaluate our EBUS-TBNA performance and safety as a key component of a staging algorithm for NSCLC and as a single investigation technique for diagnosis and staging of NSCLC.

## Methods

### Patients

From April 1, 2010 and December 31, 2014, all consecutive patients referred for EBUS-TBNA with the purpose of NSCLC staging at our institution were prospectively included in our study. Chest CT was mandatory before the procedure (PET or PET-CT was dependent upon referring physician decision). Primary exclusion criteria were, significant concurrent malignant disease or any condition or concurrent medicine that contraindicated EBUS-TBNA. Secondary exclusion criteria were added to ensure maximum homogeneity on our EBUS staging performance evaluation:

patients that received induction chemotherapy, that were lost to follow up, or that had a surgery related complication that precluded a correct mediastinal surgical staging were excluded from this latter analysis.

The 7th edition of the TNM staging system in lung cancer was used throughout.

### Procedures

EBUS-TBNA was performed under general anesthesia with flexible ultrasound bronchoscope (BF-UC180F, Olympus, Tokyo, Japan) through a rigid scope in an outpatient setting. A systematic examination of all mediastinal and hilar lymph node stations was conducted. N3 nodes were first punctured, followed by N2 and lastly ipsilateral hilar N1 nodes, if appropriate. Transbronchial aspiration was performed through a dedicated 22-gauge or 21-gauge needle (NA-2015X-4021/2, Olympus, Tokyo, Japan) and with application of negative pressure. At least two needle passes per station were carried out. Additional punctures were performed when rapid on-site evaluation (ROSE) or the macroscopic appearance of the acquired material was not satisfactory. The aspirated material was smeared onto glass slides. Smears were fixed in alcohol and immediately stained with hematoxylin/eosin staining protocol for ROSE by a cytopathologist. Specimens were categorized as positive (tumor cells), negative (lymphoid but no tumor cells), or inconclusive (poor cellularity).

### Statistical methods

A descriptive analysis was carried out in which categorical variables were expressed as absolute and relative frequencies and continuous variables as means and standard deviation.

For statistical purposes in our EBUS staging performance evaluation, it was assumed that a positive EBUS-TBNA for N2/N3 disease (with or without surgical-pathologic confirmation) was a true positive. A N0/N1 staging obtained by EBUS-TBNA and confirmed by subsequent methods (invasive or 6 month clinical and radiological follow-up) was considered a true negative. A negative EBUS-TBNA result that was later confirmed to be positive for malignancy by other invasive methods in the same anatomical location or by disease progression on clinical follow up was a false-negative. The sensitivity, specificity, positive predictive value, negative predictive value, and diagnostic accuracy rate were calculated using the standard definitions.

**Table 1** Patient characteristics, lymph node size, categorization and stations assessed, final diagnosis, and N staging.

Characteristics	
Patients <i>n</i>	122
Gender (male/female) <i>n</i> (%)	103 (84.4)/19 (15.6)
Age mean (SD)	64.2 ( $\pm 10.8$ )
PET scan <i>n</i> (%)	92 (75.4)
Lymph node size mean (SD)	13.6 mm ( $\pm 9.9$ )
Lymph node categorization	
Positive <i>n</i> (%)	93 (21.4)
Negative <i>n</i> (%)	332 (76.3)
Inconclusive <i>n</i> (%)	10 (2.3)
Lymph node stations assessed	
2R <i>n</i> (% per patients)	3 (2.5)
2L <i>n</i> (% per patients)	1 (0.8)
4R <i>n</i> (% per patients)	93 (76.2)
4L <i>n</i> (% per patients)	83 (68.0)
7 <i>n</i> (% per patients)	103 (84.4)
10R <i>n</i> (% per patients)	15 (12.3)
10L <i>n</i> (% per patients)	7 (5.7)
11R <i>n</i> (% per patients)	73 (59.8)
11L <i>n</i> (% per patients)	55 (45.1)
12R <i>n</i> (% per patients)	3 (2.5)
Final diagnosis	
Adenocarcinoma <i>n</i> (%)	78 (63.9)
Squamous cell carcinoma <i>n</i> (%)	33 (27.0)
Undifferentiated NSCLC <i>n</i> (%)	7 (5.7)
Other NSCLC <i>n</i> (%)	4 (3.3)
EBUS-TBNA N-staging	
N0 <i>n</i> (%)	63 (51.6)
N1 <i>n</i> (%)	8 (6.6)
N2 <i>n</i> (%)	34 (27.9)
N3 <i>n</i> (%)	17 (13.9)

## Results

Out of a total of 437 patients submitted to EBUS at our institution, 122 patients were included in our study (mean age  $64.2 \pm 10.8$  years; 84.4% males). Patient characteristics, lymph node size, categorization and stations assessed, final diagnosis, and N staging are presented in Table 1. A total of 435 nodes were punctured (ultrasonographic mean size  $13.6 \pm 9.9$  mm, range 4–86 mm), with a median of two needle passes for each site and four nodes per patient. The three most assessed node stations were station 7 ( $n=103$ ; 23.7% of patients), station 4R ( $n=93$ ; 21.3% of patients), and station 4L ( $n=83$ ; 19.0% of patients). PET scan was available in 75.4% of patients and ROSE in 97% of the procedures. Patients were staged by EBUS-TBNA as follows: 63 (51.6%) N0; 8 (6.6%) N1; 34 (27.9%) N2, and 17 (13.9%) N3. Final diagnosis was divided by histological type in 78 (63.9%) adenocarcinoma, 33 (27.0%) squamous cell carcinoma, 7 (5.7%) undifferentiated NSCLC, 4 (3.3%) other NSCLC. EBUS-TBNA procedure was uneventful and there were no complications in any of the patients.

Between all patients submitted to EBUS-TBNA with the purpose of primary diagnosis and staging in a single procedure ( $n=39$ ; 32.0%), primary diagnosis was achieved in 69.2% ( $n=27$ ) of them. Final diagnosis of these 27 patients was

**Table 2** Comparison of EBUS-TBNA results with the final diagnoses for prediction of lymph node stage.

EBUS-TBNA results	Final diagnosis		
	N2/N3 disease	N0/N1 disease	Total
N2/N3 disease	30	0	30
N0/N1 disease	6	37	43
Total	36	37	73

The sensitivity, specificity, positive predictive value, negative predictive value, and diagnostic accuracy rate was 83.3, 100, 100, 86.1, and 91.8%, respectively.

divided by histological type in 23 (85.2%) adenocarcinoma and 4 (14.8%) squamous cell carcinoma.

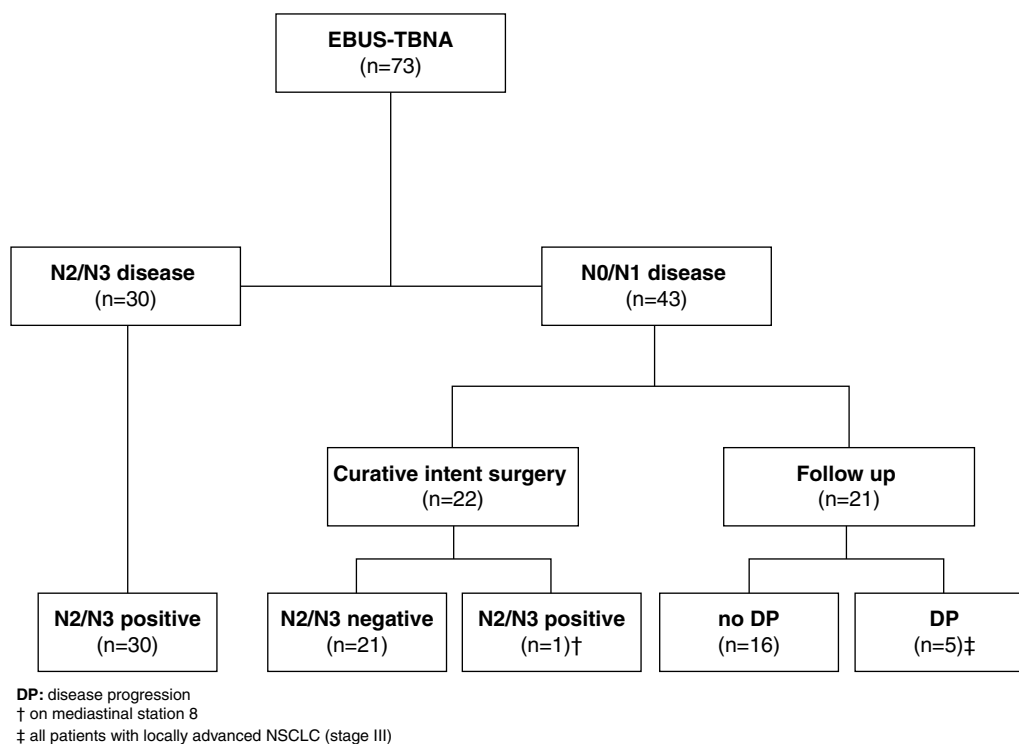
A total of 49 patients were not included in our EBUS staging performance evaluation (38 patients were lost to follow up as they were referred from other institutions, 2 patients had a surgical related complication, and 9 patients received induction chemotherapy). From this remaining group of patients ( $n=73$ ), EBUS-TBNA demonstrated N2 disease in 21 and N3 disease in 9 patients (a total of 30 (41.1%) patients). The determination of N2/N3 disease was based on malignant cytological results at EBUS-TBNA and all these patients were recorded as true positive.

Forty-three patients with suspected malignant lymphadenopathy had N0/N1 disease by EBUS-TBNA. Out of these, 22 patients underwent curative intent surgery with complete thoracic lymphadenectomy (14 patients had been previously submitted to mediastinoscopy, all confirming EBUS-TBNA previous findings) that confirmed N0/N1 disease in all but one patient, who had N2 disease unreachable by EBUS or mediastinoscopy (station 8). The remaining twenty-one patients were not eligible for curative intent surgery (due to patient's comorbidities or to non-surgical locoregional disease) and had at least 6 months clinical follow-up following multidisciplinary determined treatment approach. Five patients demonstrated clinical or radiologic progression in this follow-up period and were recorded as false negative (Fig. 1).

The comparison of EBUS-TBNA results with the final staging obtained by surgical staging or clinical follow-up is shown in Table 2. In our study population, EBUS-TBNA performance in the correct prediction of lymph node stage, including areas unreachable by EBUS had a sensitivity of 83.3%, specificity of 100%, positive predictive value of 100%, negative predictive value of 86.1%, and diagnostic accuracy rate of 91.8%.

## Discussion

Accurate staging is a key factor in the assessment of NSCLC patients, not only as a prognosis definer but also in the decision process of the most suitable treatment plan for both surgical and nonsurgical patients. Therefore, a reliable preoperative assessment of lymph node involvement has a crucial effect on prognosis and therapy. Our results confirm that EBUS-TBNA is a safe and effective assessment method of mediastinal lymph nodes in patients with NSCLC, and that it should play a central role as a part of a comprehensive lung cancer staging strategy.



**Figure 1** Clinical course of the 73 patients included in our final analysis.

Additionally, in around 20% of our study population, EBUS-TBNA was the primary diagnostic procedure, reinforcing the point that in selected cases lung cancer diagnosis and staging is achievable with a single endoscopic technique. A recent randomized controlled trial<sup>7</sup> showed that EBUS-TBNA, used as initial investigation for patients with suspected lung cancer reduces the time to treatment decision at no additional cost, when compared with conventional diagnosis and staging techniques.

EBUS-TBNA performance for mediastinal staging of NSCLC patients has been extensively described and our results are consistent with previously published reports, with several systematic reviews and meta-analyses reporting the yield of nodal staging for NSCLC by EBUS-TBNA to have a pooled sensitivity of 88–93% and a pooled specificity of 100%.<sup>5</sup> EBUS-TBNA (alone or combined with EUS-FNA) diagnostic yield was proved to be at least similar to that of mediastinoscopy,<sup>5,7–10</sup> suggesting that mediastinoscopy is rarely needed for the preoperative staging of NSCLC in clinical practice when EBUS-TBNA is available.<sup>5,7</sup> Our study results reinforce this knowledge, because mediastinoscopy was unable to detect any false negative lymph nodes in the 14 EBUS-TBNA negative patients that were concomitantly submitted to mediastinoscopy. In fact, these results allowed a change in our center NSCLC staging methodology, with mediastinoscopy performance in EBUS staged N0/N1 patients being dropped from our clinical practice.

Despite being in line with previous studies, our sensitivity rate was slightly affected by the number of false negative cases, especially among patients with non-surgical criteria and on clinical follow up. All these latter five patients had a clinical staging compatible with locoregional disease (stage

III), which negatively impacted on their progression free survival (PFS), even though they had N0/N1 mediastinal staging at the time of diagnosis.

Additionally, only one patient had a surgically confirmed N2 disease not detected by EBUS-TBNA and/or mediastinoscopy. This was due to one of the major limitations of EBUS-TBNA in mediastinal staging: its inability to image and access mediastinal lymph nodes that are not adjacent to the airways, such as the prevascular nodes (3a), the subaortic and para-aortic nodes (5 and 6), and the paraesophageal and pulmonary ligament nodes (8 and 9). EUS-FNA can access stations 8 and 9; and in combination with EBUS-TBNA, the majority of mediastinum and hilar area can be assessed with, as previously referred, a higher diagnostic yield and fewer unnecessary thoracotomies.<sup>5,8,10</sup> The practical limitation of EUS-FNA is that its transesophageal approach is usually unfamiliar to most pulmonologists, while EBUS-TBNA can be easily performed during bronchoscopy.

As shown by previous studies, the presence of an experienced pathologist during the procedure can play a crucial role since it reduces the number of inadequate samples, false-negatives and punctures with the advantage of shortening procedure time,<sup>11</sup> and from our experience we think that the presence of ROSE in the vast majority of our procedures represents an important asset in our clinical practice. As a matter of fact, we had in our series a total of 10 inconclusive lymph nodes, corresponding to 6 patients. Four of them were staged as N2 or N3 and had an inconclusive lymph node in an inferior N station. The other two patients had only one inconclusive lymph node each, with sonographic features and dimensions not suggestive of malignancy, negative PET scan and the N0 staging was confirmed through surgical procedure.

We did not experience any major complications. Often a minor oozing of blood at the site of puncture was observed but no patient had significant bleeding, pneumothorax, or pneumomediastinum which confirms the safety of EBUS-TBNA.

## Conclusion

A comprehensive lung cancer staging strategy that includes EBUS-TBNA seems to be safe and effective. Our EBUS-TBNA performance and safety in this particular setting was in line with previously published reports. Mediastinoscopy did not detect any false negative nodes, questioning the need for preoperative staging of NSCLC by mediastinoscopy in clinical practice. Additionally, our study showed that, in selected patients, lung cancer diagnosis and staging are achievable with a single endoscopic technique.

## Conflict of interest

The authors certify that there is no actual or potential conflict of interest in relation to this article.

## Author contributions

Daniel Coutinho and Ana Oliveira conceived the project idea. Ana Oliveira, Sofia Neves and Sérgio Campaignha performed all endoscopic procedures. José Miranda and Miguel Guerra performed all surgical procedures. Agostinho Sanches, David Tente and Antónia Furtado were responsible for cytopathologic analysis. Daniel Coutinho, Ana Oliveira, Sérgio Campaignha and Sofia Neves collected the data and conducted the analysis. All authors interpreted and discussed the results. Daniel Coutinho and Ana Oliveira wrote the manuscript. All authors have read and approved the final version.

## Ethical disclosures

**Protection of human and animal subjects.** The authors declare that no experiments were performed on humans or animals for this investigation.

**Confidentiality of data.** The authors declare that they have followed the protocols of their work centre on the publication of patient data.

**Right to privacy and informed consent.** The authors must have obtained the informed consent of the patients and/or

subjects mentioned in the article. The author for correspondence must be in possession of this document.

## References

1. Jemal A, Bray F, Center MM, Ferlay J, Ward E, Forman D. Global cancer statistics. *CA Cancer J Clin.* 2011;61:69–90.
2. Miranda N, Nogueira PJ, Silva AJ, Rosa MV, Alves MI, Afonso D, et al. Doenças oncológicas em números, 2013: programa nacional para as doenças oncológicas. Lisboa: Direção-Geral da Saúde; 2013. Available from: <http://www.dgs.pt/estatisticas-de-saude/estatisticas-de-saude/publicacoes/portugal-doencas-oncologicas-em-numeros-2013.aspx>
3. Ettinger DS, Akerley W, Bepler G, Blum MG, Chang A, Cheney RT, et al. Non-small cell lung cancer. *J Natl Compr Canc Netw.* 2010;8:740–801.
4. Toloza EM, Harpole L, McCrory DC. Noninvasive staging of non-small cell lung cancer: a review of the current evidence. *Chest.* 2003;123 Suppl. 1:137S–46S.
5. Inage T, Nakajima T, Yoshino I. Staging lung cancer: role of endobronchial ultrasound. *Lung Cancer Targets Therapy.* 2014;5:67–72.
6. Toloza EM, Harpole L, Detterbeck F, McCrory DC. Invasive staging of non-small cell lung cancer: a review of the current evidence. *Chest.* 2003;123 Suppl. 1:157S–66S.
7. Navani N, Nankivell M, Lawrence DR, Lock S, Makker H, Baldwin DR, et al. Lung cancer diagnosis and staging with endobronchial ultrasound-guided transbronchial needle aspiration compared with conventional approaches: an open-label, pragmatic, randomised controlled trial. *Lancet Respir Med.* 2015;3: 282–9.
8. Szlubowski A, Zieliński M, Soja J, Annema JT, Sołnicki W, Jakubiak M, et al. A combined approach of endobronchial and endoscopic ultrasound-guided needle aspiration in the radiologically normal mediastinum in non-small-cell lung cancer staging – a prospective trial. *Eur J Cardiothorac Surg.* 2010;37: 1175–9.
9. Yasufuku K, Pierre A, Darling G, de Perrot M, Waddell T, Johnston M, et al. A prospective controlled trial of endobronchial ultrasound-guided transbronchial needle aspiration compared with mediastinoscopy for mediastinal lymph node staging of lung cancer. *J Thorac Cardiovasc Surg.* 2011;142: 1393–400.
10. Sharples LD, Jackson C, Wheaton E, Griffith G, Annema JT, Dooms C, et al. Clinical effectiveness and cost-effectiveness of endobronchial and endoscopic ultrasound relative to surgical staging in potentially resectable lung cancer: results from the ASTER randomised controlled trial. *Health Technol Assess.* 2012;16:1–75, iii–iv.
11. Gilbert S, Wilson DO, Christie NA, Pennathur A, Luketich JD, Landreneau RJ, et al. Endobronchial ultrasound as a diagnostic tool in patients with a mediastinal lymphadenopathy. *Ann Thorac Surg.* 2009;88:896–902.