

Other authors have suggested that the process is like a congenital malformation with slow progression and not a sequela of pre-existing emphysema, but no PPT has been reported in children.<sup>4,6</sup> McChesney has thought that placental transmogrification might represent an unrecognized pulmonary hamartoma. The exact relationship between this and hamartoma, has not yet become clear.<sup>1</sup> Xu et al.<sup>2</sup> found that all pulmonary hamartomas show varying degrees of development of papillary structures, lined by a single layer of epithelial cells or with epithelial invagination into stroma. Depending on the size of papillary growth, hamartomas can have minimal epithelial clefting, with a small number of epithelial projections, up to those with a large number of tall villus-like projections. This exaggeration of epithelial clefting may be an explanation for the papillary pattern. In our opinion it probably results from the development of oedema, fibrosis, and chronic inflammation in the residual alveolar tissues.

PPT is regarded as an unusual benign lesion curable by surgical resection. As Brevetti et al.<sup>7</sup> described, we believe that these lesions are best treated by minimal resection, leaving as much normal lung tissue as feasible and if possible avoiding a lobectomy. After surgery, all our patients have been followed-up by monitoring imaging techniques. There was no evidence of recurrent disease or the appearance of new tumours in other locations, during a follow-up period that ranged between 36 and 108 months (average, 72 months).

As far as we know, this is the first comprehensive and updated work carried out in Portugal, also the first series of PPT in this country, the first largest series of a single centre in Europe and the second in the medical English literature. Just 30 cases have been described in the literature, all associated with emphysema or hamartoma. Our study is the first and the only centre that has presented this lesion in its two forms (hamartomatous and emphysematous).

## Conflict of interest

None declared.

## Acknowledgements

We thank Paula Plim for the English review.

## References

1. McChesney T. Placental transmogrification of the lung: a unique case with remarkable histopathologic feature. *Lab Invest.* 1979;40:245–6.
2. Xu R, Murray M, Jagirdar J, Delgado Y, Melamed J. Placental transmogrification of the lung is a histologic pattern frequently associated with pulmonary fibrochondromatous hamartoma. *Arch Pathol Lab Med.* 2002;126:562–6.
3. Marchevsky AM, Guintu R, Koss M, Fuller C, Houck W, McKenna RJ. Swyer–James (MacLeod) syndrome with placental transmogrification of the lung: a case report and review of the literature. *Arch Pathol Lab Med.* 2005;129:686–9.
4. Kim JW, Park IH, Kwon W, Eom MS, Kim YJ, Oh JH. Placental transmogrification of the lung. *Korean J Radiol.* 2013;14:977–80.
5. Fidler ME, Koomen M, Sebek B, Greco MA, Rizk CC, Askin FB. Placental transmogrification of the lung, a histologic variant of giant bullous emphysema. *Clinicopathological study of three further cases.* *Am J Surg Pathol.* 1995;19:563–70.
6. Theile A, Müller KM. Placentoid malformation of the lung. *Pathologie.* 1998;19:134–40.
7. Brevetti GR, Clary-Macy C, Jablons DM. Pulmonary placental transmogrification: diagnosis and treatment. *J Thorac Cardiovasc Surg.* 1999;118:966–7.

S. Ortiz\*, F. Tortosa

*Department of Pathology, Centro Hospitalar Lisboa Norte, EPE – Hospital de Santa Maria, Lisbon Portugal*

\* Corresponding author.

*E-mail address:* [santi.orfer@gmail.com](mailto:santi.orfer@gmail.com) (S. Ortiz).

<http://dx.doi.org/10.1016/j.rppnen.2017.02.007>  
2173-5115/

© 2017 Sociedade Portuguesa de Pneumologia. Published by Elsevier España, S.L.U. This is an open access article under the CC BY-NC-ND license (<http://creativecommons.org/licenses/by-nc-nd/4.0/>).

## CT-guided transthoracic lung diagnostic procedures: A 5 year experience



Computerized tomography (CT)-guided transthoracic diagnostic procedures are effective and safe techniques, and may help avoid thoracic surgery for the diagnosis of intrathoracic lesions. Fine needle aspiration (FNA) provides material for cytological analysis, core biopsy (CB) provides a sample for histologic examination.

The aim of our study was to evaluate the diagnostic accuracy and complication rate of both FNA and CB in pulmonary lesions suspected of malignancy.

A retrospective analysis of CT-guided transthoracic interventional procedures completed in the Radiology Department, between January 2008 and January 2013, was

performed. Patients with a pulmonary lesion suspected of malignancy, on chest CT, were included in the study.

All patients underwent a coagulation study. Anticoagulant and antiplatelet therapy had been previously interrupted. An axial acquisition prior to the procedure was obtained. The CT equipment was Philips® Brilliance 16P. A 22G spinal needle was used for the FNA, and an 18G semi-automatic needle *tru-cut* gauge system for CB. The shortest intraparenchymal needle path was chosen. The usual number of needle passes was 2 (1–3). The occurrence of complications, including pneumothorax and bleeding was identified through CT images obtained immediately after needle removal. After the procedure, patients remained under observation in the Department of Pulmonology for 6 h, with clinical evaluation before discharge.

The results of the procedures were compared with the diagnosis obtained from the integration of clinical evolution,

**Table 1** Sample Characteristics.

Characteristics	Study population (n = 140)
FNA and CB (n)	140
Sex (male)	91 (65%)
Age (years; median [QR])	67.5 (58.8;76)
Distance to the pleura (mm; mean [SD])	9.2 ( $\pm$ 15.5)
Lesion size (mm; median [QR])	40.2 (26.7;60.8)
Nodule/mass	29.3%/70.7%
FNA/CB/Both	14.3%/83.6%/2.1%

FNA – fine needle aspiration, CB – core biopsy.

radiological follow-up, and histological result (in patients submitted to surgery) for at least 12 months after the procedure.

The relationship of procedural factors and risk of complications was analyzed separately for each variable. For qualitative variables Qhi-square test was used, for quantitative variables we used the Mann–Whitney test. Statistical analysis was performed using SPSS version 22.0. A  $p < 0.05$  was considered as statistically significant.

During the study period, a total of 150 procedures were requested and 140 were performed. Ten patients were excluded, due to a high degree of emphysema ( $n=3$ ), vascular proximity ( $n=2$ ), stability ( $n=3$ ) or disappearance of the lesion ( $n=2$ ). The demographic characteristics are summarized in [Table 1](#).

Most of the lesions [122 (87.1%)] were in the pulmonary parenchyma, 10 (7.1%) in the mediastinum and 8 (5.7%) in the pleura. The mean lesion size was 40.2 mm (26.7–60.8). The mean lesion depth from the skin surface was  $9.2 \pm 15.5$  mm to the pleura. The majority ( $n=108$ ) of patients had only one lesion, 7 had two lesions and 25 patients had three or more lesions. CB was performed in 117 (83.6%) and FNA in 20 (14.3%) procedures. In 3 (2.1%) patients, FNA and subsequently CB were performed, due to the inadequacy of the sample with the first technique. In 5 (25%) cases of FNA, two needle passes were performed. In the other cases just one needle pass was done.

Complications occurred in 8 (5.7%) procedures; namely 5 (3.6%) intraparenchymatous haemorrhages, 2 (1.4%) pneumothoraxes (one required chest tube drainage) and one case of haemoptysis. Risk factors for complications were analyzed ([Table 2](#)). Only the distance to the pleura was significant ( $p=0.01$ ), as a higher distance contributed to a greater complication rate. There was no significant relationship between the rate of complications and the location or diameter of the lesion, number of needle passes, the technique used or the presence of emphysema ( $p > 0.05$ ).

A diagnosis was obtained in 119 (85%) procedures. Eighty-four lesions (60%) were malignant, 35 (25.2%) were benign, and 21 (14.8%) were inconclusive in terms of diagnosis ([Table 2](#)).

It was possible to obtain a diagnostic confirmation in 102 (85.7%) procedures. The diagnostic accuracy for malignancy was 85.2% without differences between FNA and CB ( $p=0.73$ ). The sensitivity, specificity, PPV and NPV for

**Table 2** Pathology results.

Diagnosis	n (%)
<i>Neoplastic diseases</i>	84 (60%)
Adenocarcinoma	37
Metastatic cancer	22
Squamous cell carcinoma	17
Small cell carcinoma	8
<i>Benign lesions</i>	35 (25.2%)
Hamartoma	1
Tuberculosis	2
Bronchogenic cyst	1
Solitary fibrous tumour	1
Unspecific pleurisy	5
Sarcoidosis	1
Cryptogenic organizing pneumonia	4
Inflammation	20
<i>No diagnosis</i>	21 (14.8%)
Insufficient material	8
Inadequate sample	13

malignant lesions was 96.5%, 100%, 100% and 92.3% respectively, similar to those reported in the literature.<sup>1–3</sup>

The frequency of complications was lower than that described in most studies.<sup>4,5</sup> The most frequent complication was haemorrhage and then pneumothorax, as opposed to what is usually reported, haemorrhage (2–10%) and pneumothorax (8% - 54%).<sup>1,4</sup> The low rate of pneumothorax may be due to the fact that only 5.7% ( $n=8$ ) of the lesions were located in the pleura, to the exclusion of patients with important emphysema, to the great experience of the operator and to the fact that a chest X-ray was not routinely done before patient discharge. Although the location or diameter of the lesion,<sup>5</sup> density of the lesion, number of needle passes or the presence of emphysema can influence the rate of complications<sup>6,7</sup> it was not observed in our series ( $p > 0.05$ ). A longer distance between the lesion and the pleura contributed significantly to a higher risk of complications.<sup>5</sup>

The low complication rate made analysis of the procedural factors difficult, contributing to the risk of complications.

Our series confirmed FNA and CB as safe, minimally invasive and accurate techniques that can be performed for the diagnosis of lung cancer.

## Conflicts of interest

The authors have no conflicts of interest to declare.

## References

- Loh SE, Wu DD, Venkatesh SK, Ong CK, Liu E, Seto KY, et al. CT-guided transthoracic biopsy: evaluation diagnostic yield and complications. *Ann Acad Med.* 2013;42:285–90.
- Laurent F, Latrabe V, Vergier B, Mountadon M, Mernejoux JM, Dubrez J. CT-guided transthoracic needle biopsy of pulmonary nodules smaller than 20mm: results with an automated

- 20-gauge coaxial cutting needle. *Clin Radiol.* 2000;55:281–7.
- Geraghty PR, Kee ST, McFarlane G, Razavi MK, Sze DY, Dake MD. CT-guided transthoracic needle aspiration biopsy of pulmonary nodules: needle size and pneumothorax rate. *Radiology.* 2003;229:475–81.
  - Dennie CJ, Matzinger FR, Marriner JR, Maziak DE. Transthoracic needle biopsy of the lung: results of early discharge in 506 outpatients. *Radiology.* 2001;219:247.
  - Yeow KM, Su IH, Pan KT, Tsay PK, Lui KW, Cheung YC, et al. Risk factors of pneumothorax and bleeding: multivariate analysis of 660 CT-guided coaxial cutting needle biopsies. *Chest.* 2004;126:748–54.
  - Ohno Y, Hatabu H, Takenaka D, Higashino T, Watanabe H, Ohbayashi C, et al. CT-guided transthoracic needle aspiration biopsy of small (20mm) solitary pulmonary nodules. *Am J Roentgenol.* 2003;180:1665–9.
  - Wallace M, Krishnamurthy S, Broemeling L, Gupta S, Ahrar K, Morello F, et al. CT-guided percutaneous fine-needle aspiration biopsy of small (<1-cm) pulmonary lesions. *Radiology.* 2002;225:823–8.

C. Dias<sup>a,\*</sup>, R. Reis<sup>b</sup>, C. Oliveira<sup>c</sup>, I. Candelária<sup>c</sup>, T. Couto<sup>d</sup>, A. Estevão<sup>c</sup>

<sup>a</sup> Centro Hospitalar de São João, Porto, Portugal

<sup>b</sup> Pulmonology Department, Centro Hospitalar do Porto, Porto, Portugal

<sup>c</sup> Radiology Department, Centro Hospitalar e Universitário de Coimbra, Coimbra, Portugal

<sup>d</sup> Radiology Department, Centro Hospitalar do Porto, Porto, Portugal

\* Corresponding author.

E-mail address: [catarinadias1@gmail.com](mailto:catarinadias1@gmail.com) (C. Dias).

<http://dx.doi.org/10.1016/j.rppnen.2016.12.009>  
2173-5115/

© 2017 Published by Elsevier España, S.L.U. on behalf of Sociedade Portuguesa de Pneumologia. This is an open access article under the CC BY-NC-ND license (<http://creativecommons.org/licenses/by-nc-nd/4.0/>).

## Role of flexible bronchoscopy in non-resolving community-acquired pneumonia – A retrospective analysis



Dear Editor,

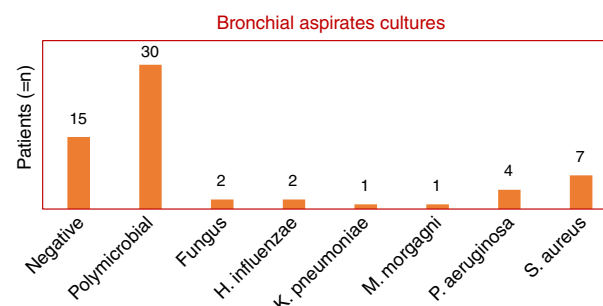
The role of flexible bronchoscopy (FB) in patients diagnosed with community-acquired pneumonia (CAP) is not clearly defined. The etiologic diagnosis of CAP is known to be a medical problem.<sup>1</sup> In about 40% of CAP cases the causative organism remains unknown.<sup>2</sup> The most common microorganisms in CAP are *Streptococcus pneumoniae* (*S. pneumoniae*), although recent studies have described an increased frequency of other microorganisms. Proper treatment of CAP is crucial and early FB may change the prognosis especially in non-resolving CAP, FB can play a key role in the clinical outcome.<sup>1</sup>

Investigate the contribution of FB in patients with non-resolving CAP in relation to etiological diagnosis, change in treatment strategy, days of hospitalization and hospital mortality.

A retrospective analysis of patients with non-resolving CAP admitted to the Pulmonology ward of Coimbra University Hospital submitted to FB during the year 2014 was carried out. Information on clinical, radiological, laboratory, specifically microbiology aspirates and bronchial lavage and antibiotic treatment was collected. Non resolving CAP was defined as a persistence of pulmonary infiltrates in chest X-ray associated with persistence of typical respiratory symptoms in the absence of an alternative diagnosis despite 72 h of antibiotic therapy.<sup>3</sup> Bronchial aspiration was performed on all patients and when possible a bronchoalveolar lavage using 10–50 ml of warm saline fluid was also performed. All specimens collected were sent to the microbiology laboratory. The criteria for infection of bronchial aspirates were the presence of colony forming units (CFU)

greater than 10<sup>5</sup> per ml and bronchial lavage exceeding 10<sup>4</sup> CFU per ml. Intensive Care Unit patients and immunocompromised patients (very poor general condition, taking immunosuppressive drugs, with human immunodeficiency virus infection or active tuberculosis) were excluded from our study.

This study included 48 patients, 36 men and 12 women, with a mean and standard deviation age of 69 ± 17 years vs 67 ± 18, respectively. Non-resolving CAP accounted for 40% of all CAP admissions. Bronchial aspirate cultures were negative in 15 patients (24%), polymicrobial in 30 patients (49%) and positive in 17 patients (27%). Fungi were found in two patients (1 with *Aspergillus fumigatus* and 1 with *Candida albicans*). The bacterial microorganisms identified were: *Haemophilus influenzae* (two patients), *Klebsiella pneumoniae* (one patient), *Morganella morganii* (one patient), *Pseudomonas aeruginosa* (four patients) and *Staphylococcus aureus* (six methicillin-resistant (MRSA) and one methicillin-sensitive (MSSA)) (Graphic 1). Bronchoalveolar lavage was performed on only 37 patients, of whom 11 had a microorganism isolated as follows: *C. albicans* (one patient), *H. influenzae* (two patients), *M. morganii* (one patient), *P. aeruginosa* (two patients) and *S. aureus* (four MRSA and one MSSA). The remaining bronchial washings



Graphic 1 Cultural results of bronchial aspirates performed in all patients undergoing flexible bronchoscopy (total 48 patients).