

anti-immunoglobulin E antibody (omalizumab) in severe allergic asthma. *Clin. Exp. Allergy*. 2004;34:632–8.

10. Samitas K, Delimpoura V, Zervas E, Gaga M. Anti-IgE treatment, airway inflammation and remodelling in severe allergic asthma: current knowledge and future perspectives. *Eur Respir Rev*. 2015;24:594–601.

R. Aguiar^{a,*}, N.P. Fernandes^a, A. Lopes^a, C. Lopes^b

^a *Immunoallergy Department, Hospital de Santa Maria, Centro Hospitalar Lisboa Norte, Lisbon, Portugal*

^b *Pneumology Department, Hospital de Santa Maria, Centro Hospitalar Lisboa Norte, Lisbon, Portugal*

* Corresponding author.

E-mail address: aguiaar2016@gmail.com (R. Aguiar).

<http://dx.doi.org/10.1016/j.rppnen.2017.05.006>
2173-5115/

© 2017 Sociedade Portuguesa de Pneumologia. Published by Elsevier España, S.L.U. This is an open access article under the CC BY-NC-ND license (<http://creativecommons.org/licenses/by-nc-nd/4.0/>).

Atypical pyoderma gangrenosum simulating pectoral abscess managed using negative pressure wound therapy



To the Editor,

Pyoderma gangrenosum (PG) is an ulcerative neutrophilic dermatosis of uncertain aetiology that is generally found in the extremities. It usually presents as painful skin ulcers.

We present a case of a patient with atypical PG that was satisfactorily treated using negative pressure wound therapy (NPWT) and immunosupresor therapy.

A 35-year-old female with inflammatory intestinal disease and a history of PG in lower extremities during pregnancy, was sent to our institution for pain and swelling at paraesternal level of 3 days of evolution without previous traumatism of the region. We performed a chest CT scan that revealed the presence of an erosive arthropathy of the left sternoclavicular joint; with a lesion of 30 mm in the thickness of the ipsilateral pectoral musculature related to an abscess (Fig. 1). We punctured the lesion under ultrasound control. This revealed purulent material, which we later drained, before wide debridement of the abscess and starting empirical antibiotic treatment.

Over the days following the drainage, the patient's evolution was negative with a large increase in purulent exudate from the wound, fever and signs of sepsis with progression of the ulcer (Fig. 2A and B).

All the microbiological cultures were negative, so as we suspected PG, a tissue sample was sent for a histopathological study.

In view of the fact that the wound was clearly worsening, combined with the impossibility of controlling the exudate we decided to place a NPWT system, combined with intensive immunosupresor therapy and broad-spectrum antibiotics (Fig. 2C).

Seven days after starting treatment with NPWT the exudate was controlled and the ulcer had stabilised, with granulated tissue appearing at the back of the wound (Fig. 2D). Thus the NPWT system was removed to prevent the growth of ulcer secondary to pathergy that could cause the NPWT system.

Finally the histopathological study of the tissue sample demonstrated central necrosis and ulceration of the epidermis and dermis surrounded by an intense acute inflammatory cell infiltrate, with a peripheral mixed to chronic inflammatory cell infiltrate. We also looked for neutrophils and fibrin in superficial vessels without histologic evidence of vasculitis. All of these findings were PG-compatible features.

The patient's evolution was finally successful, and complete healing of the ulcer achieved 4 months after onset of symptoms (Fig. 2E).

Pyoderma gangrenosum is a neutrophilic dermatosis, which was first described by Brocq in 1916 and later named by Brunsting in 1930, which is characterised by papules, pustules or vesicles in the skin that quickly transform into a painful ulcer with violet, raised and up to 20 cm diameter margins.

PG has an incidence of 0.3–1/100,000 and typically affects middle-aged patients. Four clinical variants of PG have been described: the ulcerative, pustular, bullous and vegetative type. In 80–90% of patients the lesions are reported in the lower limbs, though they may be seen in any part of the human topography, as was the case of our patient who had had a first episode of PG in lower limbs and a recurrence years later in the chest.¹

The diagnosis of PG, as in our case, is usually reached by exclusion, although frequently the typical morphology of the injury will lead us to suspect its presence. There is no specific treatment and PG management consists of suppression of the inflammatory activity, treatment of the underlying disease, the promotion of ulcer healing and pain control.

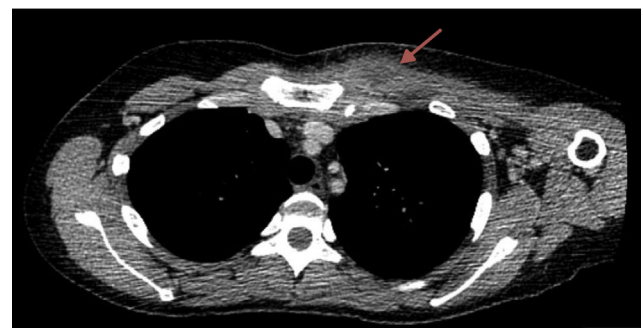


Figure 1 CT chest scan showing a 3 cm diameter lump at the level of the left pectoral muscle (arrow).

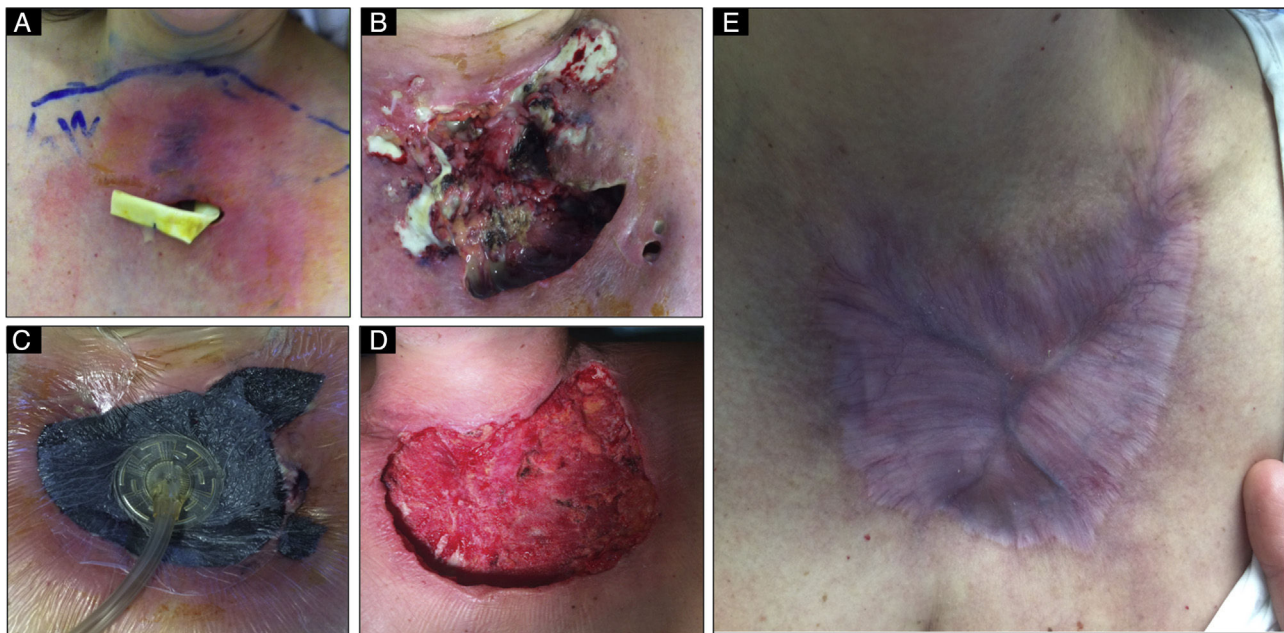


Figure 2 Different evolutionary stages of the disease. (A, B) Rapidly progressive ulcer with abundant purulent exudate. (C) Application of the system of negative aspiration (NPWT) on the ulcer bed. (D) Result after 7 days using the NPWT system and immunosuppression, where we can observe the disappearance of the exudate and the emergence of granulation tissue. (E) 6 months after onset we can observe that the lesion is fully healed.

In 2006, Niezgoda and cols. described the use of NPWT systems in managing PG for the first time. Nevertheless, there is still currently some controversy about the use of these systems in some wounds, such as those produced by PG where any traumatic handling of the wound can lead to worsening, a phenomenon termed pathergy, especially when the treatment is performed without suitable immunosuppression of the patient.² This controversy exists even *in vitro* and *in vivo* studies. It has been shown that NPWT applied to a wound helps the healing of the wound since it reduces oedema, favours the emergence of granulation tissue, increases tissue perfusion and cleans the exudate from the wound, thus reducing the local bacterial load. Therefore, NPWT can become a valid alternative therapy.^{3,4} In this way, as in our case, initial use of NPWT combined with suitable immunosuppression was a reliable system for treating PG of difficult clinical management, and produced a satisfactory evolution. Although there are few long series in the literature to prove it, NPWT could become another valid pillar in treating PG in the future.²⁻⁴

In conclusion we present a PG case with an atypical presentation simulating an abscess of the pectoral muscle, which caused a delay in diagnosis and therefore in deciding on the immunosuppressive treatment. As described above, the consequence was that the ulcer got worse and it was necessary to use a NPWT system associated with corticotherapy treatment to finally obtain a satisfactory evolution.

Conflicts of interest

The authors have no conflicts of interest to declare.

References

1. Al Ghazal P, Herberger K, Schaller J, Strölin A, Hoff N, Goerge T, et al. Associated factors and comorbidities in patients with pyoderma gangrenosum in Germany: a retrospective multicentric analysis in 259 patients. *Orphanet J Rare Dis.* 2013;8:136.
2. Cabalag MS, Wasiak J, Lim SW, Raiola FB. Inpatient management of pyoderma gangrenosum: treatments, outcomes, and clinical implications. *Ann Plast Surg.* 2015;74:354–60.
3. Geller SM, Longton JA. Ulceration of pyoderma gangrenosum treated with negative pressure wound therapy. *J Am Podiatr Med Assoc.* 2005;95:171–4.
4. Pichler M, Larcher L, Holzer M, Exler G, Thuile T, Gatscher B, et al. Surgical treatment of pyoderma gangrenosum with negative pressure wound therapy and split thickness skin grafting under adequate immunosuppression is a valuable treatment option: case series of 15 patients. *J Am Acad Dermatol.* 2016;74:760–5.

J. Soro-García*, E.M. García-Fontán,
R. Carrasco-Rodríguez, M. Blanco-Ramos,
M.A. Cañizares-Carretero

Thoracic Surgery Department, Alvaro Cunqueiro University Clinical Hospital, EOXI Vigo, Spain

* Corresponding author.

E-mail address: josesorogarcia@gmail.com (J. Soro-García).

<http://dx.doi.org/10.1016/j.rppnen.2017.05.007>
2173-5115/

© 2017 Sociedade Portuguesa de Pneumologia. Published by Elsevier España, S.L.U. This is an open access article under the CC BY-NC-ND license (<http://creativecommons.org/licenses/by-nc-nd/4.0/>).