

Lung cancer in pregnancy – Report of a case treated with crizotinib[☆]



To the Editor,

The diagnosis of cancer during pregnancy is rare and constitutes a clinical challenge because of treatment implications and potential risk for the pregnant woman and the fetus.^{1,2} The authors describe a case of advanced lung cancer diagnosed during pregnancy and its therapeutic approach.

The patient was a 36 years-old pregnant female, with previous history of lower limbs varicose veins surgery. There was no other relevant medical history or family history of oncological diseases. At 18 weeks of gestation, the patient presented to the emergency department complaining of non-productive cough, dyspnea on exertion, left posterior pleuritic chest pain and asthenia; with no fever associated. Decreased breath sounds in left hemithorax were noted. A left pleural effusion was detected on chest radiograph and a thoracentesis was performed, leading to her hospitalization at 22 weeks of gestation. Pleural fluid had characteristics of an exudate and cytology was compatible with adenocarcinoma of primary pulmonary origin [thyroid transcription factor 1 (TTF-1) positive staining], positive for echinoderm microtubule-associated protein-like 4-anaplastic lymphoma kinase (EML4-ALK) translocation. For dyspnea relief, a chest tube was inserted. No relevant abnormal findings were detected on breast and abdominal ultrasound or on abdominopelvic magnetic resonance. Thoracic computed tomography (CT) revealed a pulmonary mass in the left lower lobe, with perihilar localization and partial atelectasis of this lobe, as well as interlobular septal thickening, suggestive of lymphangitic carcinomatosis (Fig. 1). Talc pleurodesis was performed, due to fast pleural effusion recurrence, which proved to be effective. At the multi-disciplinary team board meeting, it was decided to start targeted therapy with crizotinib 250 mg *bid*, at 26 weeks of gestation. No side effects related to this therapy were detected, however, no clinical or radiological improvement was observed. Meanwhile, there was disease progression

with a breast metastasis of lung adenocarcinoma. Due to worsening of general condition, it was decided to perform caesarean delivery at 30 weeks of gestation. The newborn was healthy, but adenocarcinoma cells were identified in placental pathological examination. At disease restaging (Fig. 2), skeletal scintigraphy confirmed the presence of multifocal bone metastasis and abdominal ultrasonography showed multiple hepatic metastasis and ascites, with positive cytology. On D45 crizotinib, 15th day of puerperium, due to the rapid progression, it was decided to suspend it and initiate chemotherapy with carboplatin and pemetrexed, while waiting for ceritinib approval, completing 2 cycles of chemotherapy. Subsequently, the patient initiated ceritinib, dying 15 days later. To date, the child follow-up at 29 months exhibited regular development.

Given the lack of safety profile studies of the different chemotherapy regimens and target therapies during pregnancy, it is essential to report clinical cases and to share evidence about the use of antineoplastic therapies during the gestation period. This is of utmost importance in an era in which the incidence of lung cancer during pregnancy is expected to increase, which might be partially related to higher mean age of pregnancy and increase in tobacco consumption by women.¹⁻³ As far as we know this is the first case report of administration of crizotinib, an anti-neoplastic target therapy, during pregnancy. In this case, this therapy does not seem to have caused any harm to the newborn; however, a longer follow-up period will be necessary to assess the exposed child. In fact, most cases of lung cancer in pregnancy are diagnosed in an advanced stage and might progress to dyspnea which is difficult to relieve or a life threatening condition, which strongly influences the therapeutic options.¹⁻³ It is a huge challenge to decide on the best approach and management of cancer during pregnancy, attempting to choose the optimal anti-cancer regimen to treat the pregnant women without harming the developing fetus. Most chemotherapeutic agents are considered relatively safe when administered in the second and third trimesters and are not associated with major congenital malformations, although an increase

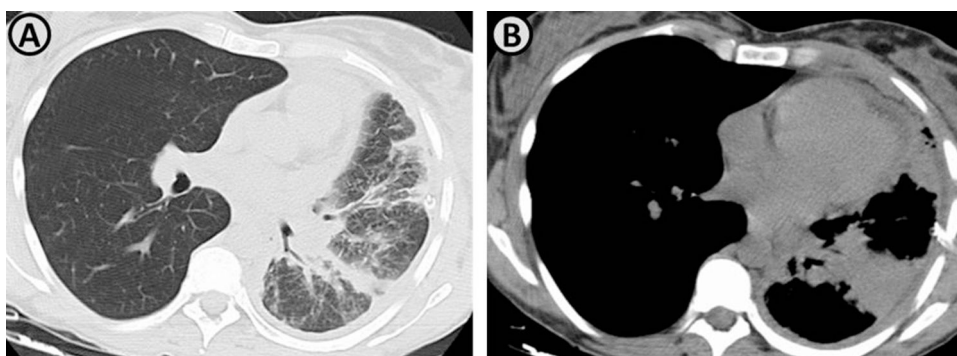


Figure 1 (A and B) Axial thoracic computed tomography images demonstrate the presence of a pulmonary mass in the left lower lobe, with perihilar localization, conditioning partial atelectasis of this lobe. There is also seen interlobular septal thickening, suggestive of lymphangitic carcinomatosis.

[☆] Address of the institution at which the work was performed: Alameda Prof. Hernâni Monteiro, 4200-319 Porto, Portugal.

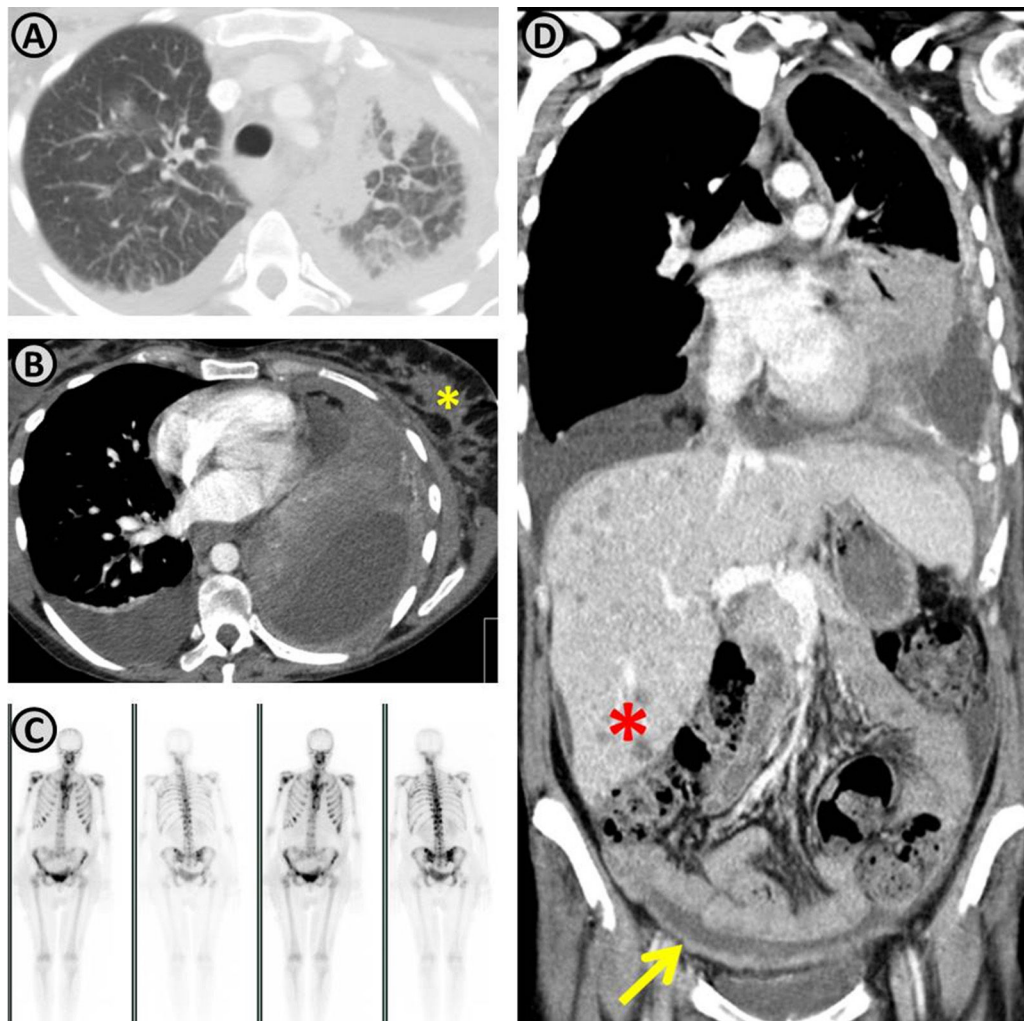


Figure 2 Restaging demonstrating disease progression. (A and B) Increasing of the lung mass and the extent of lymphangitic carcinomatosis; in the mediastinal images (B) a breast metastasis is observed (yellow asterisk). (C) Presence of multifocal bone metastasis. (D) Coronal reconstruction demonstrating progression of the lung mass, multiple hepatic nodules (red asterisk) suggestive to be metastatic, and peritoneal thickening with ascites (yellow arrow) compatible with peritoneal carcinomatosis.

in the risk for preterm delivery and intrauterine growth restriction has been reported.² Besides that, in many cases commencing antineoplastic therapy cannot be postponed until after delivery. Moreover, recently, there has been an increased use in targeted anti-cancer therapies, which adds new challenges to the selection of cancer treatment during pregnancy, since the safety of these agents in this context has not been established.² However, reports on the use of epidermal growth factor receptor tyrosine kinase inhibitor (EGFR-TKI) suggest that this treatment has not apparently been associated with consequences or major side effects on children.⁴⁻⁶ In relation to crizotinib neither previous reports nor any experimental animal model to assess teratogenicity are available. There was a recent work which assessed the extent of placental disposition of crizotinib, in which an *ex vivo* model was used and showed that the drug is strongly accumulated in placental tissue.⁷ Therefore, the report of additional clinical data on anti-neoplastic target therapy, such as crizotinib during gestation should be encouraged since the evidence for its use is scarce and limited to case reports.

Funding

The authors declare that no funding was received for this paper.

Conflicts of interest

The authors have no conflicts of interest to declare.

References

1. Pavlidis N. Lung cancer during pregnancy: an emerging issue. *Lung Cancer*. 2008;59:279-81.
2. Albright CM, Wenstrom KD. Malignancies in pregnancy. *Best Pract Res Clin Obstet Gynaecol*. 2016;33:2-18.
3. Azim HA Jr, Peccatori FA, Pavlidis N. Lung cancer in the pregnant woman: to treat or not to treat, that is the question. *Lung Cancer*. 2010;67:251-6.

4. Zambelli A, Prada GA, Fregoni V, Ponchio L, Sagrada P, Pavesi L. Erlotinib administration for advanced non-small cell lung cancer during the first 2 months of unrecognized pregnancy. *Lung Cancer*. 2008;60:455–7.
5. Rivas G, Llinas N, Bonilla C, Rubiano J, Cuello J, Arango N. Use of erlotinib throughout pregnancy: a case-report of a patient with metastatic lung adenocarcinoma. *Lung Cancer*. 2012;77:469–72.
6. Lee CH, Liam CK, Pang YK, Chua KT, Lim BK, Lai NL. Successful pregnancy with epidermal growth factor receptor tyrosine kinase inhibitor treatment of metastatic lung adenocarcinoma presenting with respiratory failure. *Lung Cancer*. 2011;74:349–51.
7. Eliesen GAM, van den Broek P, van den Heuvel JJ, Bilos A, Pertijs J, van Drongelen J, et al. Editor's highlight: placental disposition and effects of crizotinib: an ex vivo study in the isolated dual-side perfused human cotyledon. *Toxicol Sci*. 2017;157:500–9.

E. Padrão^{a,*}, C. Melo^b, G. Fernandes^{a,c}, A. Magalhães^a

^a *Pulmonology Department, Centro Hospitalar de São João, Porto, Portugal*

^b *Department of Obstetrics and Gynecology, Centro Hospitalar de São João, Porto, Portugal*

^c *Faculty of Medicine, University of Porto, Porto, Portugal*

*Corresponding author.

E-mail address: eva.padrao@gmail.com (E. Padrão).

<https://doi.org/10.1016/j.pulmoe.2018.03.007>
2531-0437/

© 2018 Sociedade Portuguesa de Pneumologia. Published by Elsevier España, S.L.U. This is an open access article under the CC BY-NC-ND license

(<http://creativecommons.org/licenses/by-nc-nd/4.0/>).

p-Hacking – A call for ethics



When the publication of scientific studies is influenced by the use and misuse of *p*-value¹ statistics two types of bias may occur – publication bias and inflation bias, also known as *p*-hacking.² The publication bias consists in considering only studies that present statistically significant results (i.e. $p < .05$). This bias removes from the literature studies whose results are considered negative, including false negatives. On the other hand, *p*-hacking consists in the exhaustive exploitation of data through the use of different analytical models and/or the manipulation of application criteria of these models until statistically significant results are obtained. While publication bias removes from the literature true or false negatives the *p*-hacking brings to the literature true or false positives. Conditioned literature (i.e. the absence of false negatives and the presence of false positives) will bias the results of secondary studies aiming to synthesise scientific evidence, such as meta-analyses, that inform clinical guidelines and evidence-based decision making.³

The demand for the statistically significant output (viz. $p < .05$) encourages researchers to do almost everything to achieve this result. There are a number of approaches^{4,5} (e.g. the exclusion of univariate and/or multivariate outliers, the selection of independent variables (IV) through stepwise hierarchical models, the strategic withdrawal of IV in multiple models, dichotomizing ordinal or continuous variables) and all are legitimate, from a strictly analytical point of view, to obtain results where *p*-value is $< .05$.⁶ The validity of the reported conclusions drawn by these methods is what is questionable, from a scientific point of view, given that there is a strong possibility of these results representing false positives, in other words, they may be mere statistical artefacts.³

The *p*-hacking bias is difficult to detect and it cannot be easily eradicated.³ Many researchers do not perceive it as a real problem, either because of lack of knowledge or because of the incentives and pressure to publish statistically significant results.

The magnitude of the bias for the use of *p*-hacking is not yet established, however, it is estimated to be quite

high.³ Seokyoung Hahn analysed the consistency between the analyses reported in the research protocol and the analyses reported in the study publication after completion from a local research ethics committee and found that only 53% mentioned an analysis plan and of these 88% did not comply with the protocol and could be the result of *p*-hacking practices.⁷

The pre-specification of the statistical analyses to be performed is one way of minimising the problem. Several studies follow an exploratory analytical approach which makes this pre-specification impossible. In addition, registration of health research protocols is not yet mandatory for all methodological designs. However, the evaluation by a health ethics committee of research protocols is already a widespread and successful practice in Portugal and across European Countries.⁸

It would be appropriate for the research protocols submitted to health ethics committees to describe in detail their analytical plan. That is, not merely stating the data that will be analysed with any particular software but rather the identification of: the analytical statistic(s) to be applied; the independent, dependent and concomitant variable(s) to be tested; the outlier definition and criteria; the post hoc tests that will be considered in the statistical modelling.

This pre-specification would make it possible to link the research statistical outputs to previous planning and prevent the negative effects of *p*-hacking. Additionally, it would be possible to develop more similar and replicable studies and to better assess the impact that *p*-hacking has on research. In the case of exploratory studies such detail is neither possible nor coherent.

Therefore, a call for health ethics committees to assess the manifestation of researchers' analytical intent in research protocols (i.e. pre-specified or exploratory) is pertinent to help prevent and further study the *p*-hacking bias.

Funding source

This research did not receive any specific grant from funding agencies in the public, commercial, or not-for-profit sectors.