

## Cervical mediastinoscopy: Safety profile, feasibility and diagnostic accuracy in a decade in a single center



### Work distribution by author

João Santos Silva contributed in elaboration of the idea and study design, data base creation, manuscript writing and revision. Ana Rita Costa contributed to the database creation and gathering data. Paulo Calvino contributed in elaboration of the idea, manuscript revision and supervision.

First described in 1959 by Carlens,<sup>1</sup> mediastinoscopy has been the gold standard in lung cancer staging and evaluation of mediastinal lymphadenopathies.<sup>2,3</sup>

Recently endobronchial (EBUS-FNA) and endoscopic (EUS-FNA) ultrasound guided biopsy with fine needle aspiration have been gaining popularity as an alternative.

The need to assess the quality of our department's performance motivated this paper; this is a report on our ten-year experience and aims to demonstrate the safety and diagnostic accuracy of mediastinoscopy and compare with the literature.

A retrospective study was performed after including all patients who underwent mediastinoscopy in our institution from January 2006 to November 2017 – 430 cases. 41 patients were excluded due to lack of records.

Videomediastinoscopy was introduced at our institution in early 2008. Before that period we report 41 mediastinoscopies performed by classic methods.

Patient characteristics are reported in Table 1 and yearly distribution in Fig. 1.

Indications were staging of lung cancer and evaluation of mediastinal lymphadenopathies or mass. Lymph nodes tissue was obtained from all patients except two cases of inaccessible mediastinum due to fibrosis. Staging mediastinoscopy was performed accessing routinely stations 4R, 7 and 4L, with two or more stations biopsied in 93.9% of cases. Diagnostic mediastinoscopy was performed as indicated by the suspected pathology.

Average hospital stay was 1.3 ( $\pm 1.9$ ) days, with 88% discharged on day 1 postoperative. No outpatient-based procedures are performed at our institution.

Complications occurred in 7 patients (1.8%) and 3 died (0.8%), as Table 2 describes.

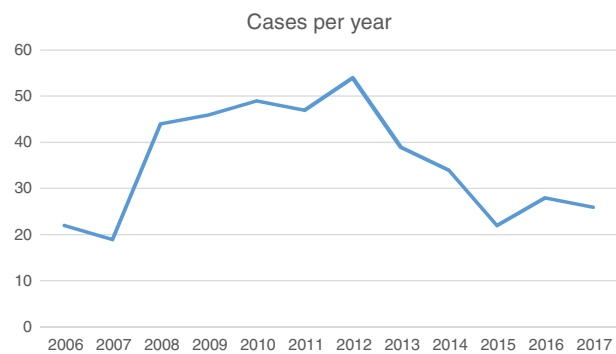


Figure 1

176 patients underwent diagnostic mediastinoscopy. Most common histopathological results were granulomatous disease (52%) and metastatic carcinoma (20%).

213 patients underwent mediastinoscopy for lung cancer staging. 41 had positive and 172 negative lymph nodes. 25 patients (11.7%) were excluded due to loss in follow-up, exploratory thoracotomy or neoadjuvant chemotherapy for local invasiveness. The remaining 147 patients underwent lung resection surgery with systematic lymph node dissection, on average, 22 days (1–68) after mediastinoscopy.

The overall incidence of false negative mediastinoscopy was 6.8% (10/147). Sensitivity of mediastinoscopy was 80.39% (95% CI, 66.88–90.18%) and negative predictive value was 93.20%. Accuracy was 94.68%.

Nowadays, the popularity of mediastinoscopy is declining due to the increase in EBUS and EUS-FNA. However, revised guidelines for preoperative mediastinal lymph node staging by European Society of Thoracic Surgeons state that EBUS/EUS-FNA is the first option in experienced centers due to its minimal invasiveness and its sensitivity to ruling out mediastinal disease but mediastinoscopy is indicated when negative in patients with suspected N2/N3 disease.<sup>4</sup>

Several studies confirm sensitivity up to 95% with EBUS to confirm mediastinal disease,<sup>5</sup> however other studies reveal false negative rates as high as 16%.<sup>3</sup> Regarding complications, rates as low as 0.15% in dedicated centers are reported but up to 1.23% in the community.<sup>6</sup>

However, the number of EBUS/EUS is expected to rise and the decrease we have witnessed in the number of mediastinoscopies performed in our center since its peak in 2012

Table 1

Characteristics	Patients (n)	(%)
Age (average, range)	60	(13–84)
Sex		
Male	313	72.8
Female	117	27.2
Previous chemotherapy, n (%)	41	9.5
Indications, n (%)		
Lung cancer staging	233	54.2
Mediastinal lymphadenopathy or mass	197	45.8

Table 2

Complications	Patients (n)	(%)
<b>Morbidity</b>		
Bleeding requiring sternotomy	4	1.0
Wound infection	0	0
Traqueal injury	1	0.25
Transient laryngeal nerve injury	4 <sup>a</sup>	15.4 <sup>a</sup>
Permanent laryngeal nerve injury	0	0
Unexpected readmissions	0	0
<b>Mortality</b>		
Postoperative	3	0.8
After discharge	0	0

<sup>a</sup>Due to lack of digital records, data referring only to year 2017.

may be due to this. Fewer mediastinoscopies may jeopardize the quality of training programs and safety rates may worsen.

In our country, EBUS is performed by pulmonologists, EUS by gastroenterologists and mediastinoscopies by thoracic surgeons and the decision to perform a mediastinoscopy may be biased by the accessibility to the preferred method by thoracic oncology teams. Surgical teams offer mediastinoscopy when there is no possibility of arranging an EBUS in time.

In our study we conclude that mediastinoscopy is safe with 1.8% complication rate and 0.8% mortality rate, comparable with larger series reporting complication rates of 1.3–3.7% and mortality rates of 0–0.6%.<sup>2,7</sup>

False negative rate was 6.8%, comparable with larger series results of 5.5–8.8%.<sup>2,7</sup> Sensitivity was 80.39%, comparable to rates of 85–89.8% in larger series.<sup>2,7</sup>

In terms of limitations, our study was retrospective. Secondly, comparison with pre-operative imaging like CT scan or PET/CT was beyond the scope of this article. Also, PET/CT was introduced in clinical practice at our institution in 2015, and only a small part of our cohort had previously had PET/CT scan. Thirdly, results were not compared to EBUS or EUS because it is done in a different institution and access to records is limited. Most centers in Portugal are performing EBUS alone and are not certified centers, and waiting times are variable. The choice of mediastinal invasive staging remains a matter of preference of oncology teams.

In conclusion, we believe mediastinoscopy will remain a tool of extreme value and an everyday practice in most thoracic surgery centers in our country which should be mastered by any dedicated thoracic surgeon. The results reported, comparable to other published series, prove mediastinoscopy to be safe and accurate.

International studies report similar rates with EBUS/EUS in mediastinal staging for lung cancer and we strongly encourage further studies comparing our results with other less invasive modalities. Furthermore, the role of EBUS/EUS in diagnosis of mediastinal adenopathies is even less studied.

## Conflicts of interest

The authors have no conflicts of interest to declare.

## References

1. Carlens E. Mediastinoscopy: a method for inspection and tissue biopsy in the superior mediastinum. *Dis Chest*. 1959;36:343–52.
2. Wei B, Bryant AS, Minnich DJ, Cerfolio RJ. The safety and efficacy of mediastinoscopy when performed by general thoracic surgeons. *Ann Thorac Surg*. 2014;97:1878–83, discussion 1883.
3. Cerfolio RJ, Bryant AS, Eloubeidi MA, Frederick PA, Minnich DJ, Harbour KC, et al. The true false negative rates of esophageal and endobronchial ultrasound in the staging of mediastinal lymph nodes in patients with non-small cell lung cancer. *Ann Thorac Surg*. 2010;90:427–34.
4. De Leyn P, Doooms C, Kuzdzal J, Lardinois D, Passlick B, Rami-Porta R, et al. Revised ESTS guidelines for preoperative mediastinal lymph node staging for non-small-cell lung cancer. *Eur J Cardiothorac Surg*. 2014;45:787–98.
5. Yasufuku K, Pierre A, Darling G, de Perrot M, Waddell T, Johnston M, et al. A prospective controlled trial of endobronchial ultrasound-guided transbronchial needle aspiration compared with mediastinoscopy for mediastinal lymph node staging of lung cancer. *J Thorac Cardiovasc Surg*. 2011;142:1393–4000.
6. Asano F, Aoe M, Ohsaki Y, Okada Y, Sasada S, Sato S, et al. Complications associated with endobronchial ultrasound-guided transbronchial needle aspiration: a nationwide survey by the Japan Society for Respiratory Endoscopy. *Respir Res*. 2013;14:50.
7. Lemaire A, Nikolic I, Petersen T, Haney JC, Toloza EM, Harpole DH Jr, et al. Nine-year single center experience with cervical mediastinoscopy: complications and false negative rate. *Ann Thorac Surg*. 2006;82:1185–9.

João Santos Silva\*, Ana Rita Costa, Paulo Calvinho

*Serviço de Cirurgia Cardiotorácica, Hospital de Santa Marta, Centro Hospitalar Lisboa Central, Rua de Santa Marta 50, 1169-024 Lisboa, Portugal*

\* Corresponding author.

*E-mail address:* joao.mss88@gmail.com (J. Santos Silva).

<https://doi.org/10.1016/j.pulmoe.2019.01.004>  
2531-0437/

© 2019 Sociedade Portuguesa de Pneumologia. Published by Elsevier España, S.L.U. This is an open access article under the CC BY-NC-ND license (<http://creativecommons.org/licenses/by-nc-nd/4.0/>).