



LETTERS TO THE EDITOR

Corticosteroid therapy for organizing pneumonia in a human T-cell lymphotropic virus type-1 carrier



Dear Editor,

Human T-cell lymphotropic virus type-1 (HTLV-1)-associated bronchioloalveolar disorder (HABA) is a unique chronic and progressive respiratory disorder occurring in patients with smouldering adult T-cell leukaemia or in HTLV-1 carriers.¹ The efficacy of corticosteroid for organizing pneumonia (OP) in an HTLV-1 carrier has not been definitively established.

We here report a case of OP in an HTLV-1 carrier that showed good response to corticosteroid treatment.

A 76-year-old man with a 10 pack-year smoking history presented to a hospital with a complaint of chest pain. During screening for infection, he was diagnosed as an HTLV-1 carrier. He had no other infections or respiratory diseases. Computed tomography (CT) revealed ground-glass opacity, consolidation, and pleural effusion in the thorax (bilaterally) (Fig. 1A, B). He was referred to our hospital for further examination.

He was taking oral medication such as aspirin, clopidogrel, alprazolam, L-carbocysteine, famotidine orally disintegrating (OD), naftopidil OD, magnesium oxide, olopatadine OD and levocetirizine hydrochloride. A bronchoscopy was performed for the ground-glass opacity in his right lung and was pathologically diagnosed with OP (Fig 1C). For the treatment of OP, we administered prednisolone at a dose of 60 mg daily; the ground-glass opacity and consolidation showed immediate improvement (Fig 1D). In 5 months, we tapered prednisolone from a dose of 60 mg daily to 0 mg.

In the present case, two important clinical observations were made. First, OP may occur in HTLV-1 carriers. To the best of our knowledge, there is only one case report of OP in an HTLV-1 carrier.² OP is induced mainly by drugs, tumours, systemic inflammatory diseases, and infections. The patient described here had no tumour or systemic inflammatory disease. Drug-induced OP is caused by several drugs such as methotrexate, gold compounds, penicillamine, bleomycin hydrochloride, amiodarone, salazosulapyridine, and nivolumab. However, he did not report using any of these; therefore, we diagnosed him as an HTLV-1 carrier with OP. Pathologically, HABA includes four types of pulmonary disorders: chronic bronchitis, chronic interstitial pneumonia, infiltration of leukemic or lymphoma cells, and lymphoproliferative disease.³ The proportions are as follows: chronic bronchitis (66%), chronic interstitial

pneumonia (16%), and others (18%). Among these, chronic interstitial pneumonia includes usual common interstitial pneumonia and chronic fibrosing interstitial pneumonia. In a study involving CT examination of HTLV-1 carriers, OP was reported (2/65, 3%),⁴ which may be one type of HABA.

Second, corticosteroid therapy may be efficacious for OP in HTLV-1 carriers. In the case reported, the patient was administered corticosteroid therapy.² OP is frequently treated with corticosteroids and has a good prognosis.⁵ Corticosteroid therapy might be efficacious for OP in HTLV-1 carriers.

The mechanism of onset of OP in HTLV-1 carriers is unknown. In HTLV-1 carriers, the percentages of CD3+ and CD3+CD25+ are significantly higher in the bronchoalveolar lavage fluid compared to the peripheral blood; therefore, the causative mechanism of HABA was suggested to involve HTLV-1 infection that may induce chronic inflammation in the lung through immunologic mechanisms.⁶ The mechanism of onset of OP in HTLV-1 carriers might also be related to HTLV-1 infection inducing chronic inflammation through immunological mechanisms.

Patients with HTLV-1 are found in specific areas of the world. However, recently, migration of people between countries has become more frequent. Therefore, the incidence of HTLV-1 infection might increase in other areas in future.

In conclusion, OP may occur in HTLV-1 carriers and corticosteroid therapy may be efficacious for OP in HTLV-1 carriers.

Statement of ethics

The authors have no ethical conflicts to disclose. Informed consent was obtained from the patient.

Funding

This research did not receive any specific grant from funding agencies in the public, commercial, or not-for-profit sectors.

Author contributions

- Masaya Taniwaki wrote the paper.
- Yu Matsumoto, Naoko Matsumoto, and Nobuyuki Ohashi contributed to data collection.
- Masahiro Yamasaki and Noboru Hattori approved the version of the manuscript to be published.

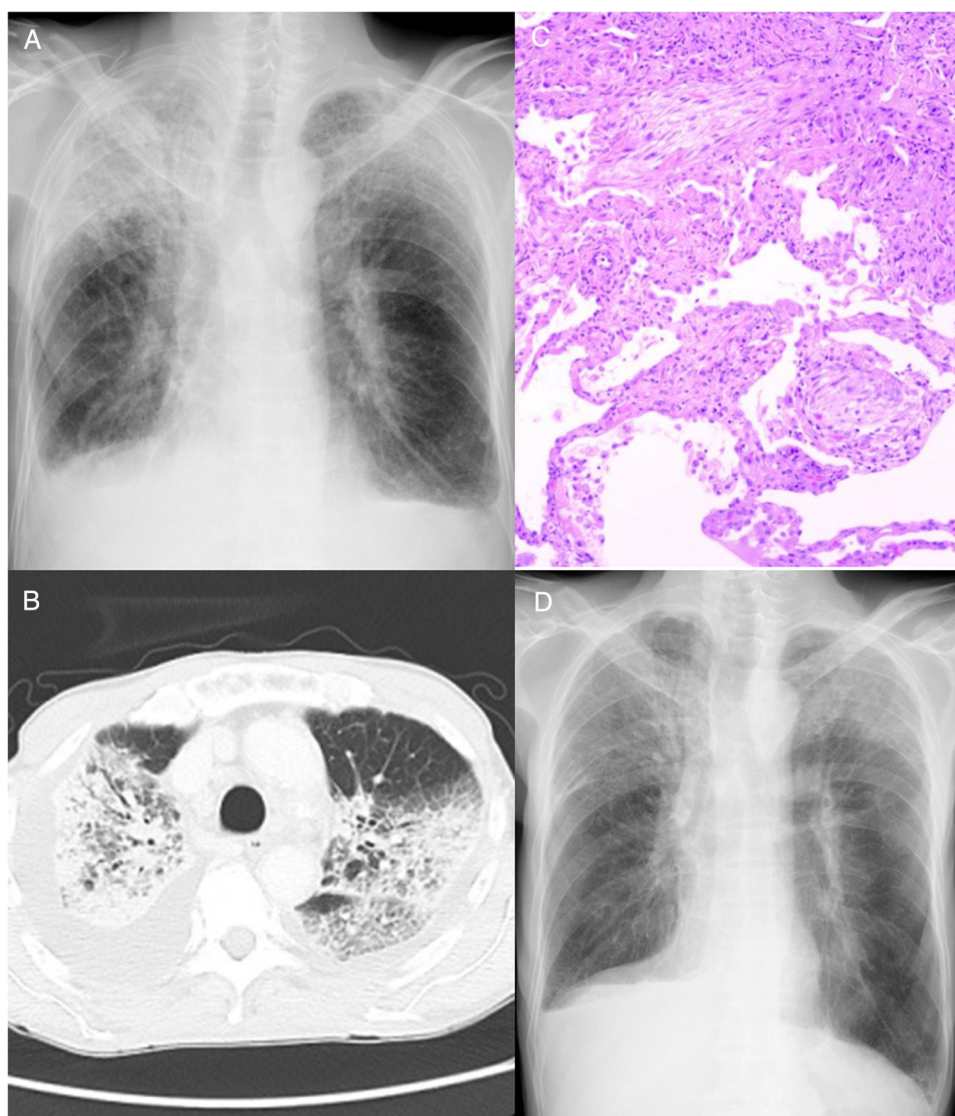


Figure 1 (A) Chest radiography and (B) computed tomography examination showed ground-glass opacity and consolidation in bilateral lung fields, as well as bilateral pleural effusion. (C) Haematoxylin and eosin staining of the lung biopsy specimen. Round-shaped fibroblasts (Masson bodies) were observed in the alveolar space; therefore, a pathological diagnosis of organizing pneumonia was made. (D) After two weeks of corticosteroid administration, chest radiography revealed improvement of ground-glass opacity and bilateral consolidation of the lungs.

Conflict of interest

None.

Acknowledgements

We thank Editage for English language editing.

References

1. Kimura I. [HABA (HTLV-I associated bronchiolo-alveolar disorder)]. *Nihon Kyobu Shikkan Gakkai Zasshi*. 1992;30:787–95.
2. Matsuo K, Tada S, Kataoka M, Kanehiro A, Kaneko S, Miyake T, et al. Bronchiolitis obliterans organizing pneumonia (BOOP) in a case of smouldering adult T-cell leukaemia. *Respirology*. 2000;5:81–5.
3. Yokohori N, Sato A, Hasegawa M, Katsura H, Hiroshima K, Takemura T. Effectiveness of combined therapy with pirfenidone and erythromycin for unclassifiable interstitial pneumonia induced by HTLV-1-associated bronchioloalveolar disorder (HABA). *Intern Med*. 2017;56:73–8.
4. Yamashiro T, Kamiya H, Miyara T, Gibo S, Ogawa K, Akamine T, et al. CT scans of the chest in carriers of human T-cell lymphotropic virus type 1: presence of interstitial pneumonia. *Acad Radiol*. 2012;19:952–7.
5. Baque-Juston M, Pellegrin A, Leroy S, Marquette CH, Padovani B. Organizing pneumonia: what is it? A conceptual approach and pictorial review. *Diagn Interv Imaging*. 2014;95:771–7.
6. Yamakawa H, Yoshida M, Yabe M, Ishikawa T, Takagi M, Tanoue S, et al. Human T-cell lymphotropic virus type-1 (HTLV-1)-associated bronchioloalveolar disorder presenting with mosaic perfusion. *Intern Med*. 2015;54:3039–43.

M. Taniwaki^{a,*}, M. Yamasaki^a, Y. Matsumoto^a,
N. Matsumoto^a, N. Ohashi^{a,b}, N. Hattori^c

^a Department of Respiratory Disease, Hiroshima Red Cross Hospital & Atomic-bomb Survivors Hospital, Naka-ku, Hiroshima, Japan

^b Ohashi Clinic, Naka-ku, Hiroshima, Japan

^c Department of Molecular and Internal Medicine, Institute of Biomedical & Health Sciences, Hiroshima University, Minami-ku, Hiroshima, Japan

*Corresponding author.

E-mail address: graymzo@yahoo.co.jp (M. Taniwaki).

Available online 15 April 2019

<https://doi.org/10.1016/j.pulmoe.2019.02.004>
2531-0437/

© 2019 Sociedade Portuguesa de Pneumologia. Published by Elsevier España, S.L.U. This is an open access article under the CC BY-NC-ND license (<http://creativecommons.org/licenses/by-nc-nd/4.0/>).

Chylothorax as a debut form of Gorham-Stout disease



Case report

Gorham-Stout disease is an extremely rare disease of unknown etiology. It is characterized by the local proliferation and dilation of lymphatic vessels, which causes spontaneous progressive osteolysis with bone resorption. It may affect one or several – usually contiguous – bones, generally the hips, the scapular waist, the vertebrae, the ribs and the skull. It mainly affects children and young adults, with no gender-based differences. Diagnosis is based on clinical, analytical, radiological and histopathological findings. Chylothorax may occur as a result of the involvement of the

lymphatic vessels of the pleura or thoracic duct by adjacent osteolysis.¹

A 37 year-old man presented with a 14-day history of progressive dyspnea that occurred even with minimal effort. The patient had normal vital signs, hypoxemia, and a generalized reduction of respiratory sounds in the left hemithorax. Blood analysis was normal. Chest X-ray showed a massive left pleural effusion without displacement of the midline (Fig. 1A). The radiological findings of CT scan and MRI are shown in Fig 1B–F.

The milky pleural fluid was a lymphocyte-predominant exudate (93% of lymphocytes); its biochemistry was compatible with chylothorax (1452 mg/dL of triglycerides). Malignancy was excluded after several negative pleural biopsies. Talc pleurodesis was performed. Microscopic findings on iliac bone biopsy are shown in Fig. 2. Sirolimus

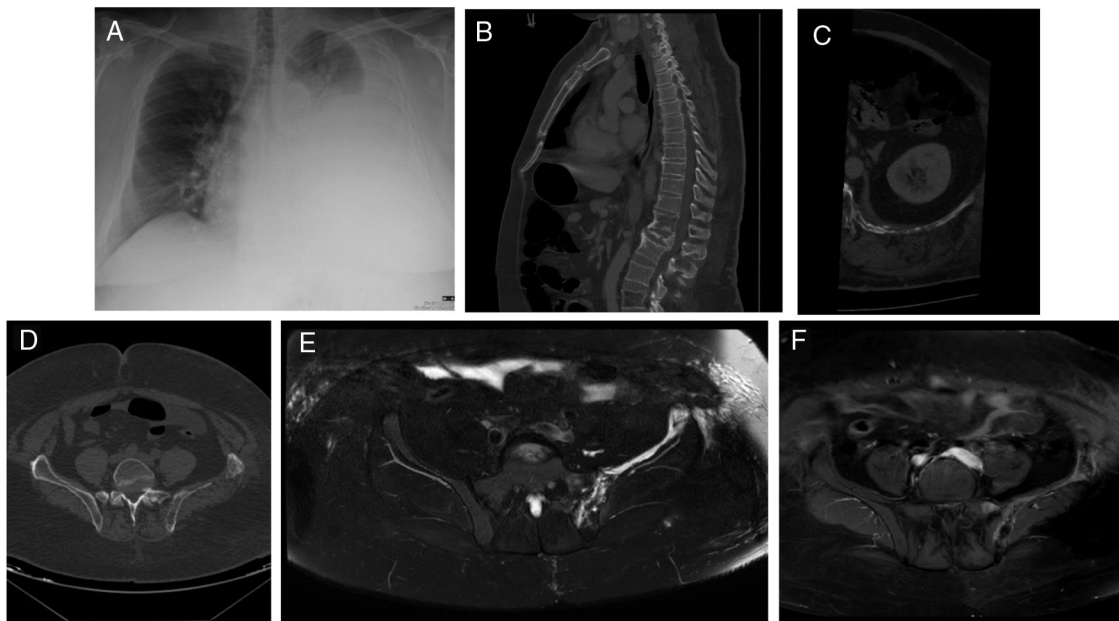


Figure 1 (A) Chest X-ray PA showed a radiodensity practically diffuse of the left hemitorax in relation to severe pleural effusion. (B) The sagittal reformatted CT image demonstrated a diffuse fat infiltration with loss of the trabecular bone pattern in the vertebral bodies T12 and L4 and an infiltration of the deep subcutaneous cellular tissue in the posterior abdominal wall. (C) The axial reformatted CT image showed multiple fatty lytic bone lesions with cortical disruptions in the 12th left rib. (D) Axial CT image demonstrated incomplete osteolysis of the left iliac bone with multiple fatty lytic bone lesions with cortical disruptions and without an increase of soft tissues. (E) Axial TSE-T2 weighted fat-suppressed image showed a diffuse hyperintensity of the left iliac bone, where linear structures are recognized that correspond to the dilatation of the lymphatic vessels. (F) This lesion presented an intense diffuse enhancement after administration of IV contrast on an axial TSE-T1 weighted fat-suppressed image.