



LETTERS TO THE EDITOR

Tarlov cyst: A rare cause of posterior mediastinal mass



To the Editor,

A 68-year-old woman was admitted to hospital with a history of dry cough and mild back pain with chronic evolution. She did not have fever, weight loss, chills or any other symptom, and had a history of smoking one pack per day for 25 years (25 pack-years). Chest radiography demonstrated a posterior mediastinal mass (Fig. 1A), which led her to consult a pulmonologist. Chest computed tomography showed a round hypodense lesion with fluid attenuation, smooth margins, and nocontrast enhancement, originating in the right D2–D3 intervertebral foramen (Fig. 1B). Magnetic resonance imaging (MRI) of the thoracic spine showed a purely cystic non-enhancing lesion originating in the D2–D3 intervertebral foramen, and closely related to the emergent nerve root sheaths (Fig. 1C and D). The cyst was explored surgically and resected through left laminectomy and foraminectomy. Histological examination revealed that it was a perineural cyst. The surgical treatment was curative. After 1 year, the patient remains asymptomatic.

The spinal perineural cyst, also known as the Tarlov cyst (TC), is a rare anomaly of the nervous system and a subtype of meningeal cyst. A TC is defined as a cystic dilatation

between the perineurium and endoneurium of the spinal nerve roots, located at the level of the spinal ganglion and filled with cerebrospinal fluid (CSF). Histologically, TCs are characterized by the presence of nerve fibers in the fibrous tissue of their walls.^{1–4}

The origin of these lesions is controversial and unclear. Theories proposed for TC formation include inflammation in the subarachnoid space, traumatic hemorrhage that leads to the blockage of venous drainage of the perineurium and epineurium, congenital diverticula from persistent embryonic fissures, and hydrostatic CSF pressure.^{1–3} It has been suggested that restricted communication with CSF in the thecal sac may result in a ball-valve mechanism that permits one-way entry of CSF into the cyst during systolic pulsations, with no exit during diastole.²

TCs are found predominantly at the lumbosacral level of the spine; they may occur at all spinal levels, but they are rarely seen in the thoracic spine.^{1–4} Meningeal cysts are classified according to location relative to the dural and arachnoid space, and to cyst wall pathology. Type I cysts are extradural. Type II cysts are perineural TCs or spinal nerve root diverticula, and their cyst walls can contain nerve fibers. Type III cysts are intradural.³

Most TCs are asymptomatic and clinically insignificant.^{2–4} Symptoms of perineural cysts depend on their localization and size. Large cysts can compress and damage nerve roots,

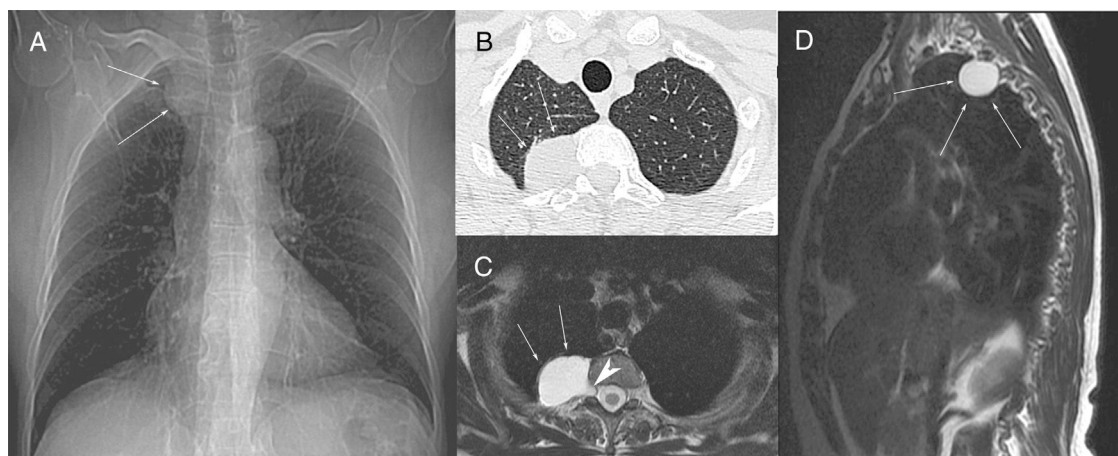


Figure 1 Scout view of a computed tomography (A) showing a right paravertebral mass (arrows) at the D2–D3 level. Axial chest computed tomography (B) demonstrating an oval mass (arrows) originating in the posterior mediastinum, at the level of the right D2–D3 intervertebral foramen. T2-weighted axial (C) and sagittal (D) magnetic resonance images showing a hyperintense round lesion (arrows), with signal intensity similar to fluid, originating in the extradural space at the level of the right D2–D3 intervertebral foramen (arrowhead).

the spinal cord, and/or surrounding bone.² They can be present as single or multiple lesions at various levels, and their incidence is higher in females than in males.^{2,4}

Computed tomography myelography and MRI are useful imaging tools for the diagnosis of TC. On computed tomography myelography, the absence of early contrast enhancement is a characteristic finding. MRI typically demonstrates signal intensity characteristics consistent with CSF-containing cysts. However, the final diagnosis is made histopathologically, often during surgery.^{1,3}

No standard treatment for TC has been established. Controversy surrounds the treatment of symptomatic lesions, with a broad range of options from conservative medical management to percutaneous cyst aspiration to open cyst fenestration or excision. When a patient has neurological deficits caused by spinal cord compression by a growing tumor, surgery is mandatory.¹⁻³

The literature contains very few case reports describing thoracic TCs.^{1,2,5} The main entities considered in differential diagnosis are other cystic nerve root sheath tumors. The presence of a solid component and contrast enhancement of the cyst suggest cystic schwannoma and cystic neurofibroma as important considerations in differential diagnosis.⁶

Conflicts of interest

The authors declare that they have no conflicts of interest to express.

References

1. Kleib AS, Saliyh SM, Hamdi H, Carron R, Soumaré O. A rare cause of thoracic spinal cord compression by multiple large Tarlov cysts. *Korean J Neurotrauma*. 2018;14:35–8.
2. Aljuboori Z, Yaseen A, Simpson J, Boakye M. Surgical excision of a symptomatic thoracic nerve root perineural cyst resulting in complete resolution of symptoms: a case report. *Cureus*. 2017;9:e1343.
3. McEvoy SD, DiLuna ML, Baird AH, Duncan CC. Symptomatic thoracic Tarlov perineural cyst. *Pediatr Neurosurg*. 2009;45:321–3.
4. Burdan F, Mocarska A, Janczarek M, Klepacz R, Łosicki M, Patyra K, et al. Incidence of spinal perineural (Tarlov) cysts among East-European patients. *PLOS ONE*. 2013;8:e71514.
5. Iwamuro H, Yanagawa T, Takamizawa S, Taniguchi M. Atypical findings of perineural cysts on postmyelographic computed tomography: a case report of intermittent intercostal neuralgia caused by thoracic perineural cysts. *BMC Med Imaging*. 2017;17:37.
6. Boukobza M, Roussel A, Fernandez-Rodriguez P, Laissy JP. Giant multiple and bilateral presacral Tarlov cysts mimicking adnexal mass-imaging features. *Int Med Case Rep J*. 2018;11:181–4.

G.F. Louza^a, I.C.F. Louza^b, G. Zanetti^a, E. Marchiori^{a,*}

^a Departamento de Radiologia da Faculdade de Medicina da Universidade Federal do Rio de Janeiro, Rio de Janeiro, Brazil

^b Setor de Radiologia, Hospital Professor Edmundo Vasconcelos, São Paulo, Brazil

*Corresponding author.

E-mail address: edmarchiori@gmail.com (E. Marchiori).

Available online 15 April 2019

<https://doi.org/10.1016/j.pulmoe.2019.03.001>
2531-0437/

© 2019 Sociedade Portuguesa de Pneumologia. Published by Elsevier España, S.L.U. This is an open access article under the CC BY-NC-ND license (<http://creativecommons.org/licenses/by-nc-nd/4.0/>).

Is probable usual interstitial pneumonia pattern synonymous with idiopathic pulmonary fibrosis?



In November 2017, Fleischner Society published a White Paper proposing four new diagnostic categories of UIP based on HRCT patterns.¹ These HRCT patterns have been incorporated into the most recent clinical guidelines about diagnosis of IPF.²

The Fleischner Society White Paper also proposed that a typical or probable UIP pattern in HRCT provides a diagnosis of IPF in the appropriate clinical context and, in these cases, lung biopsy is not necessary.¹ However, the 2018 guidelines about IPF diagnosis suggest surgical lung biopsy for patients who are clinically suspected of having IPF and have an HRCT pattern of probable UIP.² Neither of the papers recommends transbronchial lung cryobiopsy (TBLC) for histological characterization.^{1,2}

The aim of this study was to evaluate the histological and multidisciplinary diagnosis in patients with probable UIP pattern who underwent TBLC.

We reviewed HRCT of all patients who underwent TBLC between July 2014 and August 2017 at the Bronchoscopy Unit of the Pulmonology Department of Vila Nova de Gaia-Espinho Hospital Center. From a pool of 130 TBLC patients we only included those with probable UIP pattern, according to the Fleischner Society White Paper. Medical records, clinical and demographic data, histological and multidisciplinary diagnosis were retrospectively reviewed.

As a result we included 34 patients with probable UIP pattern, mostly male ($n=25$; 73.5%), with a mean age of 67.7 ± 7.1 years old. Demographic data, smoking habits, pulmonary function tests, environmental exposures and autoantibodies profile are described in [Table 1](#).

A bronchoalveolar lavage (BAL) was performed on all patients and, from the 26 patients with history of environmental exposures, only 7 had lymphocytosis $\geq 30\%$ on cellular analysis of BAL fluid.

The histological and multidisciplinary diagnosis was described in [Table 2](#).

Surgical lung biopsy was performed on 3 patients who had an inconclusive histological diagnosis. After surgical lung