



LETTERS TO THE EDITOR

Accidental breakage of a transbronchial puncture needle during an endobronchial ultrasound bronchoscopy



Endobronchial ultrasound-guided transbronchial needle aspiration (EBUS-TBNA) is a very useful tool for the diagnosis and staging of lung cancer.¹ This technique is also used for diagnosis of other mediastinal diseases that can be accessed through the airways. The use of EBUS has become widespread in recent years, as it is well tolerated, safe, cost-effective and less invasive than mediastinoscopy and core-needle biopsy. Like all diagnostic tests, EBUS is associated with some complications, the most frequent being puncture site bleeding, pneumothorax and respiratory failure.² We present a rare case of transbronchial puncture needle breakage during EBUS.

We report the case of a 63 year-old man with a mixed subsolid pulmonary 19-mm nodule (solid component with a ground-glass nodule) in the right lower lobe of the lung and mediastinal adenopathies of significant size [left paratracheal (4L): 13 mm; right hilar (11R): 12 mm; and subcarinal (7): 16 mm]. During follow-up, all adenopathies remained stable, except for the subcarinal one, which experienced a 5-mm growth (from 11 to 16 mm). Positron emission tomography did not show significant enhancement in any of the lesions (SUVmax 3.81). Due to the significant growth of the subcarinal adenopathy, we decided to perform an EBUS under sedation. The procedure was performed using BF-UC180F instrument and a 21G needle (NA-201SX-4021 model). We first punctured the adenopathies located at 7, 4L and 11R level. During the last puncture, real-time ultrasound showed that the distal portion of the needle was placed in the medial wall of the intermediary bronchus and remained motionless despite the proximal portion being extracted. Needle breakage was confirmed on chest X-ray (Fig. 1A) and bronchofibroscopy (Fig. 1B) (which was also used to extract the needle (Fig. 1C)). Histological analysis showed no malignancies. Removal of the pulmonary nodule was high-risk, as the patient had a dilated cardiomyopathy with EF 29%. Therefore, we decided to adopt a watchful waiting strategy.

EBUS is a safe technique, with a global rate of complications of 1.4%.² Within the first 24 h, the most common complications include respiratory failure, bleeding, or pneumothorax. Thereafter, complications generally are infectious (mediastinitis, sepsis or abscesses). Other potential complications include failure of the working channel or the transbronchial puncture needle.³

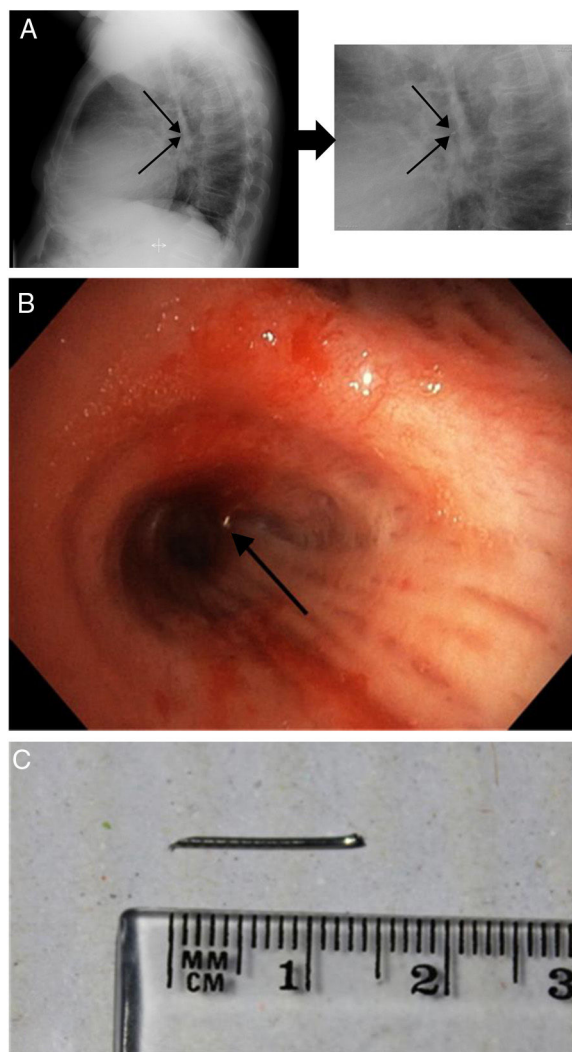


Figure 1 (A) Chest X-ray showing the presence of the distal end of the broken needle (black arrows). (B) Broken needle placed in the medial wall of the intermediary bronchus. (C) Distal 1.5 cm portion of the needle after extraction by bronchofibroscopy.

The breakage of the needle during EBUS is a rare complication, as only 15 cases were reported in a recent review of a series of 7345 EBUS procedures (0.2%).⁴ In the first case described,⁵ the needle broke during the third pass. The needle can be retained inside the adenopathy,⁶ migrate to a more distal area of the lung or even to another organ.⁵

Although it can be expelled spontaneously,⁷ an invasive method may be required when the needle cannot be reached by bronchoscopy. Otherwise, the needle may perforate or migrate to the vascular system or cause chronic inflammation as a response to a foreign object. Only in 7 of the 22 cases reported did the needle break after the adenopathy was punctured [locations 7 (3 patients), 4L (2), 4R (1) and 10R (1)]. The potential causes of needle breakage include⁷: (1) tangential position of the needle due to the angle required for puncture; (2) harder than usual cartilaginous rings or lymph nodes; (3) manufacturing defects of the needle. To prevent this complication, excessive angulation of the needle should be avoided and its structural integrity should be checked prior to each puncture. The needle can also break and remain retained within the sheath.⁸ In this case, when the sheath is extracted from the working channel and the stiffening wire is inserted, the broken distal end of the needle will be expelled. Needles generally break prior to the procedure.

The lesson learned from this experience is that, although EBUS is a safe technique, complications – such as transbronchial puncture needle breakage – may arise. The structural integrity of the needles should be checked throughout the procedure and upon completion. The needle must be extracted. If it cannot be recovered by conventional bronchofibroscopy, an invasive method will be required.

Abbreviations

EBUS	endobronchial ultrasound
EBUS-TBNA	endobronchial ultrasound with real-time guided transbronchial needle aspiration

Authors' contributions

VR, AG and LV were responsible for the conception and design of the study, and wrote and edited the manuscript. AC contributed to the drafting and revision of the manuscript. All authors read and approved the final manuscript.

Funding

This study was undertaken without funding.

Conflicts of interest

The author has no conflicts of interest to declare.

References

1. Detterbeck FC, Boffa DJ, Kim AW, Tanoue LT. The Eighth Edition Lung Cancer Stage Classification. *Chest*. 2017;151:193–203.
2. Eapen GA, Shah AM, Lei X, Jimenez CA, Morice RC, Yarmus L, et al. Complications, consequences, and practice patterns of endobronchial ultrasound-guided transbronchial needle aspiration. Results of the AQUIRE registry. *Chest*. 2013;143:1044–53.
3. Vaidya PJ, Munavvar M, Leuppi JD, Mehta AC, Chhajed PN. Endobronchial ultrasound-guided transbronchial needle aspiration: safe as it sounds. *Respirology*. 2017;22:1093–101.
4. Asano F, Aoe M, Ohsaki Y, Okada Y, Sasada S, Sato S, et al. Complications associated with endobronchial ultrasound-guided transbronchial needle aspiration: a nationwide survey by the Japan Society for Respiratory Endoscopy. *Respir. Res.* 2013;14:50.
5. Özgüll MA, Çetinkaya E, Tutar N, Özgüll G. An unusual complication of endobronchial ultrasound-guided transbronchial needle aspiration (EBUS-TBNA): the needle breakage. *Ann. Thorac. Cardiovasc. Surg.* 2014;20:567–9.
6. Vial MR, ÓConnell JO, Grosu HB, Ost DE, Eapen GA, Jimenez CA. Needle fracture during endobronchial ultrasound-guided transbronchial needle aspiration. *Am. J. Respir. Crit. Care Med.* 2016;193:213–4.
7. Hanna A, Crutu A, Baldeyrou P. Needle tip fracture, an unusual EBUS-TBNA complication. *J Bronchol Intervent Pulmonol.* 2018;25:23–4.
8. Dhillon SS, Yendamuri S. Needle assembly malfunction. An unusual complication related to endobronchial ultrasound-guided transbronchial needle aspiration. *J Bronchol Intervent Pulmonol.* 2013;20:252–5.

V. Riveiro^{a,*}, A. Golpe^a, A. Casal^a, L. Valdés^{a,b}

^a *Pneumology Department, Hospital Clínico-Universitario, Santiago de Compostela, Spain*

^b *Interdisciplinary Pneumology Research Group, Santiago de Compostela Health Research Institutions (Instituto de Investigaciones Sanitarias de Santiago de Compostela/IDIS), Santiago de Compostela, Spain*

* Corresponding author.

E-mail address: vanessa.riveiro.blanco@sergas.es (V. Riveiro).

Available online 7 May 2019

<https://doi.org/10.1016/j.pulmoe.2019.04.001>
2531-0437/

© 2019 Sociedade Portuguesa de Pneumologia. Published by Elsevier España, S.L.U. This is an open access article under the CC BY-NC-ND license (<http://creativecommons.org/licenses/by-nc-nd/4.0/>).

Treatment of advanced EGFR-mutant NSCLC patients: Sequencing matters



Dear Editor,

The availability of several treatment options in epidermal growth factor receptor mutation-positive (EGFR M+)

non-small cell lung cancer (NSCLC), poses a challenge for clinicians as to what to consider when choosing the best treatment sequence?

First, a fast and comprehensive mutation screening is required to define subpopulations benefiting from target therapies, which should include, at present time, at least EGFR, ALK, ROS1 and BRAF genes.¹