

## Cystic tuberculosis: a very unusual aspect of a common disease



### Introduction

Increase in cases of tuberculosis have been reported in recent years in several countries, particularly in urban centers and regions with high prevalence of HIV infection.<sup>1</sup> With this worldwide resurgence of *M. tuberculosis* infection, the recognition of complications and sequelae is very important. Patients with pulmonary tuberculosis present a wide range of CT findings, including airspace or interstitial nodules, the tree-in-bud pattern, consolidations, cavitation, fibrosis, bronchial wall thickening, lymph node enlargement, and pleural effusion.<sup>2</sup> However, cystic changes associated with pulmonary tuberculosis have rarely been reported, and are among the rarest presentations of this common disease.<sup>3-8</sup>

The aim of this report was to describe a case of cystic tuberculosis and to perform a review of the previous reports of this uncommon finding. The MEDLINE database was searched for articles that were published between January 1994 and October 2019. All searches were performed using medical subject heading (MeSH) or free text word. We combined search terms for the primary disease (tuberculosis), the diagnostic test (computed tomography) and pattern (cystic disease). We also manually searched the reference lists of the eligible studies.

### Case report

A 28-year-old homeless woman, a drug-user was admitted to the Emergency Department in an inebriated state under the influence of alcohol. On physical examination, she was found to be disoriented and to have a persistent cough. Her laboratory test results were unremarkable. Chest computed tomography (CT) showed bizarre, irregular cystic formations in the upper regions of the lungs associated with ill-defined centrilobular nodules (Fig. 1). Based on this tomographic pattern, the initial diagnostic suspicion was Langerhans cell histiocytosis.

After clinical improvement, when the patient was lucid and oriented, she reported that she had been admitted to a hospital in a nearby city and diagnosed with pulmonary tuberculosis 9 months previously. We contacted the hospital and obtained the following information: the patient presented with complaints of fever for 2 months, productive cough, shortness of breath, asthenia, and 12 kg weight loss. The patient's sputum was positive for acid-fast bacilli, and a culture was positive for *Mycobacterium tuberculosis*. A human immunodeficiency virus (HIV) test also yielded positive findings. The patient was treated with antituberculous drugs for 6 months. A CT examination performed at that time (9 months before the current examination) showed diffuse multiple small nodules, some of which were cavitated, in the upper lobes (Fig. 2). Thus, the final diagnosis was pulmonary tuberculosis evolving into cystic formations.

### Discussion

Our patient initially presented with disseminated tuberculosis, which evolved to cystic lesions, predominantly in the upper lung zones. Cystic lesions may develop before or during antituberculous treatment in patients with pulmonary tuberculosis.<sup>5</sup> Tuberculosis cysts may evolve with varied outcomes and severity during the course of the disease.<sup>4</sup> In some cases, the cysts are reversible and disappear almost completely after antituberculous therapy; in others, the cysts persist after treatment.<sup>3,4,6</sup> The rupture of these cystic lesions may cause pneumothorax<sup>7</sup> or pneumomediastinum.<sup>6</sup>

Several mechanisms have been suggested for the pathogenesis of cystic lung lesions due to tuberculosis: a) a check-valve mechanism due to the granulomatous involvement of bronchioles and the excavation of caseous necrotic material by bronchial drainage;<sup>3,4-7</sup> b) the communication of tuberculous lesions containing caseous necrosis with the bronchi, resulting in the excavation of necrotic material and cystic changes;<sup>7</sup> and c) the cystic lesions representation of areas of dilated bronchioles. Immunohistochemical studies and electron microscopic examinations have revealed that the proteinases secreted from the inflammatory cells of peribronchiolar granulomas are partly responsible for the degradation of elastic fibers along the bronchioles, alveolar ducts, and alveolar walls.<sup>5,7</sup>

On CT, these cysts appear predominantly in the upper and middle lung zones. The cystic lesions are associated with centrilobular nodules and branching opacities in surrounding areas.<sup>2,7</sup> The lesions are irregular in shape, increase in size, and have a tendency to coalesce. The upper zone predominance may be related to the fact that tuberculous lesions are more common in this region.<sup>6</sup>

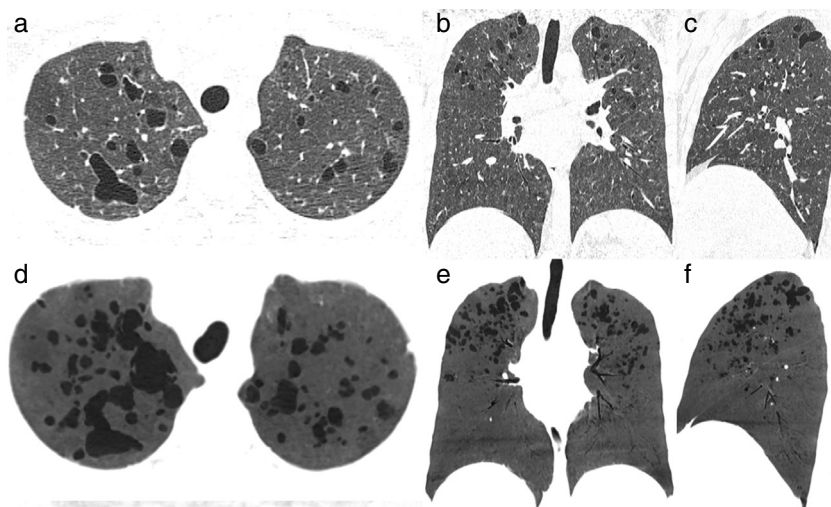
Pulmonary tuberculosis with multiple cysts should be differentiated from various cystic lung diseases, particularly Langerhans cell histiocytosis, lymphangioliomyomatosis, lymphocytic interstitial pneumonia, and *Pneumocystis jiroveci* pneumonia,<sup>2,6</sup> and from diseases that mimic cysts, such as bullous emphysema and pneumatoceles.<sup>4</sup> In the proper clinical context, cystic changes in pulmonary tuberculosis can be easily diagnosed.<sup>3</sup> In our patient, the main differential diagnosis was Langerhans cell histiocytosis, particularly because of the upper lobe predominance of the cysts. In summary, pulmonary tuberculosis may on rare occasions present as cystic lung disease and should be recognized as a possible cause of acquired cystic lung disease in appropriate clinical settings (Table 1).

### Authors' contributions

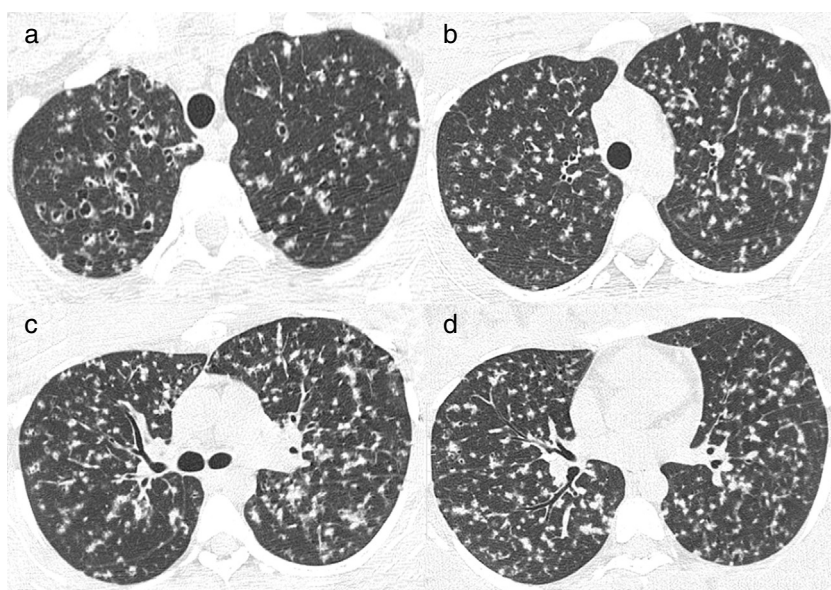
JP, ESP, EM were responsible for the conception and design of the study, and wrote and edited the manuscript. EM contributed to the drafting and revision of the manuscript. All authors read and approved the final manuscript.

**Table 1** Cases of cystic tuberculosis previously described in the literature.

Author and year of publication	Study design	Main findings
Ko et al. <sup>6</sup>	Case Reports	<p>Case 1. Female, 26 y.o, HIV (-) Fever, cough, dyspnea Sputum, BAL and culture (+) CT: micronodules; consolidations; ground-glass; cavitation Control CT (8 months): nearly complete disappearance of cystic lesions; areas of irregular lines.</p> <p>Case 2. Female, 27 y.o, HIV (-) Fever, cough, dyspnea, loss of weight Sputum and biopsy (+) CT: cysts in upper lobes; consolidations Control CT (8 months): nearly complete disappearance of cystic lesions; irregular lines and centrilobular lesions in the right lung.</p> <p>Case 3. Female, 52 y.o, HIV (-) Fever, cough, dyspnea Sputum, BAL and culture (+) CT: micronodules; diffuse ground glass Control CT (6 months): nearly complete disappearance of cysts. remaining micronodules and irregular lines.</p>
Takemura et al. <sup>7</sup>	Case Report	<p>Female, 30 y.o, immunocompromised - HIV (-) Fever, cough, loss of weight - Pneumothorax BAL and culture (+) CT: small cysts in upper lobes Patient died after 5 months</p>
Lee et al. <sup>5</sup>	Case Report	<p>Male, 24 y.o, HIV (-) Fever, cough, dyspnea - Pneumothorax Sputum and culture (+) CT: centrilobular nodules; tree-in-bud pattern; consolidations, Cavitation on the left lung CT control (4 months): cysts larger than previous TC.</p>
Cai et al. <sup>2</sup>	Case Report	<p>Male, 64 y.o, HIV (-) Fever and cough Sputum (-) - BAL and biopsy (+) CT: cysts and bilateral ground glass</p>
Ko et al. <sup>3</sup>	Case Report	<p>Male, 48 y.o, HIV (-) Fever, cough, dyspnea Sputum, BAL and culture (+) CT: micronodules; diffuse ground glass CT control (6 months): reduction of the cystic lesions; fibrosis in the upper lobes</p>
Ray et al. <sup>4</sup>	Case Report	<p>Female, 13 y.o, HIV (-) Fever, dyspnea, loss of weight BAL and culture (+) CT: centrilobular nodules; multiple cysts and diffuse ground glass. CT control (6 months): reduction of the cysts, nodules and opacities.</p>
Periwal et al. <sup>8</sup>	Case Report	<p>Female, 14 y.o, HIV (-) Fever, loss of weight - pneumothorax BAL and culture (+) CT: cysts and bilateral ground-glass.</p>



**Fig. 1** Axial (A), coronal (B), and sagittal (C) reformatted CT images showing multiple thin-walled cysts and ill-defined centrilobular nodules, mainly in the upper lung zones. The cysts have bizarre shapes and a branching appearance. (D-F) Minimum intensity projection reformatted images in the same planes as A-C better demonstrate the thin-walled bizarre cysts.



**Fig. 2** Axial CT images obtained 9 months before those presented in Fig. 1 show diffuse multiple small nodules, some of which are cavitated, in the upper lobes.

### Conflicts of interest

The author has no conflicts of interest to declare.

On behalf of all authors, the corresponding author states that there is no conflict of interest.

### Funding

This study was undertaken without funding.

### References

- [1].Belknap RW. Current medical management of pulmonary tuberculosis. *Thorac Surg Clin.* 2019;29:27–35.
- [2].Cai HR, Cao M, Meng FQ, Li WC. Cystic changes associated with pulmonary tuberculosis: a case report. *Chin Med J (Engl).* 2006;119:1125–8.
- [3].Ko SM, Seo SJ, Choi WI, Jeon YJ. Cystic change in pulmonary tuberculosis in an immunocompetent adult: a case report. *J Korean Radiol Soc.* 2008;58:261–4.
- [4].Ray A, Suri JC, Sen MK, Khanna A. Cystic lung disease in tuberculosis: an unusual presentation. *Lung India.* 2013;30:351–3.
- [5].Lee HJ, Goo JM, Im JG. Rapid and irreversible cystic change of pulmonary tuberculosis in an immunocompetent adult. *J Thorac Imaging.* 2003;18:254–6.
- [6].Ko KS, Lee KS, Kim Y, Kim SJ, Kwon OJ, Kim JS. Reversible cystic disease associated with pulmonary tuberculosis: radiologic findings. *Radiology.* 1997;204:165–9.
- [7].Takemura T, Akiyama O, Yanagawa T, Ikushima S, Ando T, Oritsu M. Pulmonary tuberculosis with unusual cystic change in an immunocompromised host. *Pathol Int.* 2000;50:672–7.

[8] Periwal P, Khanna A, Gothi R, Talwar D. Bronchocentric granulomatosis with extensive cystic lung disease in tuberculosis: An unusual presentation. *Lung India*. 2016;33:320–2.

Joane Perim, Eduardo Scarlatelli Pimenta, Edson Marchiori\*

Department of Radiology – Federal, University of Rio de Janeiro, Rua Thomaz Cameron, 438. Valparaíso. CEP 25685.120, Petrópolis. Rio de Janeiro, Brazil

\*Corresponding author.

E-mail address: [edmarchiori@gmail.com](mailto:edmarchiori@gmail.com) (E. Marchiori).

1 December 2019

<https://doi.org/10.1016/j.pulmoe.2019.12.001>

2531-0437/ © 2019 Sociedade Portuguesa de Pneumologia.

Published by Elsevier España, S.L.U. This is an open access article under the CC BY-NC-ND license (<http://creativecommons.org/licenses/by-nc-nd/4.0/>).

## Diffuse cystic lung disease as the primary tomographic manifestation of bronchiolitis: A case series



To the Editor,

The differential diagnosis of diffuse cystic lung diseases (DCLDs) includes a wide range of etiologies with different underlying pathophysiologic mechanisms.<sup>1,2</sup> Although morphological features, such as shape, distribution within the lung parenchyma and adjacent structures, and the presence of other pulmonary manifestations may suggest a specific underlying disease, a significant overlap exists between tomographic findings from different etiologies. In these cases, a lung biopsy may be required to establish a diagnosis.<sup>1,2</sup>

Lymphangiomyomatosis (LAM) is a rare slowly progressive neoplastic lung disease, which has a characteristic radiological appearance and affects mainly women of childbearing age. However, in women with regular and thin-walled cysts without extrapulmonary features compatible with LAM and with low levels of serum vascular endothelial growth factor D (VEGF-D), other potential rare etiologies may be included in the differential diagnosis, such as bronchiolitis, and smoking-related DCLDs.<sup>3–5</sup> We present the cases of eight women that were initially suspected with LAM whose histopathological analysis was compatible with bronchiolitis.

Among 347 patients with DCLDs followed at our center since 2006, eight (2.3%) had diffuse pulmonary cysts on HRCT and a histological diagnosis of cellular and constrictive bronchiolitis and were assessed in this study. Clinical, functional, tomographic, and histological features were analyzed. Written informed consent was obtained from all patients.

Pulmonary function tests adhered to recommended guidelines.<sup>6–8</sup> Computed tomography was performed in a supine position. Quantification of the volume of the cystic lesions was obtained automatically by densitovolumetry using a computer program (Advantage Workstation Thoracic VCAR software; GE Medical Systems, Milwaukee, WI, USA) and by selecting pixels between –1000 and –950 HU on soft tissue filter images. Paraffin blocks of lung tissue were retrieved for histological analysis (hematoxylin and eosin stain). Immunohistochemical staining for smooth muscle actin (SMA) and human melanoma black-45 (HMB-45) antibodies were examined.

Clinical and functional features at the time of lung biopsy are summarized in [Table 1](#). All patients were non-smoking

**Table 1** Demographic, clinical and functional characteristics (n = 8).

Female	8 (100%)
Age at diagnosis (years)	43 ± 14
Time between onset of symptoms and diagnosis (years)	2 ± 2
Current or former smokers	0
Environmental exposure	4 (50%)
Previous (mold and birds)	2 (25%)
Current (only birds)	2 (25%)
Clinical manifestations at diagnosis	
Dyspnea	6 (75%)
mMRC	1 (0–1)
Cough	4 (50%)
Wheezing	1 (12.5%)
Pneumothorax	1 (12.5%)
Pleuritic chest pain	2 (25%)
Xerostomy	2 (25%)
Xerophthalmia	1 (12.5%)
Skin lesions	0
SpO <sub>2</sub> on room air (%)	97 ± 2
Oxygen use	0
Pulmonary function tests	
FVC (L)	3.01 ± 0.73
FVC (%predicted)	88 ± 12
FEV <sub>1</sub> (L)	2.32 ± 0.85
FEV <sub>1</sub> (%predicted)	79 ± 23
FEV <sub>1</sub> /FVC	0.73 ± 0.14
DLCO (mL/min/mmHg)	18.2 ± 4.6
DLCO (%predicted)	76 ± 17
Functional patterns	
Normal spirometry	5 (63%)
Obstructive	2 (25%)
Restrictive	1 (12%)
Air trapping <sup>a</sup>	2 (29%)
Reduced DLCO	3 (38%)
Positive response to BD <sup>b</sup>	1 (17%)

Values are expressed as mean ± SD, median (25th–75th percentiles) or n (%).

Definition of abbreviations: BD: bronchodilator; DLCO: carbon monoxide diffusing capacity; FEV<sub>1</sub>: forced expiratory volume in the first second; FVC: forced vital capacity; mMRC: modified medical research council dyspnea scale; SpO<sub>2</sub>: oxyhaemoglobin saturation by pulse oximetry.

<sup>a</sup> Information available for 7 patients.

<sup>b</sup> Information available for 6 patients.