

## Pulmonary embolism detected by CT pulmonary angiography in hospitalized COVID-19 patients



Dear Editor,

Besides pneumonia, the most frequent serious manifestation of COVID-19, another prominent manifestation is venous thromboembolism (VTE).<sup>1</sup> Data on the prevalence/incidence of pulmonary embolism (PE) in COVID-19 are still limited and often focused on patients in intensive care units (ICU).<sup>2-4</sup> Moreover, few data are available on the severity of PE and on the severity of parenchymal involvement in those who develop PE. Here, we present our data in 157 consecutive COVID-19 patients, hospitalized at Bichat Hospital, who underwent CT pulmonary angiography (CTPA) for suspected PE.

From March 6 to April 20 2020, 1097 patients were hospitalized for COVID-19 at Bichat Hospital, one of the reference centers for infectious diseases in Paris. Of the 157 patients who had CTPA, all with positive SARS-CoV-2 PCR results, 30 were hospitalized in the ICU, with 23 (76.7%) requiring invasive mechanical ventilation. The remaining 127 patients were hospitalized in the general ward for serious COVID-19 manifestations but without critical illness.

For patients hospitalized for COVID-19, the general policy at our institution is to recommend use of anticoagulant therapy based on low-molecular-weight heparin or unfractionated heparin, the intensity varying from low-prophylactic doses to curative treatment via high-prophylactic doses according to the severity of the respiratory condition, the presence of obesity or other risks factors of VTE. In all cases, CTPA was performed to exclude the responsibility of superimposed PE in patients hospitalized for severe COVID-19 and presenting stagnation or worsening of their respiratory condition. CT-angiography scans were acquired with 64-row or greater scanners after injection of 70–90 mL of contrast material with a high concentration of iodine. Imaging was performed with use of a bolus-tracking technique and a threshold of 200 HU in the main pulmonary artery. Images were reconstructed with a slice thickness of 1 mm in mediastinal and parenchymal windows. We retrospectively analyzed the CTPA results as well as the clinical and biological data for the patients. The quality of the examinations was sufficient to assess the presence or absence of PE up to the segmental level. One reader (AK, with 25 years of experience) classified PE location as proximal, lobar, or segmental. The study received approval from the ethics committee of the French Language Society of Pulmonology “Comité d'évaluation des protocoles de recherche observationnels (CEPRO)”.

The incidence of PE detected by CTPA in the 157 patients was 27% (8 of 30) in ICU patients and 12% (15 of 127) in ward patients. PE was proximal, lobar, segmental, and bilateral in 0%, 12.5%, 87.5%, and 25% and 7%, 33%, 60%, and 47% of cases in the ICU and general ward, respectively. CTPA revealed a concomitant evidence of worsening of pneumonia in 75% and 67% of ICU and ward patients with PE, respectively. When using an already published CT severity index (range 0–25),<sup>5</sup> the CT score was 14 on the initial CT and 18 [14–19] at the time of PE ( $p=0.0883$ ). Interestingly, the CT severity

index of patients with and without PE showed no significant difference (18 [14–19] versus 14.5 [10–20];  $p=0.2561$ ).

Clinical and biological data are in [Table 1](#).

D-Dimers levels were significantly higher in ward patients with PE than those without; there was no difference in ICU patients. Using the age-adjusted D-dimers cut-off levels, the sensitivity, specificity, negative predictive value, and positive predictive value of D-dimers for the diagnosis of PE was 100%, 26%, 100%, and 21% respectively ([Table 2](#)). The ROC curve for D-dimer in hospitalized COVID patients with suspected PE is shown in [Fig. 1](#).

Overall, 94.3% of patients received anticoagulant therapy (at least low-prophylactic doses) at the time of CTPA (100% in ICU patients and 93% in ward patients). For patients with PE, the proportion receiving anticoagulant therapy (at least a low-prophylactic dose) at the time of diagnosis was 100% and 86.7% in the ICU and general ward, respectively.

There is mounting evidence that COVID-19 patients, particularly critically ill patients, are at increased risk of VTE.<sup>2-4,6,7</sup> The underlying mechanism involves factors related to COVID-19, such as inflammatory state, hypercoagulability, and endothelial damage, along with classical risk factors of VTE (older age, obesity, dehydration, immobilization, mechanical ventilation) which are often present with severe COVID-19.

A high incidence of PE in COVID-19 patients hospitalized in ICUs has been already reported<sup>3,4,6,7</sup> but data in non-ICU patients remain limited.<sup>6-9</sup> Our data confirm the high incidence of PE in COVID-19 patients hospitalized in ICU but also indicate that PE is also frequently observed in COVID-19 patients hospitalized in the general ward, justifying a high degree of awareness by clinicians.

Not surprisingly, we found that COVID-19 is associated with an hyperinflammatory state that contributes to the hypercoagulability and in turn to the risk of VTE but the levels of CRP and fibrinogen did not differ between those with and without PE. Overall, D-dimers levels were significantly higher in those with PE than in those without PE, in line with the results of other COVID-19 studies.<sup>2,6,8-10</sup> However, D-dimers were not able to predict thrombotic events, especially in ICU patients.

COVID-19 patients hospitalized in general wards because of severe illness are at risk of worsened condition leading, in the most severe cases, to admission to an ICU because of critical symptoms (respiratory failure, shock, multiple organ dysfunction). Likewise, in the ICU, physicians caring for COVID-19 patients are used to facing a general deterioration, with respiratory symptoms at the forefront. In both cases, progression of pneumonia is most often responsible for the observed worsening of the respiratory condition but the latter could also be related to the occurrence of PE or to PE superimposed on extending pneumonia.

From a clinical point of view, the fact that, along with the diagnosis of PE, CTPA also demonstrated a worsening of pneumonia in the majority of cases is informative. Performing thoracic CT without angiography instead of CTPA would have led to missing a significant number of embolic events. With worsening or non-improvement in patients hospitalized for COVID-19, our results argue for (1) increased awareness by clinicians of the possible responsibility of superimposed PE, even though progression of pneumonia may also be documented on chest CT, and (2) use of CTPA, whenever pos-

**Table 1** Characteristics of COVID-19 patients with and without pulmonary embolism (PE) hospitalized in the intensive care unit (ICU) or general ward (GW).

Variable	Total (n = 157)	With PE (n = 23)	Without PE (n = 134)	p
<i>GW patients</i>	127 (80.9%)	15 (65.2%)	112 (83.6%)	
<i>ICU patients</i>	30 (19.1%)	8 (34.8%)	22 (16.4%)	
<b>Clinical characteristics</b>				
<i>Age (years)</i>	63 [52–74]	59 [52–79]	63 [52–73.25]	0.9185
<i>BMI (kg/m<sup>3</sup>)</i>	27.08 [24.5–30.73]	28.11 [24.52–33.57]	26.83 [24.5–30.65]	0.5455
<i>History of VTE</i>	12 (7.6%)	1 (4.3%)	11 (8.2%)	0.4912
<i>Diabetes</i>	48 (30.6%)	6 (26.1%)	42 (31.3%)	0.6132
<i>Dyslipidemia</i>	37 (23.6%)	6 (26.1%)	31 (23.1%)	0.7579
<i>Arterial hypertension</i>	78 (49.7%)	11 (47.8%)	67 (50%)	0.8472
<i>Active malignancy</i>	5 (3.2%)	3 (13%)	2 (1.5%)	0.0036
<i>Smoking status</i>				
Never smoker	109	18	91	0.427
Former smoker	41	5	36	
Active smoker	7	0	7	
<i>Chronic cardiac insufficiency</i>	10 (6.4%)	2 (8.7%)	8 (6%)	0.621
<i>Chronic respiratory insufficiency</i>	1 (0.6%)	0	1 (0.7%)	0.6777
<i>Anticoagulant therapy</i>				
No anticoagulant	9 (5.7%)	2 (8.7%)	7 (5.2%)	0.1232
Low prophylactic dose	39 (24.8%)	5 (21.7%)	34 (25.4%)	
High prophylactic dose	90 (57.3%)	10 (43.5%)	80 (59.7%)	
Curative dose	19 (12.1%)	6 (26.1%)	13 (9.7%)	
<i>Time between symptoms onset and CTPA (days)</i>	13 [10–18]	16 [12–23]	12 [9–18]	0.0164
<i>Time between hospitalization and CTPA (days)</i>	5 [2–9.5]	8 [4–15]	5 [2–8]	0.0134
<b>Radiological characteristics</b>				
<i>Parenchymal evaluation by comparison with the previous chest CT scan</i>				
Worsening	107 (68.1%)	16 (69.6%)	91 (67.9%)	0.2420
Stability	29 (18.5%)	2 (8.7%)	27 (20.2%)	
Improvement	5 (3.2%)	2 (8.7%)	3 (2.2%)	
NA (no previous CT available)	16 (10.2%)	3 (13%)	13 (9.7%)	
<b>Biological characteristics<sup>a,b</sup></b>				
<i>D-Dimers (ng/ml)</i>	1249 [566–3394]	7638 [2179–27544]	1064 [497.5–1767]	<0.0001
GW	1055 [491–1852]	27544 [7448–76306]	870 [478–1573]	<0.0001
ICU	2179 [1280–7638]	3898 [1556–16117]	1747 [1089–6981]	0.3074
<i>Fibrinogen (g/l)</i>	5.17 [4.325–11.81]	4.94 [4.010–6.675]	5.19 [4.34–6.21]	0.9855
GW	5.15 [4.335–6.19]	4.94 [3.045–6.41]	5.19 [4.545–6.14]	0.6511
ICU	5.23 [4.22–6.743]	5.52 [4.46–7.043]	5.23 [3.978–6.548]	0.6047
<i>H-s troponin (μg/l)</i>	0.015 [0.015–0.032]	0.015 [0.015–0.028]	0.015 [0.015–0.032]	0.44
GW	0.015 [0.015–0.0255]	0.015 [0.015–0.0355]	0.015 [0.015–0.026]	0.7024
ICU	0.015 [0.015–0.06475]	0.015 [0.015–0.03450]	0.017 [0.015–0.1048]	0.2341
<i>NT-proBNP (ng/l)</i>	324 [95–1335]	253 [111.5–3096]	329.5 [93.75–1307]	0.7062
GW	244 [83–804.5]	160 [82–520.5]	307 [82–809]	0.4165
ICU	1360 [392–3901]	3096 [350.5–9674]	1069 [392–3647]	0.4815
<i>CRP (mg/l)</i>	52 [21–108.5]	109.5 [31.25–181]	47 [20.5–96.5]	0.0292
GW	50 [21–96.5]	117 [32.25–181]	46 [20.5–93.5]	0.0532
ICU	63.5 [21.25–189.8]	99 [31.25–189.8]	59.5 [17.25–191.3]	0.5574

Data are presented as median [interquartile range] or number (percentage) where appropriate. Groups with and without PE were compared by Mann–Whitney *U* test or chi-square test, for quantitative and categorical variables, respectively. *p* < 0.05 was defined as statistically significant.

Bold values signifies values are statistically significance.

<sup>a</sup> Biological data from samples obtained within 48 h before or after CT pulmonary angiography in the ICU and within 5 days before or after CT in the GW.

<sup>b</sup> Missing data in ICU: D-dimers *n* = 3, NT proBNP *n* = 3, CRP *n* = 2; missing data in GW: D-dimers *n* = 59, fibrinogen *n* = 33, troponin *n* = 39, NT proBNP *n* = 39, CRP *n* = 6.

**Abbreviations:** PE: pulmonary embolism; GW: general ward, ICU: intensive care unit; BMI: body mass index; VTE: venous thromboembolism; CTPA: CT pulmonary angiography; H-s troponin: high sensitivity troponin; BNP: brain natriuretic peptide; CRP: C reactive protein.

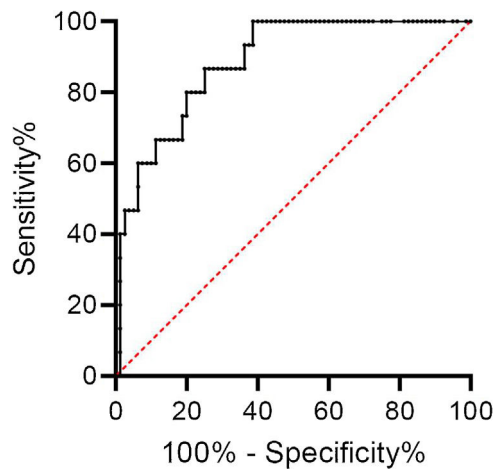
**Table 2** Age-adjusted D-dimers for predicting pulmonary embolism in hospitalized COVID-19 patients with suspected pulmonary embolism: contingency table for sensitivity and specificity calculation.

Age-adjusted D-dimers	Total (n = 157)	PE (n = 23)	No PE (n = 134)
Positive	73	15	58
Negative	20	0	20
D-Dimers non available	64	8	56

Data are presented as numbers.

Age-adjusted D-dimers cut-off level (ng/ml) was age multiplied by 10. D-Dimers were considered positive if they were above this threshold.

Abbreviation: PE: pulmonary embolism.



**Figure 1** ROC curve for D-dimer in hospitalized COVID patients with suspected PE. The area under the curve was 0.885 (95% CI 0.807–0.963). The best cut-off value seemed to be 1274 ng/ml, corresponding to a sensitivity of 100% (95% CI 79.6–100%) and a specificity of 61.3% (95% CI 50.3–61.2%).

sible. New diagnostic techniques of PE have been recently investigated.<sup>11</sup> Given the high incidence of PE in hospitalized COVID patients, they could be useful in this setting.

### Ethics approval and consent to participate

The study received approval from the ethics committee of the French Language Society of Pulmonology "Comité d'évaluation des protocoles de recherche observationnels (CEPRO)".

### Consent for publication

Not applicable.

### Availability of data and material

All data are available for reviewers on demand.

### Funding

No funding.

### Contributions of the authors

VB and HM wrote the manuscript.

GW provided assistance for statistical analysis.

XL, JFT, AD, BLJ, JG, SN, NA retrieved the clinical and biological data from the files.

AK and LS analyzed the CTPAs.

All the authors have checked the manuscript.

### Conflict of interest

Dr. Mal reports grants from Pfizer, personal fees from Boehringer, non-financial support from Novartis, outside the submitted work. Dr. Timsit reports personal fees from Merck, personal fees from Pfizer, personal fees from Gilead, personal fees from Paratek, personal fees from Medimmune, outside the submitted work. The other authors have no conflicts of interest to declare.

### References

1. Driggin E, Madhavan MV, Bikdeli B, Chuich T, Laracy J, Bondi-Zoccai G, et al. Cardiovascular considerations for patients, health care workers, and health systems during the coronavirus disease 2019 (COVID-19) pandemic. *J Am Coll Cardiol.* 2020;75(18):2352–71.
2. Cui S, Chen S, Li X, Liu S, Wang F. Prevalence of venous thromboembolism in patients with severe novel coronavirus pneumonia. *J Thromb Haemost.* 2020;18(6):1421–4.
3. Klok FA, Kruip M, van der Meer NJM, Arbous MS, Gommers D, Kant KM, et al. Incidence of thrombotic complications in critically ill ICU patients with COVID-19. *Thromb Res.* 2020;191:145–7.
4. Poissy J, Goutay J, Caplan M, Parmentier E, Duburcq T, Lassalle F, et al. Pulmonary embolism in COVID-19 patients: awareness of an increased prevalence. *Circulation.* 2020;142(2):184–6.
5. Mahdjoub E, Mohammad W, Lefevre T, Debray MP, Khalil A. Admission chest CT score predicts 5-day outcome in patients with COVID-19. *Intensive Care Med.* 2020;46:1648–50.
6. Middeldorp S, Coppens M, van Haaps TF, Foppen M, Vlaar AP, Muller MCA, et al. Incidence of venous thromboembolism in hospitalized patients with COVID-19. *J Thromb Haemost.* 2020;18(8):1995–2002.
7. Grillet F, Behr J, Calame P, Aubry S, Delabrousse E. Acute pulmonary embolism associated with COVID-19 pneumonia detected by pulmonary CT angiography. *Radiology.* 2020;296(3):E186–8.
8. Bilaloglu S, Aphinyanaphongs Y, Jones S, Iturrate E, Hochman J, Berger JS. Thrombosis in hospitalized patients with COVID-19 in a New York City Health System. *JAMA.* 2020;324(8):799–801.

9. Artifoni M, Danic G, Gautier G, Gicquel P, Boutoille D, Raffi F, et al. Systematic assessment of venous thromboembolism in COVID-19 patients receiving thromboprophylaxis: incidence and role of D-dimer as predictive factors. *J Thromb Thrombolysis*. 2020;50:211–6.
10. Zhang L, Feng X, Zhang D, Jiang C, Mei H, Wang J, et al. Deep vein thrombosis in hospitalized patients with COVID-19 in Wuhan, China: prevalence, risk factors, and outcome. *Circulation*. 2020;142:114–28.
11. Songur Yücel Z, Metin Aksu N, Akkaş M. The combined use of end-tidal carbon dioxide and alveolar dead space fraction values in the diagnosis of pulmonary embolism. *Pulmonology*. 2020;26:192–7.

V. Bunel<sup>a,d,g</sup>, L. Saker<sup>b,d,g</sup>, N. Ajzenberg<sup>c,d,g</sup>, J.F. Timsit<sup>e,d,g</sup>, S. Najem<sup>a,d,g</sup>, B. Lortat-Jacob<sup>f,d,g</sup>, J. Gay<sup>c,d,g</sup>, G. Weisenburger<sup>a,d,g</sup>, H. Mal<sup>a,d,g,\*</sup>, A. Khalil<sup>b,d,g</sup>

<sup>a</sup> Service de pneumologie B, Hôpital Bichat, Assistance Publique-Hôpitaux de Paris, Inserm UMR1152, Université Paris 7 Denis Diderot, 75018 Paris, France

<sup>b</sup> Service de radiologie, hôpital Bichat, Assistance Publique-Hôpitaux de Paris, Paris, France

<sup>c</sup> Service d'hématologie, hôpital Bichat, Assistance Publique-Hôpitaux de Paris, Paris, France

<sup>d</sup> Service des maladies infectieuses et tropicales, hôpital Bichat, Assistance Publique-Hôpitaux de Paris, Paris, France

<sup>e</sup> Service de réanimation médicale et infectieuse, hôpital Bichat, Assistance Publique-Hôpitaux de Paris, Paris, France

<sup>f</sup> Service de réanimation chirurgicale, hôpital Bichat, Assistance Publique-Hôpitaux de Paris, Paris, France

<sup>g</sup> Service de médecine interne, hôpital Bichat, Assistance Publique-Hôpitaux de Paris, Paris, France

\* Corresponding author.

E-mail address: [herve.mal@bch.aphp.fr](mailto:herve.mal@bch.aphp.fr) (H. Mal).

Available online 8 April 2021

<https://doi.org/10.1016/j.pulmoe.2021.03.007>

2531-0437/ © 2021 Sociedade Portuguesa de Pneumologia.

Published by Elsevier España, S.L.U. This is an open access article under the CC BY-NC-ND license (<http://creativecommons.org/licenses/by-nc-nd/4.0/>).

## High-resolution CT features in patients with COVID-19 pneumonia and negative nasopharyngeal and oropharyngeal swabs



To the Editor:

In response to the SARS-CoV-2 outbreak, rapid and accurate diagnosis of COVID-19 pneumonia is essential for controlling the spread of the disease and optimizing patient treatment. Although nasopharyngeal and oropharyngeal (NP/OP) swab tests are commonly used for laboratory confirmation of suspected COVID-19 cases, RT-PCR for detection of the virus has been reported to have very high specificity, but sensitivity as low as 70–80%. Reasons for initial false-negative NP/OP swab tests may include inadequate sampling techniques and/or low patient viral burden.<sup>1</sup>

Chest imaging is indicated for patients with moderate to severe symptoms of COVID-19 infection, regardless of NP/OP swab results and/or for those with confirmed diagnosis and evidence of worsening respiratory status.<sup>2</sup> Recently, it has been reported that patients who initially tested negative for COVID-19 by RT-PCR were less likely to exhibit pulmonary consolidation by CT.<sup>3</sup>

This study aimed to describe the chest CT findings in patients with COVID-19 pneumonia who had initially tested negative by NP/OP swab. The final goal is to assist physicians to avoid missed or delayed diagnoses of SARS-CoV-2 infection.

Our study was conducted in accordance with the Declaration of Helsinki and approved by the Padova Hospital ethics committee. De-identified CT scans were assessed by on-site radiologists at the Department of Radiology of Padova University. All CT scans were from patients admitted to the emergency department (ED) for suspected COVID-19

pneumonia, according to exposure history and clinical data, between February 17 and May 5, 2020.

The following inclusion criteria were used: (1) Laboratory confirmed SARS-CoV-2 infection; (2) No previous known underlying lung disease; (3) CT examination performed 1–3 days from admission to the ED. All patients included in the study group initially tested negative for COVID-19 by NP/OP swab test. All results were compared with those in the group of patients who initially tested positive for COVID-19. Two radiologists with over 5 years' experience analysed all CT images in consensus. The following CT features were assessed: distribution pattern (peripheral or central); number of lobes involved (one, two, or more); main radiological feature (ground-glass opacity [GGO], consolidation, or GGO with consolidation); concomitant lung abnormalities (crazy paving pattern, fibrous stripes); and extrapulmonary manifestations (mediastinal lymph node enlargement, pleural effusion).

Out of 453 patients admitted to the ED and administered chest CT during the study period, 159 had a confirmed diagnosis of COVID-19 pneumonia, according to WHO guidance.<sup>4</sup> In 28 of these confirmed cases (mean age, 64 ± 15 years; male/female, 18/10), the patients initially tested negative by RT-PCR (study group). SARS-CoV-2 infection was confirmed in these patients by repeated NP/OP swab test (nineteen cases) and bronchoalveolar lavage test (nine cases) over a 6-day duration (range, 3–8 days).

Unilateral lung involvement was detected in 20 out of the 28 cases. Radiologic abnormalities had peripheral distribution in 27 cases (96%) and involved two or more lobes in four cases (14%). Unilateral GGOs with or without consolidations or crazy paving were significantly more common among patients in the study group compared with those who initially tested positive (19/28 vs. 6/131;  $p < 0.0001$ ) (Table 1) (Fig. 1). Fibrous stripes on the basal regions were present in seven patients. Finally, mediastinal lymph node