

CASE REPORT

A case of massive hemoptysis related to a smoking-history: an acquired form of the Dieulafoy's disease?



A. Padilla-Serrano^{a,*}, V. Estrella-Palomares^a, B. Martínez-Palacios^a, J. González-Spínola^b

^a Intensive Care Unit, La Mancha Centro General Hospital, Alcázar de San Juan, Ciudad Real, Spain

^b Department of Radiology, La Mancha Centro General Hospital, Alcázar de San Juan, Ciudad Real, Spain

Received 20 March 2015; accepted 23 June 2015

Available online 27 July 2015

KEYWORDS

Dieulafoy's disease;
Massive hemoptysis;
Hypervascularization;
Bronchovascular
fistula;
Smoking history;
Vascular lesion

Abstract The hypervascularization of the bronchial wall, secondary to chronic bronchopulmonary inflammation is a bleeding etiology in smokers, but insufficient to explain certain massive recurrent cases. We report a case of a woman with a smoking history who presented a recurrent and massive hemoptysis. A diagnostic study with laboratory tests, bronchoscopy, computed tomography and echocardiogram did not identify the etiological cause. However, bronchial arteriography showed right and left bronchial tortuous and dilated arteries and demonstrated that a bronchovascular fistula was the origin of the hemoptysis. An acquired form of the Dieulafoy's disease in this context of a smoking history might justify such findings. Bronchial arteriography as a diagnostic method should be the preferred choice rather than bronchoscopy in these cases.

© 2015 Sociedade Portuguesa de Pneumologia. Published by Elsevier España, S.L.U. All rights reserved.

Introduction

Hemoptysis is a frequent symptom in pneumology and requires rapid and careful intervention. There are numerous causes of bleeding from the lower respiratory tract.

Bronchiectasis, tuberculosis, bronchogenic carcinoma, and various lung infections are still believed to be the most common causes of massive hemoptysis.^{1,2} A recent large series demonstrates the prevalence of the causes of massive hemoptysis in a university hospital setting.³ Further, depending upon the study, in as many as 30 percent of patients with hemoptysis no cause can be identified even after careful evaluation, including bronchoscopy. These patients are classified as having either cryptogenic or idiopathic hemoptysis.⁴ In cases in which no associated

* Corresponding author at: Avda. de la Constitución, 3, 13600 Alcázar de San Juan, Ciudad Real, Spain.

E-mail address: apadilla@jccm.es (A. Padilla-Serrano).

comorbidity can be confidently excluded, the subgroup of cryptogenic hemoptysis shares common risk factors with patients whose hemoptysis is explained by chronic bronchitis in a context of smoking history.^{5,6} Hypervascularization within the bronchial wall remains an ill-defined process in the pathogenesis of chronic airway inflammation, resembling the endobronchial findings described in Dieulafoy's disease.

We present a case of massive hemoptysis due to hypervascularization and a subsequent bronchovascular fistula, related to a smoking history.

Case report

We report a remarkable case of 49-years-old women, housewife, with a smoking history (29 packs cigarettes/year), without other toxics exposure, presenting cough and abundant blood expectoration, which was not quantified, without other semiology.

In the emergency room, the patient was hemodynamically stable. She required supplemental oxygen therapy without noninvasive or invasive mechanical ventilatory support. Laboratory studies found a hemoglobin of 9.0 g/dL, without thrombocytopenia or coagulopathy. The urgent bronchoscopy showed plentiful blood remnants on tracheo-bronchial tree and signs of chronic inflammation without active bleeding. Therefore, we decided to continue diagnostic evaluation because the bleeding had ceased and the patient remained clinically stable.

The patient had no telangiectasias on skin or mucous, and there was no family history of hemoptysis, brain aneurisms, epistaxis or gastrointestinal bleeding, which might have suggested possible hereditary hemorrhagic telangiectasia. Additional laboratory testing discarded other causes of hemoptysis, ranging from liver dysfunction, neoplasms or infection, to immune or inflammatory disorders. Radiological studies discarded regional hyperlucency or bullae. Moreover, computed tomography of the chest discarded those abnormalities that are difficult to detect with bronchoscopy, such as mass lesions (e.g., arteriovenous malformations, cancer or aspergilloma), bronchiectasis, lung abscess or pulmonary artery aneurysm. An echocardiogram discarded mitral stenosis, pulmonary hypertension, endocarditis or congenital heart disease. Pulmonary function testing showed a moderate (GOLD grade 2) chronic obstructive pulmonary disease (COPD).

On the seventh day, a new episode of massive hemoptysis took place. On this occasion, the patient was hemodynamically unstable and the laboratory tests disclosed a hemoglobin of 7.3 g/dL. Two units of "packed" red blood cells and sufficient volume of crystalloid fluid were administered. The patient refused another bronchoscopy. Urgent bronchial arteriography was performed. Selective catheterisation of the right intercostobronchial trunk showed features of marked hypervascularization, including a tortuous and dilated right bronchial artery and bronchial-to-pulmonary retrograde shunts in the right apex (Fig. 1). Selective catheterisation of the left bronchial artery showed a bronchovascular fistula, where contrast leaked from the blood vessel drawing the left bronchial tree bronchography (Fig. 2, panel A), and a tortuous and dilated superior division

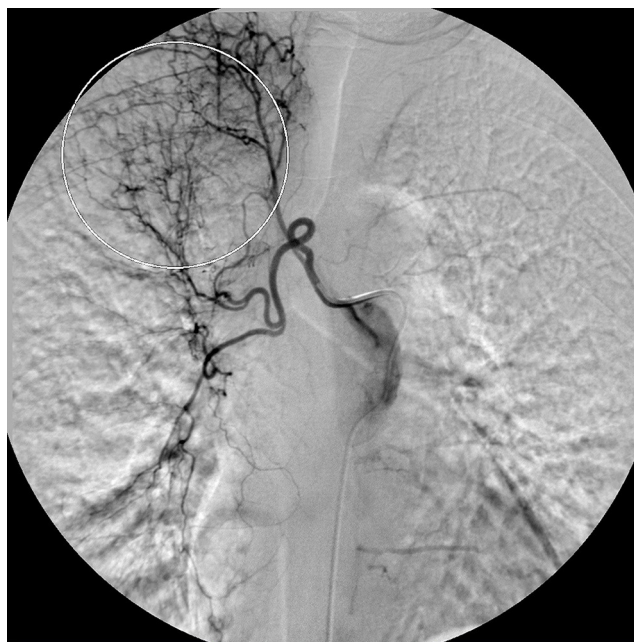


Figure 1 Selective catheterisation of the right intercostobronchial trunk. Circle: bronchial-to-pulmonary retrograde shunts in the right apex.

of left bronchial artery too (Fig. 2, panel B). Immediate cessation of hemoptysis was obtained after embolization of the bronchovascular fistula and the right intercostobronchial trunk with polyvinyl alcohol microspheres of 700–900 μm until complete stasis of the artery. Following the procedure, the patient was stabilized hemodynamically and did not present new episodes of hemoptysis. After the last episode, the patient stopped smoking and she has remained asymptomatic until now.

Discussion

We have presented a case of massive hemoptysis due to bronchovascular fistula in a patient with a smoking history. An exhaustive diagnostic evaluation was performed with laboratory tests, bronchoscopy, computed tomography and echocardiogram, but the etiology was not found. However, bronchial arteriography showed right and left bronchial tortuous and dilated arteries and a bronchovascular fistula was demonstrated in vivo to be the origin of the patient's hemoptysis.

Dieulafoy's disease is a vascular anomaly characterized by the presence of a tortuous dysplastic artery in the submucosa. The French surgeon Georges Dieulafoy first described it in 1898 as a cause of gastrointestinal bleeding in the stomach,⁷ but it has been identified in other parts of the body, including the respiratory tract.⁸ In fact, bronchial Dieulafoy's disease is extremely rare, and it is still unknown whether the origin of the anomaly is congenital or acquired, though age and tobacco use are thought to have an influence on the occurrence of the disease.⁹ Furthermore, the trigger factor of the vessel rupture is unknown. On the other hand, although bronchitis is an etiology of hemoptysis, it is controversial whether this entity alone is sufficient

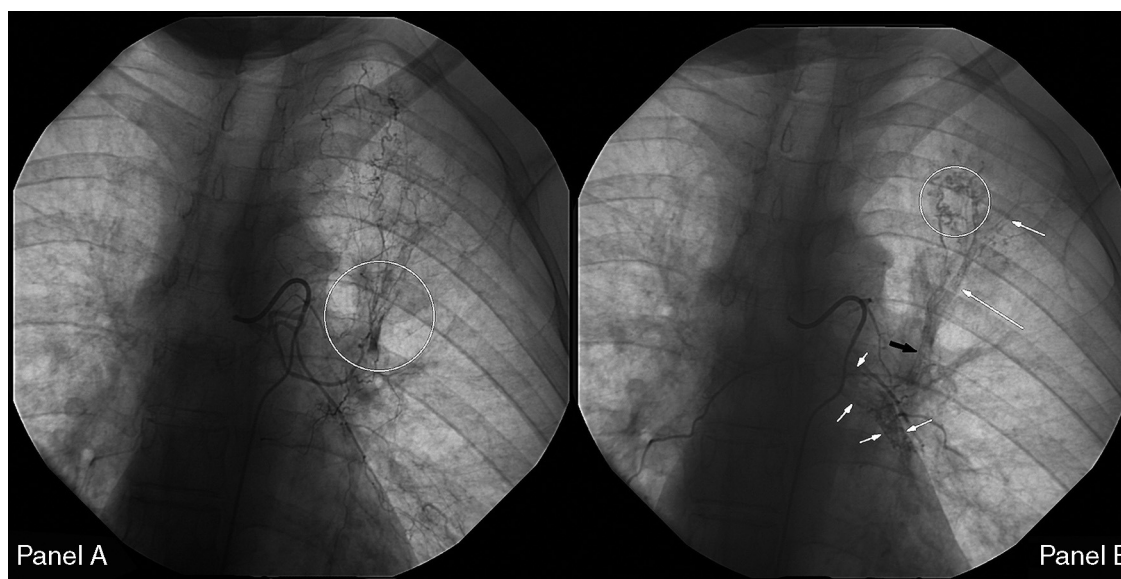

Figure 2 Left bronchial arteriography. *Panel A.* Circle: bronchovascular fistula. *Panel B.* Black arrow: Fistula formation between a vessel and the tracheobronchial tree. White arrows: contrast leakage from the vessel drawing the bronchial tree bronchography. Circle: tortuous and dilated superior division of left bronchial artery.

to cause massive hemoptysis and many clinicians believe that other contributing factors must be present for massive hemoptysis to occur in the setting of bronchitis alone.² Menchini et al. have reported a retrospective cohort of 35 patients with smoking-related bronchopulmonary disease and no associated comorbidity, who were referred for embolization to cease hemoptysis. Bronchial artery angiography revealed moderate or severe hypervascularization in 28 (80%) patients and no statistically difference was observed between the angiographic findings and the severity of COPD, tobacco consumption or the amount of bleeding.¹⁰ He then suspected of the Dieulafoy's disease in these cases. Therefore, recurrent and massive hemoptysis caused by hypervascularization within the bronchial wall due to chronic airway inflammation in the context of a smoking history might be explained by an acquired form of this entity.

Regarding the diagnosis of Dieulafoy's disease of the bronchus, the bronchoscopy may show a small, sessile, non-pulsating nodular lesion, often with a white cap, and apparently normal mucosa.⁸ At times, the bronchoscopic appearance is not diagnostic because the site where the abnormal vessel opens into the bronchus is usually a pinpoint mucosal defect surrounded by normal-appearing mucosa and this small defect is often not seen on bronchoscopy due to pooling of blood or filling of the bronchial lumen with clots. This is what occurred in our case. Bronchial Dieulafoy's disease can only be definitively diagnosed by histopathologic examination¹¹; however, bronchial biopsy in such cases can result in severe hemorrhage.¹² Moreover, performing biopsy would be not useful in this context, because the diagnosis of Dieulafoy's disease of the bronchus should be based on the pathological examination of a large surgical lung resection.⁹ Endobronchial ultrasound may be helpful in detecting the vascular nature of the lesion,¹³ but this was not available at our hospital. Hope-Gill et al. recommend the bronchial

arteriography as the most appropriate initial investigation in these cases.¹⁴ There are no specific angiographic criteria for diagnosing Dieulafoy's disease, but the finding of a tortuous and ectatic artery is suggestive of this condition. Selective embolization has been proposed as a method for stopping the bleeding,^{14,15} and only in a few cases does the patient require surgical resection.⁴ Recently, Dalar et al. have proposed the argon plasma coagulation of these lesions.¹⁶

We have described a peculiar case of massive and recurrent hemoptysis without associated comorbidity, except smoking. The tortuous and dilated bronchial arteries and bronchovascular fistula that we found in the context of hypervascularization might be an acquired form of the Dieulafoy's disease, which would explain the magnitude of bleeding.¹⁰ The occurrence of this fact during the bronchial arteriography is extremely rare. To the best of our knowledge, an image of such active bleeding through the bronchovascular fistula has never previously been demonstrated.

Conclusion

Nowadays, Dieulafoy's disease should always be included in the differential diagnosis of any patient with massive and recurrent hemoptysis. We then considered this possibility given the absence of comorbidity in our patient, except for a smoking history. Since tobacco consumption long-term causes hypervascularization within the bronchial wall, secondary to chronic airway inflammation in the setting of bronchitis, we believe that this disease could be more common than the reports in the literature suggest. Although excision of the affected portion of lung is the gold standard for the definitive histopathologic diagnosis of Dieulafoy's disease, surgery is only the option in recurrent and uncontrolled cases. Bronchial arteriography as diagnostic method should be the preferred choice rather than bronchoscopy when the

Dieulafoy's disease is suspected, in order to avoid hazardous and unnecessary biopsy procedures altogether.

Conflicts of interest

The authors have no conflicts of interest to declare.

Ethical disclosures

Protection of human and animal subjects. The authors declare that no experiments were performed on humans or animals for this study.

Confidentiality of data. The authors declare that no patient data appear in this article.

Right to privacy and informed consent. The authors declare that no patient data appear in this article.

References

1. Cahill BC, Ingbar DH. Massive hemoptysis. Assessment and management. *Clin Chest Med.* 1994;15:147–67.
2. Hirshberg B, Biran I, Glazer M, Kramer MR. Hemoptysis: etiology, evaluation, and outcome in a tertiary referral hospital. *Chest.* 1997;112(2):440–4.
3. Soares Pires F, Teixeira N, Coelho F, Damas C. Hemoptysis-etiology, evaluation and treatment in a university hospital. *Rev Port Pneumol.* 2011;17(1):7–14.
4. Savale L, Parrot A, Khalil A, Antoine M, Théodore J, Carette MF, et al. Cryptogenic hemoptysis. From a benign to a life-threatening pathologic vascular condition. *Am J Respir Crit Care Med.* 2007;175:1181–5.
5. Adelman M, Haponik EF, Bleecker ER, Britt EJ. Cryptogenic hemoptysis: clinical features, bronchoscopic findings, and natural history in 67 patients. *Adv Intern Med.* 1985;102:829–34.
6. Hiyama J, Horita N, Shiota Y, Ono T, Yamakido M. Cryptogenic hemoptysis and smoking. *Chest.* 2002;121:1375–6.
7. Dieulafoy G. Exulceratio simplex: l'intervention chirurgicale dans les hématomésis foudroyantes consécutives à l'exulceration simple de l'estomac. *Bull Acad Méd.* 1898;49:49–84.
8. Kolb T, Gilbert C, Fishman EK, Terry P, Pearse D, Feller-Kopman D, et al. Dieulafoy's disease of the bronchus. *Am J Respir Crit Care Med.* 2012;186(11):1191.
9. Parrot A, Antoine M, Khalil A, Théodore J, Mangiapan G, Bazelly B, et al. Approach to diagnosis and pathological examination in bronchial Dieulafoy disease: a case series. *Respir Res.* 2008;9:58.
10. Menchini L, Remy-Jardin M, Faivre JB, Copin MC, Ramon P, Matran R, et al. Cryptogenic haemoptysis in smokers: angiography and results of embolisation in 35 patients. *Eur Respir J.* 2009;34:1031–9.
11. Stoopen E, Baquera-Heredia J, Cortes D, Green L. Dieulafoy's disease of the bronchus in associated with a paravertebral neurilemoma. *Chest.* 2001;119:292–4.
12. Van der Werf TS, Timmer A, Zijlstra JG. Fatal haemorrhage from Dieulafoy's disease of the bronchus. *Thorax.* 1999;54:184–5.
13. Gurioli C, Casoni GL, Gurioli C, Tomassetti S, Romagnoli M, Ravaglia C, et al. Endobronchial ultrasound in Dieulafoy's disease of the bronchus: an additional application of EBUS. *Monaldi Arch Chest Dis.* 2010;73(4):166–8.
14. Hope-Gill B, Prathibha BV. Bronchoscopic and angiographic finding in Dieulafoy's disease of the bronchus. *Hisp Med.* 2002;63:178–9.
15. Bhatia P, Hendy MS, Li-Kam-Wa E, Bowyer PK. Recurring embolotherapy in Dieulafoy's disease of the bronchus. *Can Respir J.* 2003;10:331–3.
16. Dalar L, Sökücü SN, Ozdemir C, Büyükkale S, Altın S. Endobronchial argon plasma coagulation for treatment of Dieulafoy disease. *Respir Care.* 2015;60:e11–3.