

A. Oliveira*, L. Martins, M. Félix

Pediatric Medical Department, Hospital Pediátrico de Coimbra, Centro Hospitalar e Universitário de Coimbra, Portugal

*Corresponding author.

E-mail addresses: alexandra.raquel@gmail.com (A. Oliveira), lvmartins@hotmail.com (L. Martins), miguel.felix@chc.min-saude.pt (M. Félix).

<http://dx.doi.org/10.1016/j.rppnen.2015.04.004>

Non-small cell lung cancer in octogenarian patients – The experience in a tertiary university hospital



Dear Editor,

Lung cancer is the most common cancer worldwide, and the leading cause of cancer-related death.¹ It is considered a disease of the elderly, and octogenarians represent a rapidly growing population of patients diagnosed with this disease.² Despite this, the evidence-based standard of care for these patients is limited. Therefore, the clinical practice in this population often poses challenges to clinicians.

The authors report the incidence, clinical characteristics, treatment and prognosis of non-small cell lung cancer (NSCLC) in octogenarian patients (80 years and over), in a tertiary academic hospital in Oporto, Portugal. We retrospectively evaluated 1292 patients newly diagnosed with lung cancer, from January 2009 to December 2014. For the purpose of analysis, only patients with NSCLC that had a follow-up in our center were included.

Ninety-two octogenarians were included (7.1% of total), 79.3% ($n=73$) were male with a median age of 82.0 years (80–90). Smoking history was present in 65% ($n=58$) of patients. The median time from symptom onset to diagnosis was 2.0 months (0–12.0). The diagnosis was obtained by bronchoscopy in 45.7% ($n=42$) of patients, transthoracic biopsy guided by CT in 46.7% ($n=43$) and blind pleural biopsy in 7.6% ($n=7$). Adenocarcinoma was the most common histopathological type, recorded in 51.1% ($n=47$) of patients, followed by squamous cell carcinoma in 41.3% ($n=38$). Clinical staging revealed 23.8% ($n=22$) of patients with stage I and II, 8.7% ($n=8$) with III-A and 67.4% ($n=62$) with III-B and IV. The initial Performance Status (PS) was 0 and 1 in 60.9% ($n=56$) of patients, 2 in 16.3% ($n=15$) and 3 and 4 in 22.8% ($n=21$). After careful consideration, the following treatments were performed: surgery in 5.4% ($n=5$), surgery followed by adjuvant chemotherapy in 1.1% ($n=1$), chemotherapy only in 17.4% ($n=16$), chemotherapy plus conventional radiotherapy in 8.7% ($n=8$), conventional radiotherapy in 5.4% ($n=5$) and stereotactic body radiation therapy (SBRT) in 2.2% ($n=2$). Most patients (58.7%, $n=54$) were submitted to best supportive care (BSC), two-thirds presenting PS ≥ 2 . Platinum-based doublet regimens were used in one-third of patients submitted to chemotherapy. Surgery was performed on 6 patients: lobectomy and mediastinal lymph node dissection in 3, lobectomy without mediastinal lymph node dissection in

1, segmentectomy in 1 and atypical lung resection in 1. Using Charlson Comorbidity Index, all patients scored high, even the potential surgical candidates, reducing the number of surgeries performed. One postoperative death was the major complication encountered. During the follow-up period, 38% ($n=35$) of octogenarians are still alive, 53.5% ($n=49$) died and 8.7% ($n=8$) were lost to follow-up. In Kaplan–Meier analyses, the median survival rate was about 2.5 months in the BSC group and 12.5 months for those submitted to other non-surgical treatments. More than 80.0% of patients who had surgery are still alive (Fig. 1).

With social and medical evolutions, and consequently global aging, it is expected that more elderly will be affected by lung cancer. For clinicians, it will be increasingly a challenge to manage these patients because they usually have a high burden of comorbidities, a high risk of complications and shorter life expectancy.^{3,4} Thus, some clinicians are reluctant to propose anticancer treatments (including surgery) to octogenarians. Nevertheless, surgery is the best chance of a cure,⁴ and should not be denied based on older age alone. Furthermore, the mortality rates associated to surgery have reached acceptable levels.⁵ In our

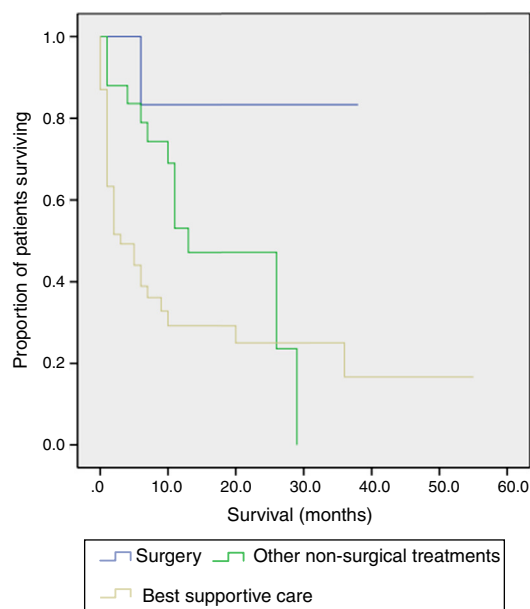


Figure 1 Kaplan–Meier survival curves according to treatment performed (surgery, other non-surgical treatments and best supportive care).

study, we found that more than 40% of patients were submitted to some form of anticancer treatment. Only a minority of octogenarians presented in surgical staging, and only just over a quarter of them were submitted to surgery, with acceptable outcomes. The presence of significant comorbidities was a major reason for excluding surgery. In patients with contraindications to surgery, SBRT has emerged as an attractive treatment option.⁶ Two of our patients had SBRT, without significant morbidity. Chemotherapy was also performed in about a quarter of patients. In a recent study, octogenarians with NSCLC treated with chemotherapy showed prolonged survival compared with those submitted to BSC.⁷

Our results suggest that selected octogenarians with NSCLC, regardless of age, may benefit from specific anticancer treatment. Thus, a multidisciplinary assessment is recommended. Further studies are warranted to provide an optimal treatment approach for octogenarians.

Conflicts of interest

The authors have no conflicts of interest to declare.

References

1. Blanco R, Maestu I, de la Torre MG, Cassinello A, Nunez I. A review of the management of elderly patients with non-small-cell lung cancer. *Ann Oncol*. 2015;26:451–63.
2. Blanchard EM, Arnaoutakis K, Hesketh PJ. Lung cancer in octogenarians. *J Thorac Oncol*. 2010;5:909–16.
3. Zhang J, Xue ZQ, Chu XY, Wang YX, Zhao JH, Xu C, et al. Surgical treatment and prognosis of octogenarians with non-small cell lung cancer. *Asian Pac J Trop Med*. 2012;5:465–8.
4. Rizzi A, De Simone M, Raveglia F, Cioffi U. The role of thoracic surgery in octogenarians with non-small cell lung cancer. *Interact Cardiovasc Thorac Surg*. 2013;16:680.
5. Guerra M, Neves P, Miranda J. Surgical treatment of non-small-cell lung cancer in octogenarians. *Interact Cardiovasc Thorac Surg*. 2013;16:673–80.
6. Sandhu AP, Lau SK, Rahn D, Nath SK, Kim D, Song WY, et al. Stereotactic body radiation therapy in octogenarians with stage I lung cancer. *Clin Lung Cancer*. 2014;15:131–5.
7. Sim SH, Kim YJ, Kim SH, Keam B, Kim TM, Lee SH, et al. Current status of chemotherapy use and clinical outcome in octogenarians with advanced non-small cell lung cancer. *J Cancer Res Clin Oncol*. 2015;14:1073–81.

H. Dabó^{a,*}, R. Gomes^b, V. Hespanhol^{a,c}, H. Queiroga^{a,c}

^a Pulmonology Department of Centro Hospitalar de São João, Oporto, Portugal

^b Pulmonology Department of Hospital Sousa Martins, Unidade Local de Saúde – Guarda, Portugal

^c School of Medicine, University of Oporto, Oporto, Portugal

* Corresponding author.

E-mail address: hansdabo@yahoo.com.br (H. Dabó).

<http://dx.doi.org/10.1016/j.rppnen.2015.06.006>

Late onset congenital cystic adenomatous malformation associated with intra-lobar pulmonary sequestration



Dear Editor,

Lung congenital malformations, which include congenital cystic adenomatous malformation (CCAM) and pulmonary sequestration (PS), are rare. PS accounts for 0.15–6.45% of lung malformations and is characterized by a nonfunctioning mass of pulmonary tissue that receives arterial supply from the systemic circulation and lacks communication with the tracheobronchial tree. It is classified as intralobar PS (IL-PS) if it is contained within the normal lung and drains to the pulmonary veins and as extralobar PS (EL-PS) if it is separated from the surrounding parenchyma by his own pleural covering and drains to the systemic circulation.^{1–3} CCAM is responsible for 25–30% of congenital lung malformations. It is a hamartomatous lesion with anomalous development, characterized by a mass of lung tissue from different pulmonary origins and various degrees of cyst formation that communicates with the tracheobronchial tree and is supplied and drained by the pulmonary circulation.^{1–3} CCAM is classified into 5 types, based on histological features and level of malformation in the airway and lung.⁴ These lesions

are usually diagnosed in the neonatal period, their presentation in adulthood is less frequent.^{1,2} Despite the fact that they are two of the most common lung malformations their association is uncommon, particularly for IL-PS and CCAM.^{2,5}

We report a case of a 36 year-old woman, never smoker, observed in the outpatient clinic for recurrent pneumonias. Over the past 5 years, she reported several pneumonias, all slowly resolving and in need of multiple courses of antibiotics. Between infections she complained of dry cough and left pleuritic chest pain. She worked as a care assistant in a continuing care unit and apart from the recurrent infections had no other significant medical history. Physical examination was unremarkable and laboratory findings and bronchoscopy were normal. Chest X-ray showed a reticular opacity in the left lower field and a computed tomography (CT), performed two months earlier, showed a heterogeneous consolidation on the left lower field with millimetric air spaces compatible with cysts (Fig. 1A). Chest CT was repeated, revealing a 10 cm heterogeneous consolidation on the left inferior lobe, with arterial supply arising from the thoracic descending aorta and venous drainage to the pulmonary veins (Fig. 1B–F). The second CT was performed during another infectious episode and radiologic findings suggested IL-PS with superimposed infection. The infection was resolved and the patient was submitted to left inferior lobectomy with an uneventful post-operative recovery. Surgical procedure confirmed the anomalous vascularization