

study, we found that more than 40% of patients were submitted to some form of anticancer treatment. Only a minority of octogenarians presented in surgical staging, and only just over a quarter of them were submitted to surgery, with acceptable outcomes. The presence of significant comorbidities was a major reason for excluding surgery. In patients with contraindications to surgery, SBRT has emerged as an attractive treatment option.⁶ Two of our patients had SBRT, without significant morbidity. Chemotherapy was also performed in about a quarter of patients. In a recent study, octogenarians with NSCLC treated with chemotherapy showed prolonged survival compared with those submitted to BSC.⁷

Our results suggest that selected octogenarians with NSCLC, regardless of age, may benefit from specific anticancer treatment. Thus, a multidisciplinary assessment is recommended. Further studies are warranted to provide an optimal treatment approach for octogenarians.

Conflicts of interest

The authors have no conflicts of interest to declare.

References

1. Blanco R, Maestu I, de la Torre MG, Cassinello A, Nunez I. A review of the management of elderly patients with non-small-cell lung cancer. *Ann Oncol*. 2015;26:451–63.
2. Blanchard EM, Arnaoutakis K, Hesketh PJ. Lung cancer in octogenarians. *J Thorac Oncol*. 2010;5:909–16.
3. Zhang J, Xue ZQ, Chu XY, Wang YX, Zhao JH, Xu C, et al. Surgical treatment and prognosis of octogenarians with non-small cell lung cancer. *Asian Pac J Trop Med*. 2012;5:465–8.
4. Rizzi A, De Simone M, Raveglia F, Cioffi U. The role of thoracic surgery in octogenarians with non-small cell lung cancer. *Interact Cardiovasc Thorac Surg*. 2013;16:680.
5. Guerra M, Neves P, Miranda J. Surgical treatment of non-small-cell lung cancer in octogenarians. *Interact Cardiovasc Thorac Surg*. 2013;16:673–80.
6. Sandhu AP, Lau SK, Rahn D, Nath SK, Kim D, Song WY, et al. Stereotactic body radiation therapy in octogenarians with stage I lung cancer. *Clin Lung Cancer*. 2014;15:131–5.
7. Sim SH, Kim YJ, Kim SH, Keam B, Kim TM, Lee SH, et al. Current status of chemotherapy use and clinical outcome in octogenarians with advanced non-small cell lung cancer. *J Cancer Res Clin Oncol*. 2015;14:1073–81.

H. Dabó^{a,*}, R. Gomes^b, V. Hespanhol^{a,c}, H. Queiroga^{a,c}

^a Pulmonology Department of Centro Hospitalar de São João, Oporto, Portugal

^b Pulmonology Department of Hospital Sousa Martins, Unidade Local de Saúde – Guarda, Portugal

^c School of Medicine, University of Oporto, Oporto, Portugal

* Corresponding author.

E-mail address: hansdabo@yahoo.com.br (H. Dabó).

<http://dx.doi.org/10.1016/j.rppnen.2015.06.006>

Late onset congenital cystic adenomatous malformation associated with intra-lobar pulmonary sequestration



Dear Editor,

Lung congenital malformations, which include congenital cystic adenomatous malformation (CCAM) and pulmonary sequestration (PS), are rare. PS accounts for 0.15–6.45% of lung malformations and is characterized by a nonfunctioning mass of pulmonary tissue that receives arterial supply from the systemic circulation and lacks communication with the tracheobronchial tree. It is classified as intralobar PS (IL-PS) if it is contained within the normal lung and drains to the pulmonary veins and as extralobar PS (EL-PS) if it is separated from the surrounding parenchyma by his own pleural covering and drains to the systemic circulation.^{1–3} CCAM is responsible for 25–30% of congenital lung malformations. It is a hamartomatous lesion with anomalous development, characterized by a mass of lung tissue from different pulmonary origins and various degrees of cyst formation that communicates with the tracheobronchial tree and is supplied and drained by the pulmonary circulation.^{1–3} CCAM is classified into 5 types, based on histological features and level of malformation in the airway and lung.⁴ These lesions

are usually diagnosed in the neonatal period, their presentation in adulthood is less frequent.^{1,2} Despite the fact that they are two of the most common lung malformations their association is uncommon, particularly for IL-PS and CCAM.^{2,5}

We report a case of a 36 year-old woman, never smoker, observed in the outpatient clinic for recurrent pneumonias. Over the past 5 years, she reported several pneumonias, all slowly resolving and in need of multiple courses of antibiotics. Between infections she complained of dry cough and left pleuritic chest pain. She worked as a care assistant in a continuing care unit and apart from the recurrent infections had no other significant medical history. Physical examination was unremarkable and laboratory findings and bronchoscopy were normal. Chest X-ray showed a reticular opacity in the left lower field and a computed tomography (CT), performed two months earlier, showed a heterogeneous consolidation on the left lower field with millimetric air spaces compatible with cysts (Fig. 1A). Chest CT was repeated, revealing a 10 cm heterogeneous consolidation on the left inferior lobe, with arterial supply arising from the thoracic descending aorta and venous drainage to the pulmonary veins (Fig. 1B–F). The second CT was performed during another infectious episode and radiologic findings suggested IL-PS with superimposed infection. The infection was resolved and the patient was submitted to left inferior lobectomy with an uneventful post-operative recovery. Surgical procedure confirmed the anomalous vascularization

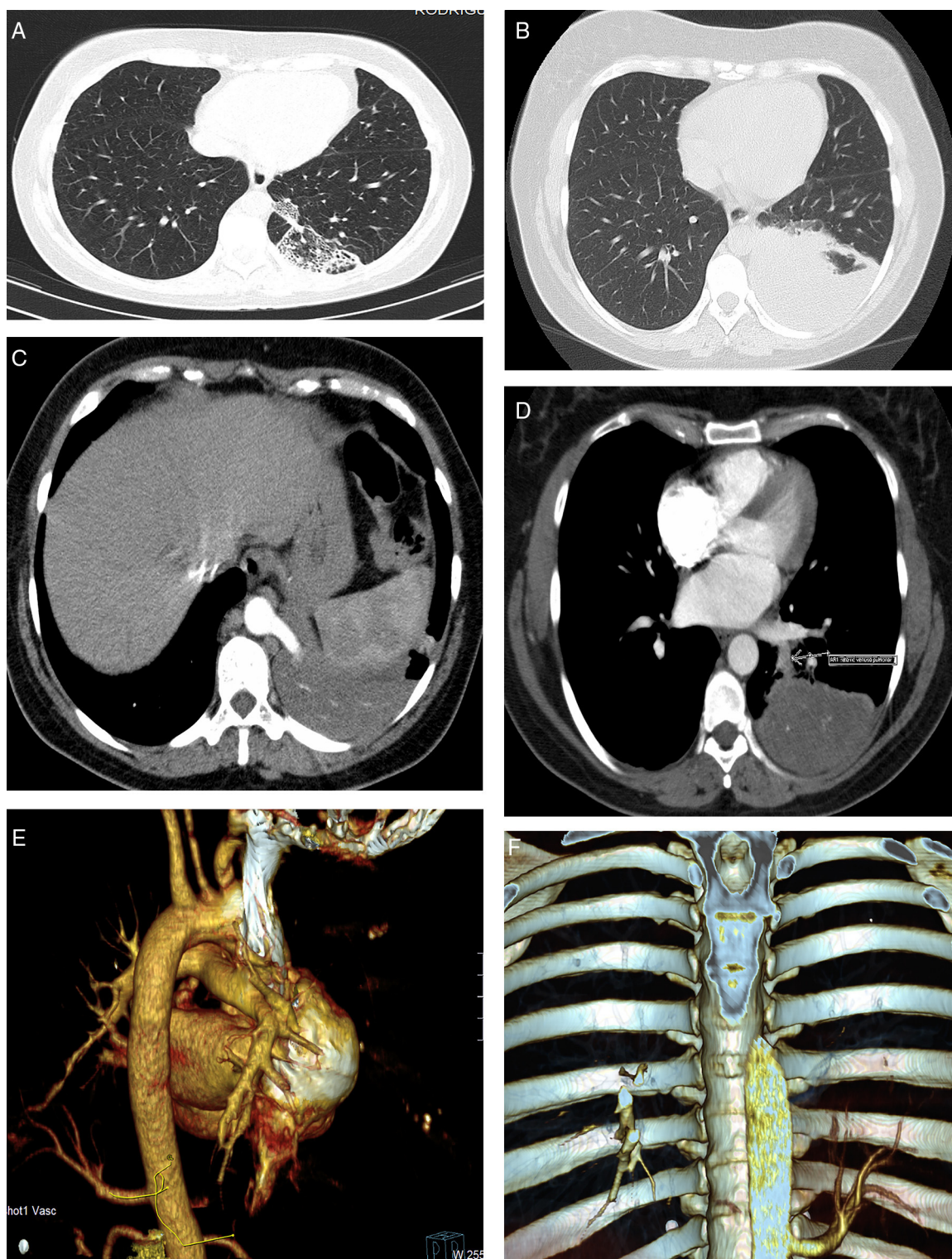


Fig. 1 (A) The first chest CT performed, showing a heterogeneous posteromedial consolidation in the left lower lobe comprising multiple cysts. (B) The second chest CT showing posteromedial hepatization of the left lower field, compatible with superimposed infection. (C) CT angiography showing the anomalous artery arising from the thoracic aorta. (D) CT angiography images showing the venous drainage (arrow) to the pulmonary veins. (E-F) 3D CT reconstructions showing the anomalous artery.

and histological findings were compatible with CCAM type 2. A diagnosis of CCAM type 2 associated with IL-PS was established based on imaging and histological findings. The patient remained asymptomatic 1 year after surgery.

This case combines an unusual association of congenital malformations – IL-PS and CCAM – with an infrequent diagnosis in adulthood. Few cases are described in literature of CCAM and IL-PS association.^{2,5-7} We found reports of presenting in adulthood were even scarcer.⁶

These lesions are usually diagnosed prenatally or in the first years of life. Both can have a wide spectrum of presentations ranging from asymptomatic to neonatal death depending on the size of the mass and consequent physiological impairment.^{1,2} After the first year of life recurrent infections are the most common presentation for both pathologies.¹⁻⁴ It is important to note that potential for malignant transformation has been described in both entities, with stronger evidence in CCAM.³ Imaging has an important part in diagnosis of these lesions. Before birth ultrasound has a key role and after birth CT scan is the gold standard. Morphological features, location and blood supply can help distinguish the different malformations but this differentiation can be particularly difficult. Final diagnosis is established by histological analysis.¹⁻³ CCAM is found in most cases to be an isolated finding, although type 2 has been described with other anomalies.^{1,2} Whereas the existence of further congenital anomalies, such as lung, cardiac, diaphragm or chest wall anomalies, is more frequent in PS, particularly in cases of EL-PS, it only happens in 15% of IL-PS cases.^{1,5} The mainstay of treatment for CCAM and PS is surgical resection, lobectomy is the usual procedure of choice.¹⁻³ The authors present this case because it is so rare. Although uncommon and infrequently diagnosed in adults, congenital malformations should be included in the differential diagnosis of repeated infections, particularly if they are on the same lobe.

Conflicts of interest

The authors have no conflicts of interest to declare.

References

1. Feijó CA, Ferreira H, Fischer G. Congenital lung malformations. *J Bras Pneumol.* 2011;37(2):259–71.
2. Samuel M, Burge DM. Management of antenatally diagnosed pulmonary sequestration associated with congenital cystic adenomatoid malformation. *Thorax.* 1999;54:701–6.
3. Laberge JM, Puligandla P, Flageole H. Asymptomatic congenital lung malformations. *Semin Pediatr Surg.* 2005;14:16–33.
4. Sousa V, Carvalho L. Malformação adenomatóide quística congénita do pulmão ou malformação congénita das vias aéreas pulmonares. *Rev Port Pneumol.* 2003;IX(3):249–56.
5. Sánchez Abuín A, Somoza I, Liras J, Méndez R, Tellado M, Ríos J, et al. Malformación adenomatoidea quística congénita asociada a secuestro pulmonar. Presentación de dos casos clínicos. *Cir Pediatr.* 2005;18:39–41.
6. Chung T, Cheng L, Chang H, Lin M. Adult-onset congenital cystic adenomatoid malformation in combination with intralobar bronchopulmonary sequestration: a case report. *Chin J Radiol.* 2004;29:213–6.
7. Herman TE, Siegel MJ. Congenital intralobar pulmonary sequestration with cystic adenomatoid malformation. *J Perinatol.* 2009;29:175–7.

E. Silva*, J. Vale, A. Reis

Pulmonology Department, Centro-Hospitalar Tondela-Viseu, Portugal

* Corresponding author.

E-mail address: eloisacs@gmail.com (E. Silva).

<http://dx.doi.org/10.1016/j.rppnen.2015.05.003>

Yellow bronchoscopy: A severe case of tracheal and bronchial Jaundice



Dear Editor,

Jaundice, which can be caused by a very wide variety of conditions, results from the increased levels of bilirubin in the blood. Due to the affinity of bilirubin to elastin, jaundice is best detected by examining the skin and sclera, but can also be found in others elastin-rich tissues such as skin, sclera, intima of the vessel wall and ligaments.

We present the case of a 68-year-old nonsmoker male who was referred to the emergency department for evaluation of 1-week history of jaundice, light-colored stools, dark urine, anorexia and weight loss. Blood work showed an

elevated direct bilirubin 9.34 mg/dL (normal, 0–1 mg/dL) and he was diagnosed with a carcinoma of the pancreas head.

Bronchoscopy was performed during a pulmonary nodule investigation and revealed a nodule on the left side of the epiglottis and severe vocal cords and bronchial tree jaundice (Fig. 1).

Bronchoscopy is not a frequently performed exam in patients with such high levels of bilirubin in the blood. In the present case bronchoscopy was performed due to the nodule location, making it difficult to access through transthoracic lung biopsy and due to the need for pulmonary metastasis exclusion in order to get a correct staging.

The high amount of elastin present in the airways makes it possible to observe a fine yellow coloration characteristic of jaundice in the bronchial tree, as observed in these endoscopic images of rare beauty and iconographic interest.