



## RESEARCH LETTERS

### Transfusion related acute lung injury: An underdiagnosed and dangerous entity



Dear Editor,

Transfusion-related acute lung injury (TRALI) is one of the most serious blood transfusion complications. This pathological process produces a clinical syndrome characterized by dyspnea; hypoxemia; arterial hypotension; non-cardiogenic, acute pulmonary edema; and fever. TRALI usually occurs within the first six hours after a blood transfusion (classic TRALI)<sup>1</sup> or from six to 72 h after the transfusion (delayed TRALI).<sup>2</sup>

We report the case of a 70-year-old female without a prior history of cardiovascular or pulmonary disease who was subjected to a programmed total right knee arthroplasty and required multiple transfusions of packed red blood cells during her hospital stay. Four hours after completion of the third unit of red blood cells, she started to develop dyspnea, fever, arterial hypotension, increased heart rate and a calculated PaO<sub>2</sub>/FiO<sub>2</sub> ratio of 220 mmHg. Pulmonary auscultation detected bilateral crackles. Chest radiography showed bilateral alveolar infiltrates (chest radiography prior to admission showed no acute pathology; Fig. 1A and B). Computed tomography angiography ruled out pulmonary embolism and showed bilateral alveolar infiltrates (Fig. 1C). Transthoracic echocardiography excluded left chamber overload (left ventricle ejection fraction of 69%). Oxygen therapy was initiated, which had a favorable evolution and complete resolution of bilateral pulmonary infiltrates within 48 h from the onset of symptoms, without requiring mechanical ventilation (Fig. 1D). Having excluded other possible causes of ARDS, the diagnosis of acute lung injury secondary to transfusion or TRALI syndrome was made.

TRALI is a little-known complication resulting from the transfusion of blood products, especially red blood cell concentrates, fresh frozen plasma, apheresis, and platelet concentrates. TRALI is the third leading cause of death associated with transfusion; however, underdiagnosis is very common, and therefore, very few documented cases exist.<sup>1</sup>

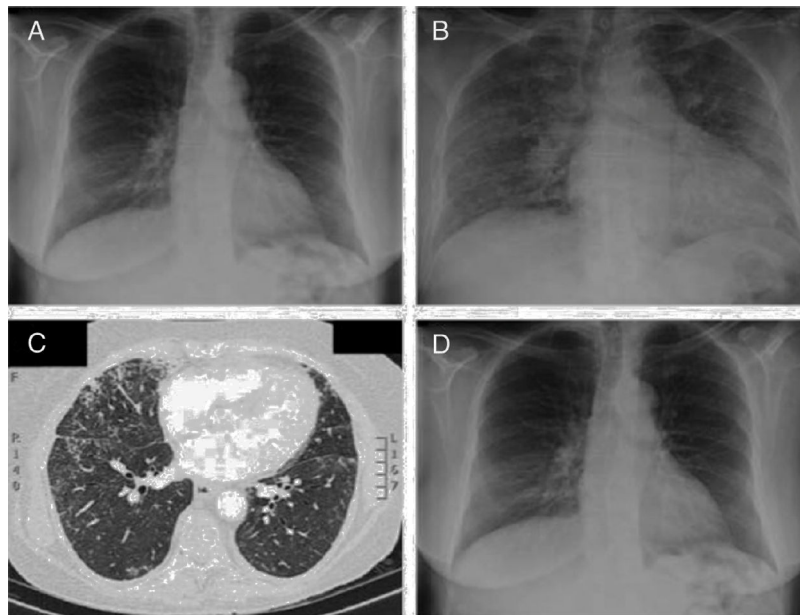
TRALI is characterized by sudden onset of dyspnea, cyanosis, and fever. Arterial hypotension has also been reported in most patients. A physical examination shows diffuse pulmonary crackles and decreased breath sounds. Chest radiography shows faint, diffuse alveolar infiltrates consistent with pulmonary edema.<sup>3</sup> The mortality rate of this syndrome ranges from 5 to 25%, and most patients

recover during the first 72 h.<sup>3</sup> Critically ill patients have a higher risk of developing TRALI after receiving a blood transfusion.<sup>4,5</sup> The high incidence of TRALI among critically ill patients may be explained by the “two-hit hypothesis”. The “first hit” is an underlying clinical condition that alerts and prepares the lung neutrophil. The “second hit” is transfusion of cellular blood products, which causes the activation of neutrophils in the lung compartment, resulting in TRALI. Hematologic malignancies, cardiovascular diseases, sepsis, fluid overload, cardiac emergency surgery, massive transfusion, mechanical ventilation, a high score on the Acute Physiology and Chronic Health Evaluation (APACHE)-II scale, advanced age, shock, alcohol dependence, kidney failure, and severe liver disease have been identified as risk factors for the “first hit”.<sup>4,6</sup>

The lack of recognition of this entity may result in improper treatment and the failure to report diagnosed cases to blood transfusion services and blood banks.<sup>1</sup> Unfortunately, the signs and symptoms associated with TRALI may be easily confused with other conditions, including transfusion-associated circulatory overload (TACO), pneumonia, and acute respiratory distress syndrome (ARDS). The first key point in the diagnosis of TRALI is to differentiate it from other forms of ARDS, this means that it is mandatory to exclude other possible causes of ARDS before making the diagnosis; the second key point for differentiating TRALI from other types of pulmonary edema is that pulmonary edema in TRALI is not cardiogenic, and patients have no volume overload. Its treatment involves maintaining hemodynamic status and applying ventilatory support.<sup>1</sup> No indication exists for using corticosteroids or diuretics; extracorporeal membrane oxygenation was successfully used in a severe case.<sup>3</sup> The differential diagnosis of TRALI is important because aggressive diuretic therapy may aggravate hypotension and cause shock and death.

No specific treatment is available, despite the progress made in researching TRALI. The reduction in the number of cases of this entity is predominantly due to the preventive measures implemented. The potential functions of washing transfusion products, implementation of strategies in fresh blood products, and pre-storage filtration are currently being researched as possible measures to prevent TRALI.<sup>7</sup>

In conclusion, TRALI is a serious complication of transfusion and other forms of ARDS need to be excluded before making the diagnosis. It is extremely important to closely monitor patient status for at least 72 h after receiving a blood transfusion, suspect TRALI if the patient reports respiratory symptoms, and perform an echocardiogram to



**Figure 1** (A) Chest radiography prior to admission shows no acute pulmonary disease. (B) Chest radiography performed hours after the third transfusion shows bilateral pulmonary alveolar infiltrates. (C) Computed tomography angiography of the pulmonary arteries confirms the existence of bilateral and diffuse alveolar infiltrates. (D) Chest radiography 72 h after the onset of clinical symptoms shows a complete disappearance of bilateral pulmonary infiltrates.

distinguish between different types of adverse reactions related to the transfusion.

### Conflict of interests

The authors have no conflicts of interest to declare.

### References

1. Kopko PM, Paglieroni TG, Popovsky MA, Muto KN, MacKenzie MR, Holland PV. TRALI: correlation of antigen-antibody and monocyte activation in donor-recipient pairs. *Transfusion*. 2003;43:177–84.
2. Marik PE, Corwin HL. Acute lung injury following blood transfusion: expanding the definition. *Crit Care Med*. 2008;36:3080–4.
3. Silliman CC, Ambruso DR, Boshkov LK. Transfusion-related acute lung injury. *Blood*. 2005;105:2266–73.
4. Gajic O, Rana R, Winters JL, Yilmaz M, Mendez JL, Rickman OB, et al. Transfusion-related acute lung injury in the critically ill: prospective nested case-control study. *Am J Respir Crit Care Med*. 2007;176:886–91.
5. Vlaar AP, Juffermans NP. Transfusion-related acute lung injury: a clinical review. *Lancet*. 2013;382:984–94.
6. Rana R, Fernandez-Perez ER, Khan SA, Rana S, Winters JL, Lesnick TG, et al. Transfusion-related acute lung injury and pulmonary

edema in critically ill patients: a retrospective study. *Transfusion*. 2006;46:1478–83.

7. Peters AL, van Hezel ME, Juffermans NP, Vlaar AP. Pathogenesis of non-antibody mediated transfusion-related acute lung injury from bench to bedside. *Blood Rev*. 2015;29:51–61.

M.A. Ariza-Prota<sup>a,\*</sup>, A. Pando-Sandoval<sup>b</sup>, T. Budiño<sup>a</sup>

<sup>a</sup> *Área del Pulmón, Hospital Universitario Central de Asturias (HUCA), Instituto Nacional de Silicosis (INS), Facultad de Medicina, Universidad de Oviedo, Spain*  
<sup>b</sup> *Servicio de Neumología, Hospital Valle del Nalón, Asturias, Spain*

\*Corresponding author.

E-mail address: [arizamiguel@hotmail.com](mailto:arizamiguel@hotmail.com)

(M.A. Ariza-Prota).

<http://dx.doi.org/10.1016/j.rppnen.2016.12.003>  
 2173-5115/

© 2017 Sociedade Portuguesa de Pneumologia. Published by Elsevier España, S.L.U. This is an open access article under the CC BY-NC-ND license (<http://creativecommons.org/licenses/by-nc-nd/4.0/>).